



대한근골격영상의학회 20년


20 Years History of Korean Society of Musculoskeletal Radiology

1990-2010

대한근골격영상의학회 20년

20 Years History of Korean Society of Musculoskeletal Radiology

1990-2010



창립 20주년 기념집을 발간하며

대한근골격영상의학회 창립 20주년을 맞아



존경하는 회원 여러분!

20년 전 근골격영상을 전공하는 몇몇 선생님들이 혜화동 한 찻집에 모였습니다. 근골격영상을 위한 모임을 갖자고 결정하였고 그 후 격월로 모여 준비해온 증례를 뷰박스에 걸어 놓고 열띤 토론을 하였습니다. 그로부터 20년이 지나는 동안 그 모임은 정식 학회의 이름을 갖게 됐고 매월 월례집담회와 춘계학술대회, 이미징 컨퍼런스, 연수 강좌, 송년 심포지움 등 다양한 학술활동을 통해 많은 회원이 참가하는 모임이 되었습니다. 시작은 작았지만 20년이 지난 지금의 발전은 많은 회원 여러분들께서 그 동안 각자 맡은 역할을 훌륭히 해 주셨기에 가능한 일이었습니다. 잘 아시는 바와 같이 우리 학회는 회원 여러분 한분 한분이 모여 이뤄졌으며 존재의 의미가 있는 모임입니다.

우리는 이제 새로운 20년을 시작하고 있습니다. 지난 20년간의 많은 경험과 노력을 바탕으로 더 나은 학회를 만드는 것이 20주년에 회원으로 있는 우리 모두의 역할이라고 생각해 봅니다.

존경하는 회원 여러분!

우리 주위에는 많은 학회가 있습니다. 학회 활동은 회원으로서 누릴 수 있는 권리이지만 한편으로는 회원으로서의 의무도 존재합니다. 여러 회원님들의 노력의 결실을 같이 나누는 것을 권리라 한다면 결실을 맺을 수 있도록 참여하는 것은 의무라 할 수 있을 것입니다. 지난 20년간 학회의 활발한 활동과 발전은 회원 여러분 모두의 참여가 있었기에 가능한 일이었습니다

앞으로도 우리 학회는 많은 활동을 계획하고 있습니다. 이러한 일은 회원 여러분의 적극적인 참여가 있어야 가능합니다. 앞으로도 지속적인 참여를 부탁드립니다. 마지막으로 회원 여러분의 건승을 기원합니다. 회원 여러분! 감사합니다.

2010년 12월

대한근골격영상의학회 회장 류경남

발간사 / 류경남 회장

1부. 대한근골격영상의학회 발자취

- 1 연혁
- 2 역사 _태동기
_발전기
_도약기
_성숙기

2부. 조직

- 1 조직도
- 2 임원단
- 3 역대회장
- 4 회원 _현황
_명단

3부. 학술활동

1 국내

- 1 연례활동
- 2 학술대회

차례

- 3 연수교육
- 4 Subspecial conference
- 5 송년 Symposium
- 6 우수논문
- 7 AMS 2004

2 국외

- 1 논문
- 2 학회
- 3 전시 발표

4부. 사진으로 보는 학회 20년

5부. 학회 현황

- 1 회칙
- 2 지회 운영
- 3 홈페이지 및 퀴즈 운영

1 부

대한근골격영상의학회 발자취

1 연혁

2 역사

- 태동기
- 발전기
- 도약기
- 성숙기

1 | 연혁

1990.11.14	근골격계방사선과학연구회 창립
1991.01.10	월례집담회 시작
1991.06.15	학술대회(심포지움) 시작-경북대학병원
1993.04.14	Imaging Conference 시작
1993.12	최초 근골격계방사선과학연구회 회칙 제정
1995.01	증례집 1호 발간
1995.08.05	충청-호남지회 창립
2000	영남지회 창립
2000.01	대한근골격영상의학회 로고 제작
2000.04.07	대한 근골격계방사선과학연구회 홈페이지 개설
2004.09.04	Asian Musculoskeletal Society 6th Annual Meeting 개최(서울)
2005	1차 회칙 개정
2005.06.01	대한근골격영상의학회로 명칭 변경 및 운영위원회 확장
2005.11.06	대한근골격영상의학회 주관 연수교육 시작
2006	대한근골격영상의학회 홈페이지 개편
2006.12	Weekly Cases 시작
2009.12.12	송년 심포지움 시작
2010.04.16	창립 20주년 춘계학술대회 개최 - 제주도
2010.05	2차 회칙 개정

2 | 역사

● 발전기

새벽 공기는 가을답지 않게 싸늘했다.

이순신 장군의 직함을 따서 지어진 거제도 옥포 에드미럴 호텔 찬 공기를 마시며 카메라를 들고 서성거리는 한 사람이 있었으니 그가 바로 대한영상의학회 근골격연구회 총무 양 익 교수였다.

전날 우리는 춘계학술대회를 여기서 치렀다. 오늘 오전 중 겨울연가를 촬영했다는 외도를 자연답사하고 귀가하기에 앞서 거제도 포로수용소를 잠깐 들렀다. 그 해 겨울 미국 북미방사선학회에 참석하고 귀국하는 비행기에서 큼직하게 인자한 눈을 가진 지 원희 교수와 동석하여 멀고도 먼 태평양을 함께 건넜다. 이 두 교수님은 내가 대한근골격영상의학회 회장을 할 때 총무를 맡아주셨던 고마운 분들이다.

정치나 경제는 끊임없이 남녀노소의 분별이 있고, 크고 작음이 있고, 많고 적음이 있어 항상 부자연스런 법이 형성되고 그에 상응하는 죄악이 생기기 마련이다. 하지만 학문은 그렇지 않다. 학문은 남녀노소가 없고 크고 작음이 없고 많고 적음 조차 없는 것인데, 학벌이나 권위가 개입 되어 마치 그 모양이 부풀고 위축되어 회칙을 만들고 새로운 법을 재정하는 어처구니 없는 일이 일어나고 그에 상응하는 죄가 발생하여 인간은 자유로부터 멀어지고 창의력은 소실되어 국가의 백년대계가 위기에 놓여 지기도 한다.

고려 말 조선 초 정도전 선생은 [조선경국전]에서 '백성이 가장 귀하고 사직은 다음이고 군주는 가장 가벼운 존재'라고 설파하고 있다. 당시 남송의 주희는 '인간의 성품이 바로 진리' 라는 '성즉리' 이는 바로 도덕적 성품이 창의적 발상을 할 수 있다는 것이다. 도덕적 성품이란 무엇인가? 그것은 죄의식이 없는 자유로운 심성을 말하고 있다. 즉 법이란 인위적이고 법이 말미암아 인간을 죄인으로 만들고 인간을 자유롭지 못하게 구속한다는 것이다.

옛날 춘추전국시절 제나라 제왕은 죽은 말뼈다귀 몇 구를 갖고 와 천리마라고 우기는 한 상인에게 큰 상을 내린 적이 있다. 그런 연후 제나라는 당대 최고 부유한 나라가 되었다. 군주가 백성을 믿을 때 백성은 자유로워지고 창의력 있는 역사를 이룩한다는 것이다.

회장이 할 수 있는 일은 없다. 총무가 할 수 있는 일은 많다. 총무가 연수 강좌를 개최하자고 할 때 나는 지원희 교수의 조상이신 대한민국 초대 면역학의 창시자 지석영 선생을 생각했다. 총무가 근골격연구회를 근골격영상 의학회로 명칭 변경을 요청했을 때 회원들이 좋다는 명칭으로 대한영상 의학회에 등록했다. 학회 등록하고 해외 연자를 초청하고 춘계학술대회를 개최하고 추계학술대회 강연 프로그램을 짜고 연사를 선정하고, 하고 많은 일들이 총무의 손에서 순조롭게 이루어져 우리 학회는 흑자를 누렸다.

회장직을 마치고 5년이란 세월이 흘렀다. 어느 날 학회에서 만난 지원희 교수는 이렇게 말했다. '문 선생 덕분에 내가 하고 싶은 일 다 해 본 것 같아요

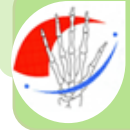/문태용

2부

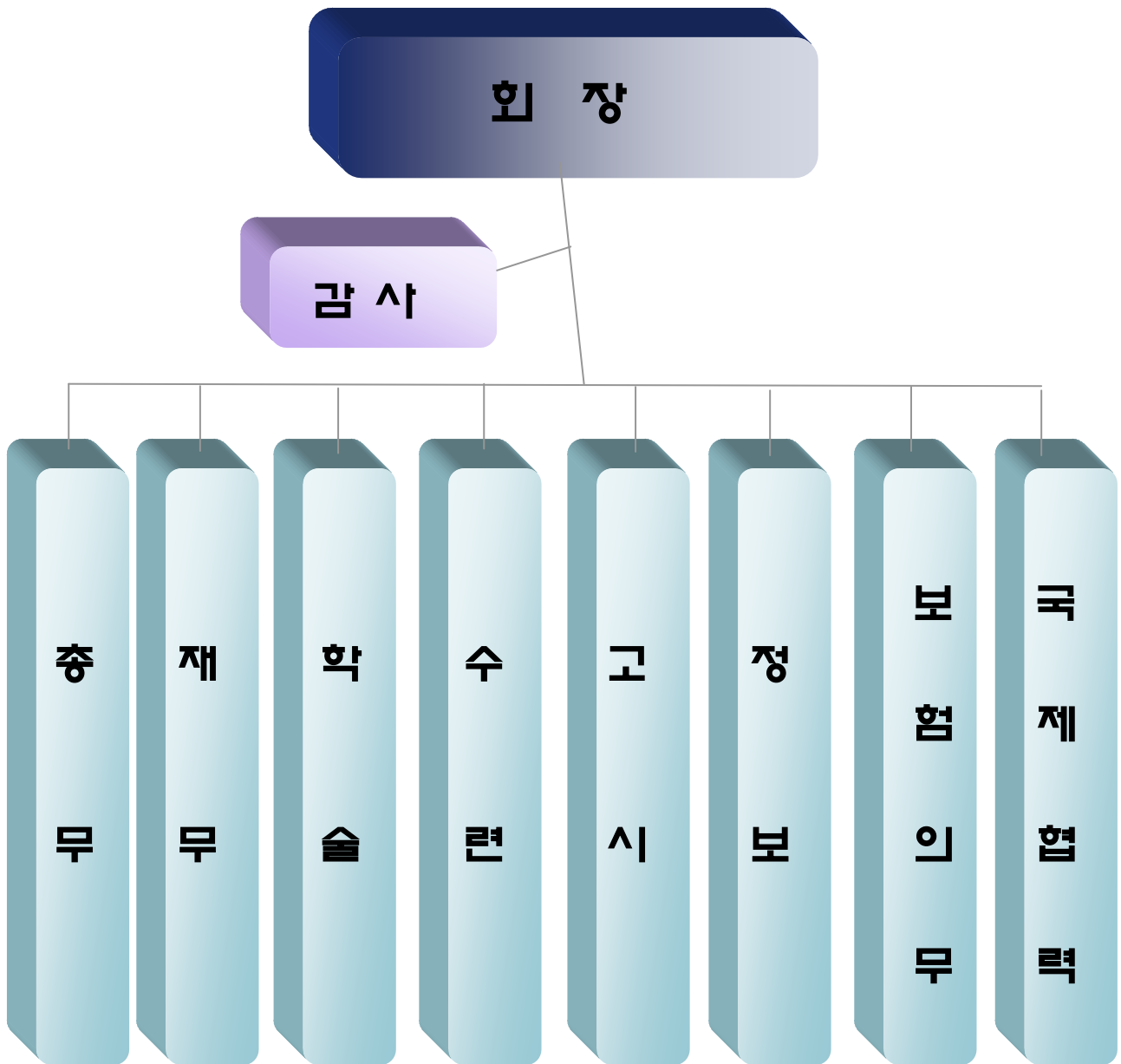
조직

- 1 조직도
- 2 임원단
- 3 역대회장
- 4 회원명단

1 | 조직도



대한근골격영상의학회



2 | 역대 임원단

1) 연구회 시기

근골격계 방사선연구회가 창립된 지난 1990년 11월. 회장, 총무, 학술위원을 시작으로 2006년 대한근골격영상의학회로의 승격과 동시에 학회 형식의 이사진이 구성되었다. 4년에 걸친 초대 회장단 시기엔 총무 3분이 교체됐고, 마지막 3번째 총무부터는 업무의 연계성을 위해 회장 임기와 엇갈려 임명토록 했다.

2) 학회 시기

2006년 학회 승격 이후 회장 산하에 이사진을 구축해 총무이사, 재무이사, 학술이사, 고시 이사, 수련 이사, 정보이사, 보험의무이사, 국제협력이사를 도입했으며 2005년에는 간행이사를 추가로 두었다. 2008년부터는 학술이사, 고시이사, 수련이사, 정보이사 산하 간사 제도를 도입했다. 또한 2010년에는 감사 제도를 도입하였다.

3) 연구회 시기의 역대 임원단


임기	대	회장	총무	학술위원	정보위원
1990.11 ~ 1995	1 대	강홍식 (서울대)	신명진 (울산대) (1990 ~ 1993)	류경남 (경희대)	
			송인섭 (중앙대) (1993 ~ 1994)		
			성미숙 (가톨릭대) (1994 ~ 1996)		
1996 ~1997	2 대	서진석 (연세대)	성미숙 (가톨릭대) (1994 ~ 1996)	김성문 (울산대)	
			조재현 (아주대) (1997 ~ 1998)		
1998 ~1999	3 대	조길호 (영남대)	조재현 (아주대) (1997 ~ 1998)	김성문 (울산대)	
			천경아 (가톨릭대) (1999 ~ 2000)		
2000 ~2001	4 대	박양희 (국립경찰 병원)	천경아 (가톨릭대) (1999 ~ 2000)	김백현 (고려대)	이영준 (인제대)
			김백현 (고려대) (2001 ~ 2002)	이정훈 (원자력병원)	
2002 ~2003	5 대	박진균 (전남대)	김백현 (고려대) (2001 ~ 2002)	이상훈 (울산대)	이영준 (인제대)
			양 익 (한림대) (2003 ~ 2004)		
2004 ~2005	6 대	문태용 (부산대)	양 익 (한림대) (2003 ~ 2004)	이상훈 (울산대)	이영준 (인제대)
			지원희 (가톨릭대) (2005 ~ 2006)		

4) 학회 시기의 역대 임원단

임기	2006 ~ 2007 년		2008 ~ 2009 년		2010 년~
대	7 대		8 대		9 대
회장	서경진 (단국대)		신명진 (울산대)		류경남 (경희대)
총무	지원희 (가톨릭대)	하두회 (차의과학 대)	하두회 (차의과학 대)	최윤선 (을지대)	최윤선 (을지대)
재무	하두회 (차의과학 대)	최윤선 (을지대)	최윤선 (을지대)	이민희 (성균관대)	이민희 (성균관대)
학술	조재현 (아주대) 간행 이경규 (한림대)		성미숙 (가톨릭대) 간사 김성준 (연세대), 최자영 (서울대)		황지영 (이화여대) 간사 이인숙 (부산대)
수련	권순태 (충남대)		박정미 (가톨릭대) 간사 명재성 (고려대)		박정미 (가톨릭대) 간사 류정아 (한양대)
고시			이상용 (전북대) 간사 이영환 (대구가톨릭 대)		이상용 (전북대)
정보	전동진 (을지대)		정혜원 (울산대)		운영철 (성균관대) 간사 박지선 (경희대)
보험 의무	고영환 (보라매병원)		양익 (한림대)		양익 (한림대)
국제 협력	홍성환 (서울대)		최정아 (서울대)		김성준 (연세대)
감사					하두회 (차의과학대)


3 | 역대 회장

1대 1990~1995




강홍식

2대 1996~1997




서진석

3대 1998~1999




조길호

4대 2000~2001




박양희

5대 2002~2003




박진균

6대 2004~2005




문태용

7대 2006~2007



서경진

8대 2008~2009









신명진

9대 2010~



류경남

4 | 회원명단



3 부

학 술 활 동

제 1장. 국내 활동

- 연례활동
- 학술대회
- 연수교육
- Subspecial conference
- 송년 심포지움
- 우수논문
- AMS 2004

1 | 연례활동

1) 집담회

Short Lecture				특이사항
시기	장소	제목	강사	내용
1993				
1994				
1995				
1996				
1997	02.11	서울대		
1998	04.07	서울대		
1999	02.09	서울대	no	
	03.09	서울대	no	
	04.20	충남대		Dr. Timan 춘계심포지움
	04.21	삼성서울병원		Dr. Timan Imaging conference
	05.11	서울대	no	
	06.08	서울대	no	
	07.06	서울대	no	
	09.18	가톨릭대 성빈센트	Sports related injury	추계 심포지움
	10.12	서울대	no	
	12.14	서울대	no	송년회, 가든부
2000	01.11	서울대	no	
	02.08	서울대	no	
	03.14	서울대	no	
	04.19	삼성서울병원	no	Imaging conference 춘계심포지움

	05.09	서울대	no		
	06.13	서울대	no		
	07.11	서울대	no		
	10.10	서울대	no		
	10.26				대영회
	11.14	서울대	no		
	12.08	서울대 임상의학연구	운파기념 특별강연회		송년회 (사랑방손님과어머니)
2001	01.09	서울대	no		
	02.21	삼성서울병원			Imaging conference
	03.13	서울대	no		
	04.10	서울대	no		
	05.26	울산대	근골격계 초음파의 진보		춘계심포지움
	06.12	서울대	no		
	07.10	서울대	no		
	09.11	서울대	no		
	10.09	서울대	no		
	10.25	호텔 롯데월드			대영회
	11.13	서울대	no		
	12.11	서울대	no		송년회, 가든뷰
2002	01.08	서울대			
	02.10	삼성서울병원			Imaging conference
	03.12	서울대			
	04.13	애드미랄호텔 (거제)	근골격계 방사선과학의 최신지견		춘계 심포지움
	05.14	서울대	시작(?)	이경규 선생님 (서울대전임의)	
	06.11	서울대	no		
	07.09	서울대	no		

	09.10	서울대	no		
	10.08	서울대	no	허용민 선생님 (연세대전임의)	
	10.16	호텔 롯데월드			대영회
	11.12	서울대	Musculoskeletal ultrasound	Antonio H.Bouffard (Henry Ford hospital)	
	12.10	서울대		김동은 선생님 (아산병원 전임 의)	송년회 (사랑방손님과어머니)
2003	01.14	서울대	no		
	02.12	삼성서울병원			Imaging conference
	03.11	서울대	Combined Scintigraphic and Radiographic Diagnosis of Bone and Joint Disease	박용휘 교수님 (성애병원)	
	04.12	수안보 파크호텔	Spine Imaging		준계 심포지움
	05.07	서울대	no		
	06.10	서울대	Mesenchymal chondrosarcoma	박용구 교수님 (경희대 병리과)	
	07.15	서울대	no		
	09.16	분당 서울대	no		
	10.07	서울대	no		
	11.11	서울대	segmental instability of spine on plain radiography	황지영 선생님 (삼성병원 전임의)	

	12.09	서울대	no		송년회(산적)
2004	01.13	서울대	Posterolateral instability of the knee	최자영 선생님 (서울대 전임의)	
	02.10	서울대	Hypercellular bone marrow	최정은 선생님 (여인도성모 전임의)	
	03.09	서울대	DXA 골밀도 결과의 판독법	양승오 교수님 (울산대)	
	04.10	김해 관광호텔	류마티스 근골격 방사선의학		춘계심포지움
	05.11	서울대	Cellular and molecular imaging	서진석 교수님 (신촌 세브란스)	
	06.09	삼성서울병원			Imaging conference
	07.13	서울대	no		
	09.02				AMS
	09.14	서울대	no		
	10.20				대영회
	11.09	서울대	no		
	12.14	서울대	no		송년회
2005	01.11	서울대	Bone scintigraphy in musculoskeletal radiology	양승오 교수님 (울지인대)	
	02.15	서울대	연조직종양의 자기공명조영증강 양상	문태용 교수님 (부산대)	
	03.08	서울대	Rapidly destructive hip disease의 이해	류경남 교수님 (경희대)	
	04.16	부산대	Musculoskeletal Trauma imaging		춘계학술대회

	05.10	삼성서울병원			Imaging conference
	06.08	서울대	Imaging of craniovertebral junction	홍석주 교수님 (고려대)	
	07.12	서울대	Quick References: Orthopedic Hardware	이지영 교수님 (단국대)	
	09.13	서울대	Complications after total knee replacement	천경아 교수님 (가톨릭대)	
	10.19				대영회
	11.06	서울대	Musculoskeletal plain radiography		연수강좌
	11.08	서울대	no		
	12.13	서울대	Musculoskeleta I PET/CT	양승오 교수님 (울지인대)	송년회
2006	01.18	서울대	Cartilage imaging	David G Disler	
			MR and US of arthritis	Theodore T Miller	
	02.14	서울대	슬관절 스포츠 손상의 수술적 치료	장중범 교수님 (분당서울대 정형외과)	
	03.07	서울대	Fractures of the Calcaneus	황지영 교수님 (이화여대)	
	03.21	을지대학병원	정도관리와 기타 최신지견		춘계학술대회
	05.09	서울대	Imaging Anatomy of the Knee Joint	류경남 교수님 (경희대)	
	06.04	서울아산병원	Essentials of		연수강좌

			Musculoskeletal Imaging		
	07.11	서울대	Radiologic Signs in Skeletal Dysplasias and Congenital Malformations	김옥환 교수님 (아주대)	
	09.06	삼성서울병원			Imaging conference
	10.30	그랜드힐튼			대영회
	11.14	서울대	Shoulder arthroscopy	오주환 교수님 (서울대 정형외과)	
			강의법	류경남 교수님 (경희대)	
	12.08	Partners Lounge	K-space	서경진 교수님 (단국대)	송년회
2007	01.16	서울대	Imaging of ankle sprain	김성준 교수님 (한양대)	
	02.13	서울대	no(?)		
	03.20	강남성모	Update of rheumatoid arthritis and ankylosing spondylitis : Diaganosis and Management	박성환 교수님 (강남성모병원 류마치스 내과)	
	04.20	전북대학병원			준계학술대회
	05.15	강남성모	Brachial plexus	서경진 교수님 (단국대)	
	06.17	세브란스 은명대강당			연수강좌

	07.10	서울대	no(?)		
	09.05	삼성서울병원			Imaging conference
	10.22	그랜드힐튼			대영회
	11.13	서울대	no(?)		
	12.11	갈리오페			송년회
2008	01.08	서울대	no		
	02.12	서울대	no(?)		
	03.11	서울대	no(?)		
	04.25	강릉아산병원	Musculoskeletal application of Molecular Imaging and 3T MRI		춘계학술대회
	05.13	서울아산병원	no(?)		연수강좌
	06.22	고려대학교 인촌기념관			
	07.08	서울아산병원	no(?)		
	08.26	서울아산병원	no(?)		
	09.10	삼성서울병원			Imaging conference
	10.24	코엑스			AOCR+KCR
	11.11	서울아산병원	no(?)		
	12.09	서울아산병원	no(?)		송년회 (아산병원 Sky lounge)
2009	01.13	서울아산병원	no(?)		
	02.24	서울대 어린이병원	Radiology- Pathology Joint Conference		
	03.10	서울아산병원	no(?)		
	04.10	경주 교육문화회관			춘계학술대회
	04.26	고려대학교 인촌기념관	Imaging of the lower extremity		연수강좌

	05.12	서울아산병원	no(?)		
	06.09	서울아산병원	no(?)		
	07.07	서울아산병원	no(?)		
	08.25	서울아산병원	no(?)		
	09.09	삼성서울병원			Imaging conference
	10.21	코엑스			대영회
	11.10	서울아산병원	no(?)		
	12.12	서울성모병원	Resident training, Imaging tools		송년심포지움
2010	01.12	서울성모병원	Isotropic imaging in joints	윤영철 교수님 (성균관인대)	
	02.18	경희의료원	Radiology- Pathology Joint Conference		
	03.16	서울성모병원	Disc nomenclature	곽규성 교수님 (아주인대)	
	04.16	제주 라마다플라자			춘계학술대회
	05.16	삼성서울병원	근골격계 단순촬영의 이해		연수강좌
	06.08	서울성모병원	Molecular imaging for cancer detection	송호택 교수님 (연세의대)	
	07.06	서울성모병원	US-guided perineural injection	홍석주 교수님 (고려의대)	
	08.24	서울성모병원	Pediatric ribs	박상옥 선생님 (서울아산병원)	
	09.08	삼성서울병원			Imaging conference
	10.20	그랜드힐튼			대영회

11.09	서울성모병원	Diffusion-weighted MR imaging	이소연선생님 (가톨릭의대 전임의)	
12.11	서울대병원 c 강당	Imaging of knee joint, pelvis		송년심포지움

2) Imaging Conference

	Moderator	진행방식	Special Lecture	제목
99. 04.21		골영회 회원 증례토론	Dr. Timan	
2000. 04.19	송인섭(중앙대)	전공의 증례토론 (춘계심포지움)		
2001. 02.21		골영회 회원 증례토론	Dr. Rssnick	MR imaging of meniscal problems
2002. 02.20	박정미(가톨릭대)	전공의 증례토론	Dr. Rssnic	MRI of arthritis
2003. 02.12	권순태(충남대) 조재현(아주대)	골영회 회원 Panel	서경진 (서주진단방사선과)	Radiologic signs
2004. 05.09	양익(한림대)	전공의 10명 증례토론	서경진 (서주진단방사선과)	Signs
2005. 06.08	김성문(서울아산)	Presentation tool (clickman)	서경진 (단국대의대)	Image Sniper: One Shot, One Kill
2006. 09.06	홍성환(서울대)	Musculoskeletal Radiology Ti	서경진(단국대)	Funny Wrist Anatomy
2007. 09.05				
2008. 09.10	양익(한림대)	전공의 증례토론	신명진(울산대)	One shot, One kill
2009. 09.09	류경남(경희대)	Clickman 사용		
2010. 09.08	지원희(서울성모)	Clickman 사용		

2 | 학술대회

1) 2007 춘계학술대회

목 차

좌장: 강홍식 (서울의대)

1:00 - 2:00 등록	
1:50 - 2:30 근육영상의학의 최장님 인사	
2:00 - 2:30 Internal Disc Disruption	이준우 (서울의대) 1
2:30 - 3:00 Knee-Posterolateral Corner Injury	최재형 (서울의대) 21
3:00 - 3:30 Femoroacetabular Impingement Syndrome	서민욱 (부산의대) 31
3:30 - 3:40 coffee break	

좌장: 박진균 (전남의대)

3:40 - 4:10 기타 특강 (1) - 과 영 실	
4:10 - 4:40 Rotator Interval and Cable	윤영철 (영남대의대) 41
4:40 - 5:10 Muscle Imaging	이정민 (보경공중의대) 49
5:10 - 5:40 Acetabular and Pelvic Bone Fracture	김성호 (한양대의대) 55
5:40 - 6:10 기타 특강 (2) - 병 상 권	
6:10 - 6:20 우수-패피 논문 시상식	최정아 (서울의대)
6:20 - 6:40 총회	

2007. 4.20
전북대학교 병원
GSK홀(전주)

2) 2008 춘계학술대회

목 차

1:00 ~ 2:00 등록

2:00 ~ 2:10 근육영상의학의 최장님 인사 / 산영선, 윤선대

제 1부
Molecular imaging

좌장: 류경남, 박영미

2:10 ~ 2:40 Molecular imaging - introduction / 서진석, 연세대	19
2:40 ~ 3:10 Cancer detection: Quantitative comparison of three superparamagnetic stem cell labeling agents by 3T MRI and bioluminescence imaging / 송호익, 연세대	31
3:10 ~ 3:40 Matrix metalloproteinase imaging in arthritis / 이상훈, 울산대	45
3:40 ~ 4:10 Fracture healing using mesenchymal stem cell / 이진우, 울산대	55
4:10 ~ 4:40 Coffee break	


제 2부
Musculoskeletal application of 3T MRI

좌장: 강홍식, 최수철

4:40 ~ 5:00 Practical issue in 3T imaging / 문승규, 한국대	65
5:00 ~ 5:20 Small joint imaging at 3T / 명재일, 고려대	73
5:20 ~ 5:40 Large joint imaging at 3T / 진 옥, 경희대	83
5:40 ~ 6:00 Spine imaging at 3T / 좌규일, 아주대	89
6:00 ~ 6:20 시상 및 총회	

2008. 4.25~26
강릉아산병원
대강당

3) 2009 춘계학술대회



목 차

전시 초록1 MR imaging in the Shoulder and Elbow of Professional Baseball Players / 전동진, 최윤신 양승오 7

전시 초록2 Imaging Findings of Accessory Ossicles Around Small Joints / 최윤신, 양혜진, 임미혜, 이시훈, 전동진, 한창원, 양승오 8

2009년 4월 10일 (금)

13:00 ~ 14:00 등록
14:00 ~ 14:10 대한근골격영상의학회 회장님 인사 (홍산의대 신명진)

제 1부 : Musculoskeletal Ultrasonography Revisited

좌장: 박진규 (연세대학교), 설미숙 (가톨릭대학교)

14:10 ~ 14:40 MRI versus US in musculoskeletal radiology / 이영환, 대구가톨릭의대 11

14:40 ~ 15:10 Optimization of US images-what the musculoskeletal radiologists should know / 위두희, 포항공중의대 17

15:10 ~ 15:40 Maneuver for dynamic musculoskeletal US / 조길호, 영남의대 23

15:40 ~ 16:10 coffee break

제 2부 : Pros and Cons of MRI Techniques in Musculoskeletal Imaging

좌장: 서진석 (연세대학교), 양승오 (포항공중대학교)

16:10 ~ 16:40 MRI versus MR arthrography for joint evaluation / 차광규, 순천향의대 27

16:40 ~ 17:10 Optimization of MRI sequence for joint imaging in 3T / 강창호, 고려의대 33

17:10 ~ 17:40 Advanced MRI techniques for musculoskeletal tumor imaging / 강병성, 울산의대 41

17:40 ~ 18:00 학술포럼
18:00 ~ 18:20 시상 및 총회

2009년 4월 11일 (토)

제 3부 : Radiologists' role in Pain Intervention: How to build a pain clinic as a radiologist

좌장: 문태용 (부산대학교), 최수정 (연세대학교)

09:00 ~ 09:30 Historical review & radiologists' role for pain intervention / 신명진, 울산의대 55

09:30 ~ 10:00 Technical details for pain intervention / 권종원, 상경련의대 61


10:00 ~ 10:30 coffee break

10:30 ~ 11:00 How to build a pain intervention practice in the academic environment / 이은주, 서울의대 67

11:00 ~ 11:30 How to build a pain intervention practice in the community environment / 김성현, 후천영상의학센터 81

2009.4.10~11 경주 교육문화회관

4) 2010 춘계학술대회



2010년 4월 16일 (금)

13:00 ~ 14:00 등록
14:00 ~ 14:10 대한근골격영상의학회 회장님 인사 / 경희의대 류경남

제 1 부 : 20 Years History of Korean Society of Musculoskeletal Radiology

좌장: 류경남 (경희대학교)

14:10 ~ 14:30 대한근골격영상의학회의 창립과 발전 / 서울의대 강홍식
14:30 ~ 14:50 대한근골격영상의학회의 과제와 미래 / 울산의대 신명진
14:50 ~ 15:00 모의 / 서울의대 강홍식, 연세의대 서진석, 영남의대 조길호, 전남의대 박진규, 부산의대 문태용, 광주동국대의대 서경진, 울산의대 신명진
15:00 ~ 15:20 coffee break

제 2 부 : Musculoskeletal Imaging Modality and Techniques

좌장: 양승오 (포항공중대학교), 박정미 (가톨릭대학교)

15:20 ~ 15:45 MR: Cartilage imaging and quantification / 울산의대 이상훈 29

15:45 ~ 16:10 CT: Current clinical applications and recent advances / 고려의대 이근영 39

16:10 ~ 16:35 US: Evolution of musculoskeletal US imaging / 계명대의대 이상훈 45

16:35 ~ 17:00 Radiation exposure in musculoskeletal radiology / 순천향의대 김현주 57

17:00 ~ 17:30 Research designs and process in musculoskeletal radiology / 전석의대 이상훈 63

17:30 ~ 17:50 학술포럼
17:50 ~ 18:20 시상 및 총회
19:00 ~ 저녁식사

(토) 4월 17일 (토)

제 3 부 : Optimization of MRI Sequences and Protocol

좌장: 문태용 (부산대학교), 최수정 (연세대학교)

09:00 ~ 09:30 MR: Optimization of MRI sequences for joint imaging in 3T / 강창호, 고려의대 33

09:30 ~ 10:00 Technical details for pain intervention / 권종원, 상경련의대 61

10:00 ~ 10:30 coffee break

10:30 ~ 11:00 How to build a pain intervention practice in the academic environment / 이은주, 서울의대 67

11:00 ~ 11:30 How to build a pain intervention practice in the community environment / 김성현, 후천영상의학센터 81

2010.4.16~17 제주도. 리미다 플라자 호텔

3 | 연수교육

1) 대한근골격영상의학회 연수교육 리스트

년도	날짜	교육주제	교육장소	주관	모임구분	평점
2010	11.14	근골격계 영상진단	2강의실	서울대	연수교육	
	08.28	Radiology-Pathology Correlation 2010 : Chest Disease and Soft Tissue Tumors	암센터 B1 대강당	삼성 병원	심포지움	
	05.16	근골격계 단순촬영의 이해	본관 B1 대강당	골영회	연수교육	5
	04.16 ~ 04.17	20 Years History of Korean Society of Musculoskeletal Radiology Musculoskeletal Imaging Modality and Techniques Optimization of MRI Sequences and Protocol	라마다 플라자 제주호텔	골영회	춘계학회	5
2009	04.26	Imaging of the lower extremity	고려대 인촌기념관	골영회	연수교육	5
	04.10	Musculoskeletal System Application of Ultrasonography and MRI Radiologist's Role in Pain Intervention	경주 교육 문화회관	골영회	춘계학회	5
	02.22	척추영상의학	서울아산병원 대강당	추영회	연수교육	6
2008	11.	흔한 근골격계 질환에 대한 영상의학적 평가와 진단	서울대학교 병원	서울대	연수교육	
	06.22	Imaging of the upper extremity	고려대 인촌기념관	골영회	연수교육	5
	04.06	Musculoskeletal ultrasound 연수교육 및 workshop 2008	분당서울대 병원대강당	분당 서울대	연수교육	
	04.25	Musculoskeletal application of molecular imaging and 3T MRI	강릉 아산 병원 강당	골영회	춘계학회	3
	02.17	척추 영상의학 연수강좌	서울아산 제1연구동 지하강당	추영회	연수교육	6

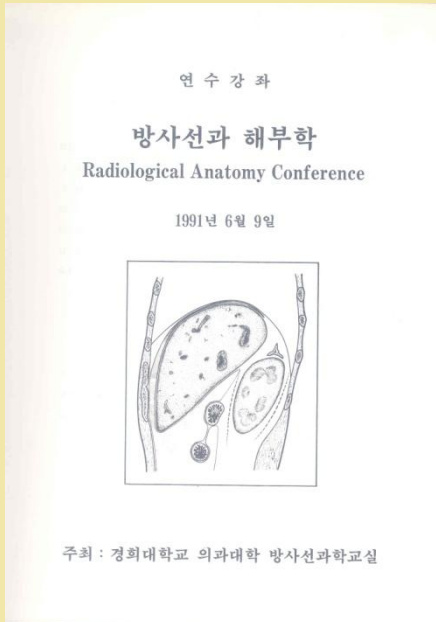
2007	06.17	Arthritis and metabolic bone disease	연세대 은명대강당	골영회	연수교육	5
	04.20	Musculoskeletal Imaging	전북대병원	골영회	춘계학회	3
2006	11.	Musculoskeletal Imaging & Intervention	서울대병원	서울대	연수교육	5
	09.30	The 2nd international high-field MRI symposium	삼성서울병원 대강당	삼성 의료원	삼포지움	
	06.04	Essentials of Musculoskeletal Imaging	서울아산병원 대강당	골영회	연수교육	6
	03.31	Musculoskeletal Imaging	을지대병원	골영회	춘계학회	3
2005	11.06	Musculoskeletal Plain Radiography: Correlation with Other Imaging Modalities	서울대병원 소아임상 1,2 강의실	골영회	연수교육	5
	03.26	통증 인터벤션 workshop 2005	분당서울대 병원대강당	분당 서울대	워크샵	
	04.16	Musculoskeletal Trauma Imaging	부산대병원 응급의료센터 9층	골영회	춘계학회	3
	04.24	Musculoskeletal ultrasound 연수교육 및 workshop 2005	분당서울대 병원대강당	분당 서울대	연수교육	
2004	09.02 ~04	제6차아시아근골격방사선학회학술대회 (BONE TUMOR AND OSTEOPOROSIS)	롯데호텔 잠실	골영회	국제학회	18
	04.10	Rheumatology	김해관광 호텔대강당	골영회	춘계학회	3
	06.06	MSUS seminar 2004 in Korea	분당서울대 병원 강당	초음파 학회	연수강좌	
2003	04.12	Spine imaging	충주수안보 파크호텔	골영회	춘계학회	3
	11.	Musculoskeletal Radiology	서울대병원	서울대	연수교육	
2002	04.13	근골격계방사선과학의 최신지견	에드미랄 호텔(경남)	골영회	춘계학회	4
2001	11.10 ~11	The 11th International Seoul Radiology Symposium : Musculoskeletal Radiology	서울대병원	서울대	심포지움	
1999	11.	Musculoskeletal Radiology	서울대병원	서울대	연수교육	
	03.21	Radiological anatomy conference	경희대병원	경희대	연수교육	

	04.11	Radiological pathologic conference	경희대병원	경희대	연수교육	
1998	09.06	Musculoskeletal Imaging	연세대학교 의대 강당	연세대	연수교육	
1997	11.	Musculoskeletal Radiology	서울대병원	서울대	연수교육	
	03.02	Radiological anatomy conference	경희대병원	경희대	연수교육	
	04.06	Radiological pathologic conference	경희대병원	경희대	연수교육	
1995	11.	Musculoskeletal Radiology	서울대병원	서울대	연수교육	
	03.05	Radiological anatomy conference	경희대병원	경희대	연수교육	
	04.16	Radiological pathologic conference	경희대병원	경희대	연수교육	
1993	03.07	Radiological pathologic conference	경희대병원	경희대	연수교육	
	05.30	Radiological anatomy conference	경희대병원	경희대	연수교육	
1992	11.	Imaging Diagnosis in Musculoskeletal System	서울대병원	서울대	연수교육	
1991	06.09	Radiological anatomy conference	경희대병원	경희대	연수교육	

2) 연수교육 내용



91년 연수강좌

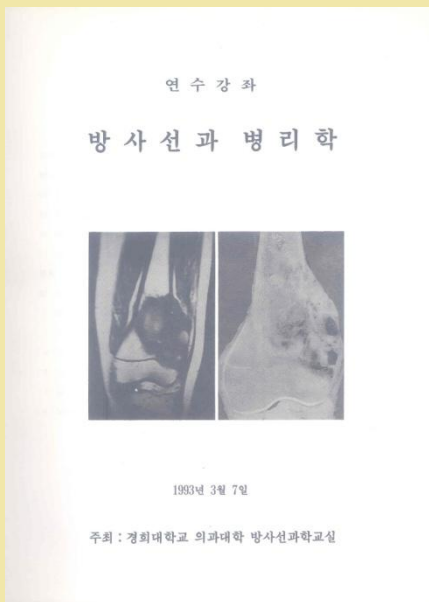


목 차

오전	
9:00-9:40	Brain, supratentorial 장기현-1
9:40-10:20	Brain, infratentorial 최규호-19
10:20-10:40	휴식
10:40-11:20	Sella, parasella and skull base 이종철-27
11:20-12:00	Spinal cord and its cover 정태성-37
오후	
1:10-1:50	Bone in general 박종구·윤경남-41
1:50-2:30	Vertebrae and sacroiliac joint 류경남-51
2:30-2:50	휴식
2:50-3:30	Shoulder and wrist 장홍식-67
3:30-4:10	Hip joint 이선화-76
4:10-4:50	Knee joint 신명진-84
4:50-	Quiz시험

1991.6.9

93년 연수강좌

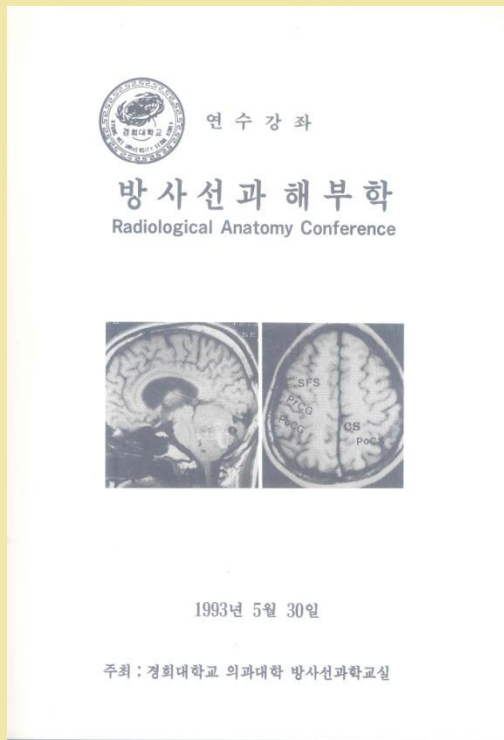


목 차

오전	
09:00-09:50	Neuropathology 지계근-1
09:50-10:30	Brain tumors 최규호-15
10:30-10:50	휴식
10:50-11:30	Sella and parasellar tumors 최추석-24
11:30-12:10	Inflammatory diseases of the brain 장기현-31
오후	
12:10-1:10	점심
1:10-1:50	Spinal cord diseases 은종기-44
1:50-2:30	Vertebral disease 신명진-53
2:30-2:50	휴식
2:50-3:30	Bone tumors 류경남-61
3:30-4:10	Arthritis 서경진-68
4:10-4:50	Metabolic bone disease 이선화-80

1993.3.7

93년 연수강좌2



목 차

오 전

08:30-09:00 등 록

08:50-09:00 안내 및 소개

09:00-09:40 Development of the lung and heart유 시 준--1

09:40-10:20 Pulmonary airway and interstitium임 정 기--26

10:20-10:40 휴 식

10:40-11:20 The pleura and mediastinum성 동 욱--36

11:20-12:00 The heart and pericardium임 태 환--43

12:00-1:00 점심

오 후

1:00-1:30 Muscle, tendon, bone and joint류 경 남--53

1:30-2:00 Development and physiology of bone이 선 화--61

2:00-2:40 The knee joint안 진 환--70

2:40-3:00 휴 식

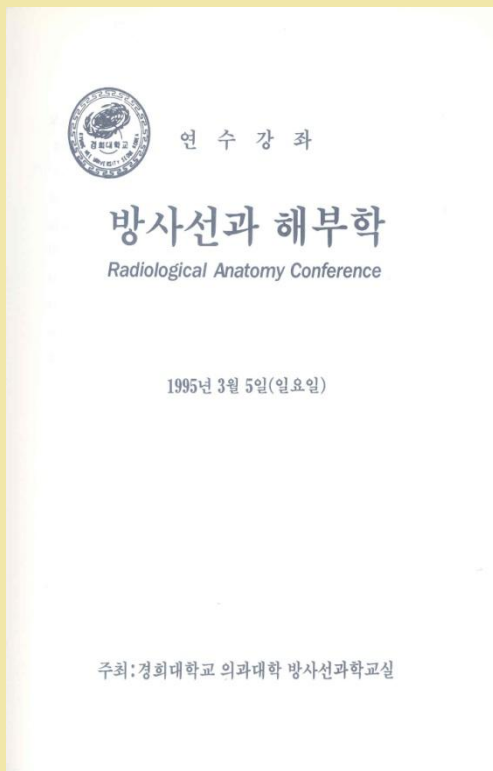
3:00-3:40 The brain최 우 석--77

3:40-4:20 The sella and parasella장 기 현--85

4:20-5:00 The spinal canal and vertebrae김 동 익--91

1993
5.30

95년 연수강좌



목 차

오 전

9:00-9:30 Supratentorial MR anatomy은 중 기(인제외대)--1

9:30-10:00 Supratentorial vascular anatomy변 홍 식(삼성의료원)--19

10:00-10:30 Infratentorial MR anatomy김 상 준(단국외대)--47

10:30-10:50 휴 식

10:50-11:20 Infratentorial vascular anatomy최 우 석(경희외대)--55

11:20-11:50 Spine and spinal cord anatomy경 태 심(인제외대)--63

11:50-12:20 Spinal vascular anatomy최 우 석(경희외대)--76

12:20-1:20 점심

오 후

1:20-1:50 Pharynx and laryngeal anatomy이 호 규(울산외대)--86

1:50-2:20 Temporal bone anatomy한 문 회(서울외대)--93

2:20-2:50 Development and physiology of the bone이 선 화(이화외대)--103

2:50-3:10 휴 식


3:10-3:40 Hip joint경 선 관(원광외대)--114

3:40-4:10 Shoulder joint강 홍 식(서울외대)--123

4:10-4:40 Knee joint류 경 남(경희외대)--135

1995
3.5

95년 연수강좌2



연수강좌

방사선과 병리학

Radiological Pathologic Conference

1995년 4월 16일(일요일)

주최: 경희대학교 의과대학 방사선과학교실

목 차

오 전

- 9:00-9:30 Neuropathology홍 은 경 (한양외대)--- 1
- 9:30-10:00 Brain tumors최 우 석 (경희외대)--- 14
- 10:00-10:30 Sella and parasellar lesions장 기 현 (서울외대)--- 36
- 10:30-10:50 휴 식
- 10:50-11:20 Spinal cord lesions최 우 석 (경희외대)--- 46
- 11:20-11:50 Pharynx and laryngeal lesions한 분 희 (서울외대)--- 53
- 11:50-12:20 Neck and salivary gland lesions윤 은 경 (고려병원)--- 57
- 12:20-1:20 점 심

오 후

- 1:20-1:50 Pathology of the hip joint서 경 진 (경북외대)--- 70
- 1:50-2:20 Pathology of the shoulder joint이 용 결 (경희외대)--- 78
- 2:20-2:50 Pathology of the knee joint서 진 석 (연세외대)--- 80
- 2:50-3:10 휴 식
- 3:10-3:40 Bone tumors류 경 남 (경희외대)--- 85
- 3:40-4:10 Pathology of chondrogenic tumors박 용 구 (경희외대)--- 93
- 4:10-4:40 Soft tissue tumors이 영 속 (고려병원)---114

1995
4.16

97년 연수강좌 1

연수강좌

방사선과 해부학

Radiological Anatomy Conference

(뇌신경계 및 근골격계)

1997년 3월 2일 (일요일)

주최: 경희대학교 의과대학 방사선과학교실

목 차

오 전

- 9:00-9:30 Supratentorial functional MR anatomy최 우 석 (경희외대)--- 1
- 9:30-10:00 Supratentorial vascular anatomy서 대 철 (울산외대)--- 15
- 10:00-10:30 Infratentorial functional MR anatomy서 경 진 (연남외대)--- 23
- 10:30-10:50 휴 식
- 10:50-11:20 Infratentorial vascular anatomy변 흥 식 (삼성의료원)--- 38
- 11:20-11:50 Spine and spinal cord anatomy김 의 홍 (경희외대)--- 52
- 11:50-12:20 Spinal vascular anatomy김 동 식 (연세외대)--- 63
- 12:20-13:20 점 심

오 후

- 1:20-1:50 Oropharynx and laryngeal anatomy이 남 준 (고려외대)--- 70
- 1:50-2:20 Orbit anatomy최 규 호 (가톨릭외대)--- 82
- 2:20-2:50 Development and physiology of the bone이 선 화 (이화외대)--- 88
- 2:50-3:10 휴 식
- 3:10-3:40 Hip joint설 미 숙 (가톨릭외대)--- 97
- 3:40-4:10 Shoulder joint신 명 진 (울산외대)---102
- 4:10-4:40 Knee joint류 경 남 (경희외대)---105

1997
3.02

97년 연수강좌 2

연 수 강 좌

방사선과 병리학

Padiological Pathology Conference

1997년 4월 6일 (일요일)

주최: 경희대학교 의과대학 방사선과학교실

목 차

오 전

9:00-9:30	Basic neuropathology	홍 은 경 (한양대)...	1
9:30-10:00	Pathologic correlation of brain tumors	장 기 현 (서울대)...	8
10:00-10:30	Sella and parasellar tumor	최 우 석 (경희대)...	15
10:00-10:50	휴 식		
10:50-11:20	Pathologic correlation of spinal cord lesion	정 태 섭 (연세대)...	30
11:20-11:50	Oropharynx and laryngeal lesion	이 호 규 (울산대)...	42
11:50-12:20	Neck and salivary gland lesion	이 남 준 (고려대)...	53
12:20-13:20	점 심		
13:20-13:50	Shoulder: rotator cuff & instability	권 순 태 (충남대)...	76
13:50-14:20	Knee: Ligament & menisci	박 진 균 (전남대)...	83
14:20-14:50	Infections of bone & soft tissues	서 정 진 (경북대)...	91
14:50-15:10	휴 식		
15:10-15:40	Articular diseases	강 홍 석 (서울대)...	104
15:40-16:10	Bone tumors	류 경 남 (경희대)...	113
16:10-16:40	Hot topics in osteopathology	박 용 구 (경희대)...	135


1997
4.06

99년 연수강좌 1

연 수 강 좌

방사선 해부학

-뇌신경 및 근골격계-



일시 : 1999년 3월 21일 (일요일)
장소 : 경희대학교 중앙도서관 시청각교육실
주최 : 경희대학병원 진단방사선과

목 차

09:00-09:30	Brain functional MR anatomy	최 우 석	1
09:30-10:00	Supratentorial vascular anatomy	변 홍 석	15
10:00-10:30	Cranial nerve MR anatomy	서 정 진	35
10:30-10:50	휴 식		
10:50-11:20	Infratentorial vascular anatomy	서 대 철	53
11:20-11:50	Oropharynx and laryngeal anatomy	김 의 종	63
11:50-12:20	Pediatric neurosonography	김 인 원	77
12:20-13:20	점 심		
1:20- 1:50	Spine and spinal cord anatomy	최 규 호	85
1:50- 2:20	Spinal vascular anatomy	김 동 덕	95
2:20- 2:50	Development and physiology of the bone	이 선 화	103
2:50- 3:10	휴 식		
3:10- 3:40	Hip joint	박 정 미	113
3:40- 4:10	Shoulder joint	권 순 태	121
4:10- 4:40	Knee joint	류 경 남	129

1999
3.21

99년 연수강좌 2

연수강좌

방사선 병리학 -뇌신경 및 근골격계-

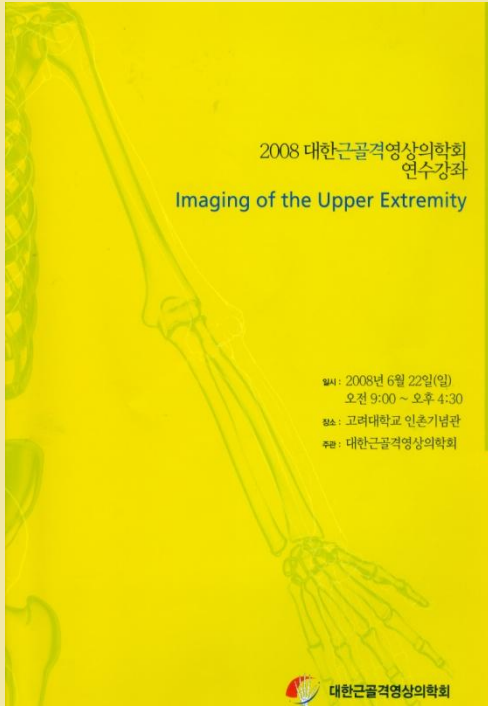


일시 : 1999년 4월 11일 (일요일)
장소 : 경희대학교 중앙도서관 시청각교육실
주최 : 경희대학병원 진단방사선과

목차

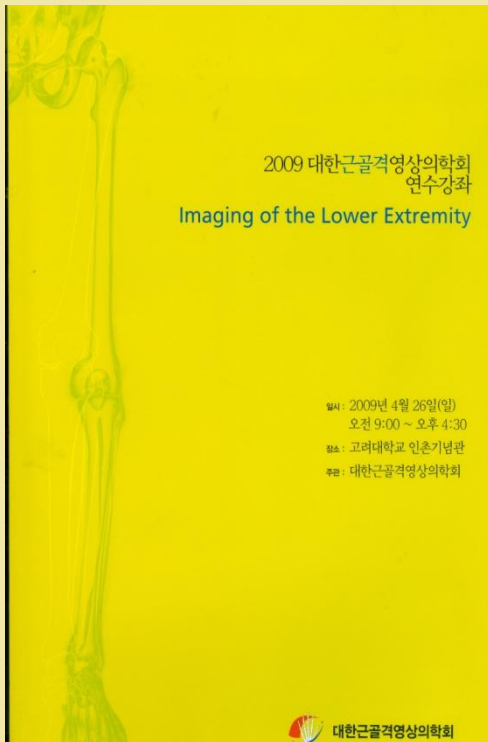
09:00-09:30	Basic neuropathology	홍은경	1
09:30-10:00	Pathologic correlation of brain tumors	최우석	15
10:00-10:30	Sella and parasellar tumor	김동익	31
10:30-10:50	휴식		
10:50-11:20	Pediatric Brain Tumor	김인원	41
11:20-11:50	Oropharynx and laryngeal lesion	이남준	53
11:50-12:20	Neck and salivary gland lesion	이호규	67
12:20-13:20	점심		
1:20- 1:50	Bone tumor : Margin	강홍식	85
1:50- 2:20	Bone tumor : Periosteal reaction	신명진	93
2:20- 2:50	Bone tumor : Matrix	서진석	101
2:50- 3:10	휴식		
3:10- 3:40	Osteopathology in bone tumor	박용구	109
3:40- 4:10	Soft tissue tumor	서경진	127
4:10- 4:40	US of tumor and tumor-like lesions	류경남	137

1999
4.11



목 차	
08:40 ~ 09:00	사전등록 및 Introduction
I. Shoulder	
09:00 ~ 09:30	Anatomy of the shoulder / 조길호 영남의대 7
09:30 ~ 10:00	Impingement and rotator cuff disorder / 최정아 서울의대 13
10:00 ~ 10:30	Glenohumeral instability / 윤영철 상균의대 25
10:30 ~ 10:50	Miscellaneous lesions / 하두희 포천중문의대 33
10:50 ~ 11:10	Coffee break
II. Elbow	
11:10 ~ 11:30	Anatomy of the elbow / 김지영 가톨릭대 43
11:30 ~ 11:50	Ligament injuries of the elbow / 이상훈 울산의대 49
11:50 ~ 12:10	Tendon abnormalities of the elbow / 박지선 경희대 57
12:10 ~ 13:30	Lunch
III. Wrist and hand	
13:30 ~ 14:00	Anatomy of the wrist and hand / 황지영 이화여대 71
14:00 ~ 14:30	Abnormalities in the ligaments and TFC / 박정미 가톨릭대 79
14:30 ~ 15:00	Tendon abnormalities of the wrist and hand / 이영환 대구가톨릭대 87
15:00 ~ 15:20	Coffee break
IV. Brachial plexus and nerve	
15:20 ~ 15:40	Anatomy of the brachial plexus / 서경진 동국대 103
15:40 ~ 16:00	Pathology of the brachial plexus / 서경진 동국대 103
16:00 ~ 16:30	Entrapment neuropathies in the upper extremities / 최수정 울산의대 115

**2008
6.22**



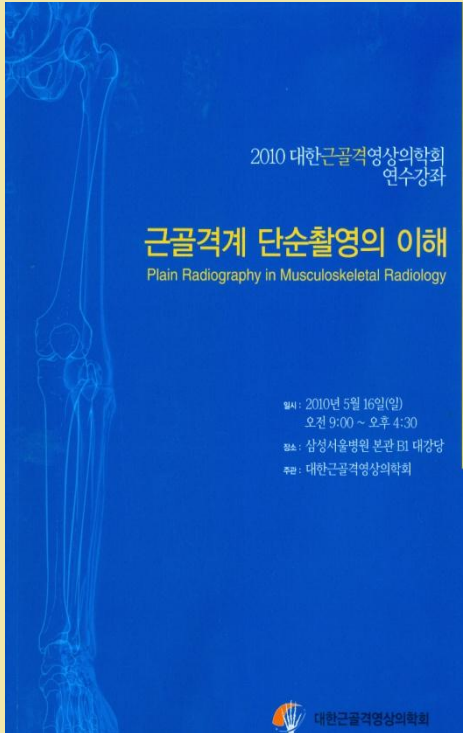
목 차	
08:40 ~ 09:00	사전등록 및 Introduction
I. Hip	
09:00 ~ 09:20	Anatomy of the hip / 천경아 가톨릭의대 9
09:20 ~ 09:50	Overuse and sport injury related abnormality / 차장규 순천향의대 15
09:50 ~ 10:20	Osseous lesions / 홍성환 서울의대 25
10:20 ~ 10:40	Femoroacetabular impingement / 권순태 충남의대 37
10:40 ~ 11:00	Coffee break
II. Knee	
11:00 ~ 11:20	Anatomy of the knee / 박규성 아주의대 47
11:20 ~ 11:50	How to approach chronic knee pain / 최상의 성균관의대 65
11:50 ~ 12:20	How to approach traumatic knee / 진 옥 경희의대 71
12:20 ~ 13:40	Lunch
III. Foot and ankle	
13:40 ~ 14:10	Anatomy of the foot and ankle / 이상용 전북의대 85
14:10 ~ 14:40	How to approach chronic pain of ankle and foot / 최윤선 을지의대 93
14:40 ~ 15:10	How to approach traumatic ankle and foot / 김철준 연세의대 103
15:10 ~ 15:30	Coffee break
IV. Interventional musculoskeletal radiology	
15:30 ~ 16:00	Pain intervention for extremity / 고영환 서울의대 123
16:00 ~ 16:30	Compartmental anatomy and biopsy strategy / 이준우 서울의대 133

**2009
4.26**

2010 대한근골격영상의학회
연수강좌

근골격계 단순촬영의 이해
Plain Radiography in Musculoskeletal Radiology

일시: 2010년 5월 16일(일)
오전 9:00 ~ 오후 4:30
장소: 삼성서울병원 본관 B1 대강당
주최: 대한근골격영상의학회



대한근골격영상의학회

2010 대한근골격영상의학회 연수강좌

- 주 제: 근골격계 단순촬영의 이해
- 일 시: 2010년 5월 16일 (일요일) 09:00~16:30
- 장 소: 삼성서울병원 본관 B1 대강당
- 주 관: 대한근골격영상의학회

8:40-9:00	사전등록 및 Introduction	
09:00-09:30	Development of bone and variant	성균관대 유소영 • 7
09:30-09:50	Shoulder girdle	이화대 황지영 • 15
09:50-10:10	Elbow and forearm	가톨릭대 박경미 • 25
10:10-10:30	Wrist and hand	연세의대 이상용 • 33
10:30-10:50	Coffee break	
10:50-11:20	Pelvic girdle	동국대 서경천 • 39
11:20-11:50	Knee, ankle and foot	연세의대 송호택 • 47
11:50-13:20	Lunch	
13:20-13:50	Bone age	단국대 이영석 • 57
13:50-14:10	Cervical spine and craniocervical junction	원광대 정선관 • 67
14:10-14:30	Thoracic spine and thoracic cage	울산대 최수경 • 77
14:30-14:50	Lumbar spine	충남대 권순태 • 85
14:50-15:10	Coffee break	
15:10-15:30	Fracture: interpretation	성균관대 권종원 • 91
15:30-15:50	Fracture: healing and complication	포천중문의대 하두희 • 101
15:50-16:10	Orthopedic hardware	한림대 양 익 • 109
16:10-16:30	Postoperative plain radiography	경희대 박지선 • 121

**2010
5.16**

**Radiology-Pathology Correlation 2010:
Chest Diseases and Soft Tissue Tumors**

“영상을 이해하면 병리가 보인다!”



일시: 2010년 8월 28일 (토)
장소: 삼성서울병원 암센터 지하1층 대강당
주최: 삼성서울병원 영상의학과
후원: Bayer Korea (주)
Bracco Korea

**RADIOLOGY-PATHOLOGY CORRELATION 2010:
CHEST DISEASE AND SOFT TISSUE TUMORS**

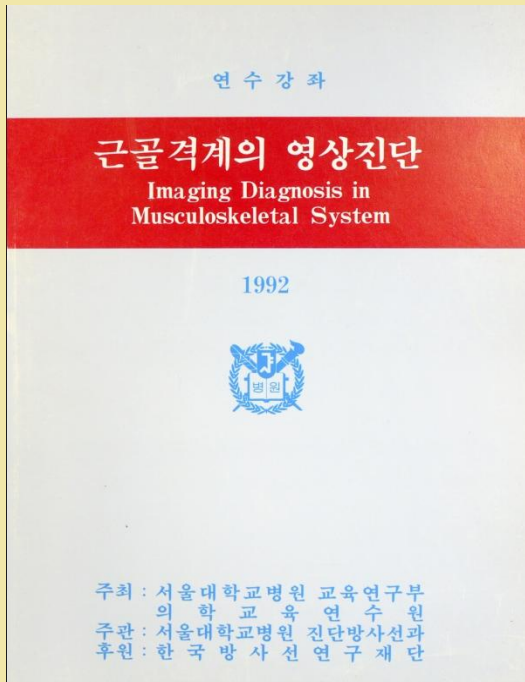
일시: 2010년 8월 28일 (토)
장소: 삼성서울병원 암센터 지하1층 대강당

“영상을 이해하면 병리가 보인다!”

09:00 - 09:10	Opening Remark	이경수
Pulmonary Diseases		
09:10 - 09:55	Image-Pathology correlation of Pulmonary Infection	좌장: 김태성
09:55 - 10:40	Image-Pathology correlation of Lung Cancer	이진아, 한정호 이효연, 한정호
10:40 - 10:50	Coffee Break	
10:50 - 11:40	Image-Pathology correlation of Congenital Lung Disease	김지혜, 한정호
11:40 - 13:00	Lunch	
Breast and Thyroid Disease		
13:00 - 13:45	Image-Pathology correlation of Benign Breast Disease	좌장: 남석진
13:45 - 14:30	Image-Pathology correlation of Malignant Breast Disease	고은영, 조은운 한부경, 조은운
14:30 - 15:20	Image-Pathology correlation of Thyroid Disease	신정희, 오영문
15:20 - 15:35	Coffee Break	
Musculoskeletal Tumors		
15:35 - 16:20	Radiology-Pathology Correlation of Bone Tumors	좌장: 서성욱
16:20 - 17:05	Radiology-Pathology Correlation of Soft tissue Tumors	최성희, 최윤라 권종원, 최윤라
17:05 - 17:20	Quiz 시상식	최연현

**2010
8.28**

92년 연수강좌



목 차

오 전

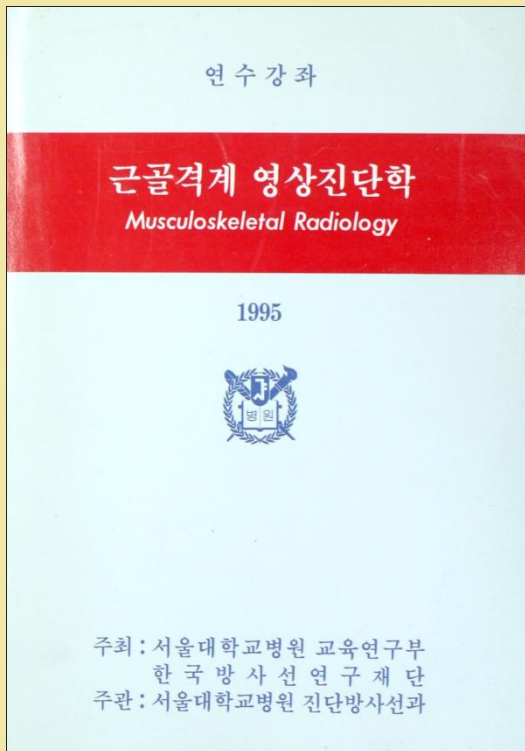
9:10-9:40 척추와 사지의 해부와 생리학..... (서울의대) 정 문 상... 1
 9:40-10:10 대사성 골질환(Metabolic Bone Diseases) (서울의대) 강 흥 식... 6
 10:10-10:50 Imaging of the Musculoskeletal Tumor (연세의대) 서 진 석...14
 10:50-11:10 휴 식
 11:10-11:40 Infectious Diseases..... (경희의대) 류 경 남...20
 11:40-12:20 Articular Diseases (경북의대) 서 경 진...30

오 후

12:20-1:20 점심 식사
 1:20-1:50 Osteonecrosis & Osteochondrosis (계명대의대) 우 영 훈...50
 1:50-2:30 MRI of the Extremities (서울의대) 강 흥 식...59
 2:30-2:50 휴 식
 2:50-3:30 MRI of the Spine (울산의대) 신 명 진...71
 3:30-4:00 골 스캔(Radionuclide Bone Scan)..... (서울의대) 이 명 철...80
 4:00-4:30 바늘구멍 신티그래피에 의한 골격계 질환의 진단..... (가톨릭의대) 박 용 휘...95
 4:30-5:00 질문 및 토의

1992.11

95년 연수강좌



목 차

오 전

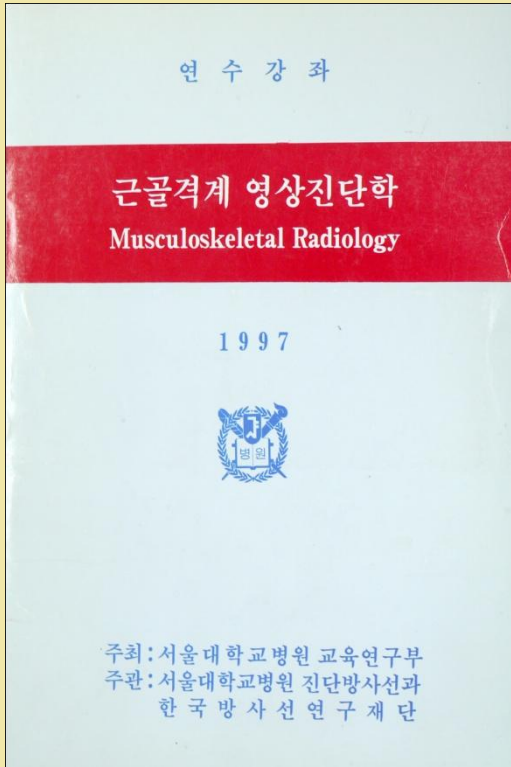
09:00-09:40 Congenital Diseases(아주의대)김 옥 화... 1
 09:40-10:30 Tumors and Tumor-like Diseases(서울의대)강 흥 식... 20
 10:30-10:50 휴 식
 10:50-11:20 Infectious Diseases(천남의대)박 진 관... 31
 11:20-12:00 Arthritides(경북의대)서 경 진... 45
 12:00-1:00 점심식사

오 후

1:00-1:40 Metabolic and Endocrine Diseases.....(울산의대)양 승 오... 61
 1:40-2:20 Degenerative Diseases(Including Spine)(경희의대)류 경 남... 71
 2:20-2:40 휴 식
 2:40-3:40 Internal Derangements of Joints
 Upper Extremity(서울의대)강 흥 식... 80
 Lower Extremity(삼성의료원)안 중 모... 94
 3:40-4:20 Osteonecrosis and Miscellaneous(원광의대)정 선 관...108
 4:20-4:50 MR Imaging Techniques(연세의대)서 진 석...133
 4:50-5:20 Radioisotope Bone Scan(서울의대)정 준 기...138

1995.11

97년 연수강좌



목 차

오 전

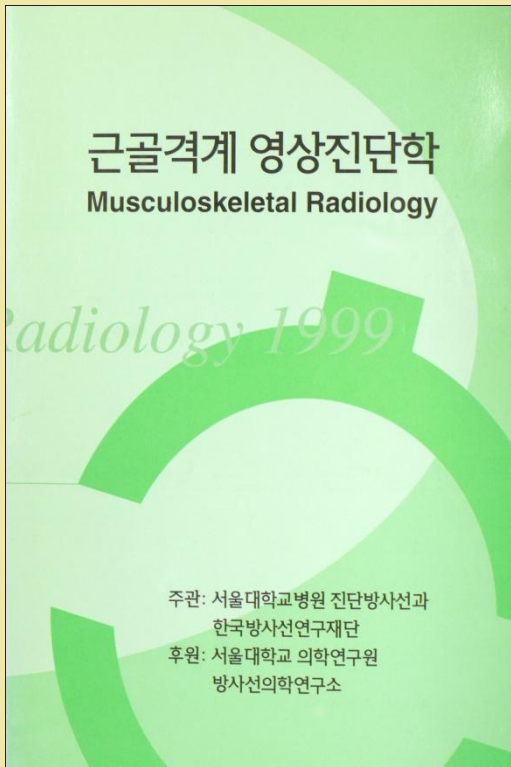
- 9:00-9:40 골종양의 방사선학적 접근 (서울의대) 강홍식 ... 1
- 9:40-10:10 감염성 질환 (전남의대) 박진균 ... 13
- 10:10-10:30 휴 식
- 10:30-11:10 관절염 (경북의대) 서경진 ... 25
- 11:10-11:40 무혈성 괴사 (경희의대) 류경남 ... 40
- 11:40-12:10 외상성 골절환 (울산의대) 신명진 ... 50
- 12:10-13:10 점심식사

오 후

- 13:10-13:50 무릎관절 (가톨릭의대) 성미숙 ... 59
- 13:50-14:20 어깨관절 (충남의대) 권순태 ... 74
- 14:20-14:50 손목 및 발목관절 (연세의대) 서진석 ... 86
- 14:50-15:10 휴 식
- 15:10-16:00 척추질환 (서울의대) 강홍식 ... 97
- 16:00-16:30 대사성 골질환 (울산의대) 양승오 ... 113
- 16:30-17:00 동위원소 골스캔 (서울의대) 정준기 ... 131

1997.11

99년 연수강좌



목 차

- 09:00-09:30 뼈의 생리 및 대사성 질환 이 상 용 ... 1
- 09:30-09:55 골다공증의 진단 임 승 오 ... 11
- 09:55-10:20 무혈성 괴사 이 상 문 ... 33
- 10:20-10:35 휴식
- 10:35-11:05 관절염 홍 성 환 ... 41
- 11:05-11:35 감염성 질환 정 해 원 ... 59
- 11:35-12:10 골종양의 방사선학적 접근 강 홍 식 ... 69
- 12:10-13:20 점심식사
- 13:20-13:40 자기공명영상 촬영 protocol 안 중 모 ... 81
- 13:40-14:10 무릎관절 성 미 숙 ... 89
- 14:10-14:40 어깨관절 류 경 남 ... 103
- 14:40-15:10 MR 관절조영술 권 순 태 ... 117
- 15:10-15:30 휴식
- 15:30-16:00 골수 영상 박 정 미 ... 129
- 16:00-16:30 척추: 추간판 질환 강 홍 식 ... 141
- 16:30-16:50 척추: 압박골절 신 명 진 ... 149
- 16:50-17:10 척추: 수술후 변화 김 성 문 ... 153


1999.11

2001년 연수강좌

The 11th International Seoul Radiology Symposium

Musculoskeletal Radiology

2001년 11월 10일



일시 : 2001년 11월 10일(토)-11일(일)
 장소 : 서울대학교병원 A강당
 주최 : 서울대학교 의과대학 방사선과학교실
 후원 : 서울대학교 의학연구원 방사선의학연구소
 한국방사선연구재단
 두뇌한국21 인건생명과학연구단

목 차

November 10, 2001(Sat)

14:00-14:10	Opening remark Kee-Hyun Chang
Musculoskeletal Tumors		
14:10-14:30	Bone destruction and periosteal reaction Heung Sik Kang 1
14:30-15:00	Judicious imaging of the solitary bone tumor Murali Sundaram 9
15:00-15:20	Multiple bony lesions Joong Mo Ahn 27
15:20-15:50	Surface lesions of bone Masataka Uetani 30
15:50-16:10	Break	
16:10-16:30	Osseous tumors Jin Suk Suh 32
16:30-16:50	Cartilage tumors Kyung Nam Ryu 39
16:50-17:20	Fibrous dysplasia of bone Murali Sundaram 48
17:20-17:50	MR imaging of intra- and juxta-articular mass lesions Masataka Uetani 49
17:50-18:10	Radionuclide imaging of bone tumors Seung Oh Yang 52

2001
11.11~12

2003년 연수강좌

근골격계 영상진단학

Musculoskeletal Radiology

Radiology 2003

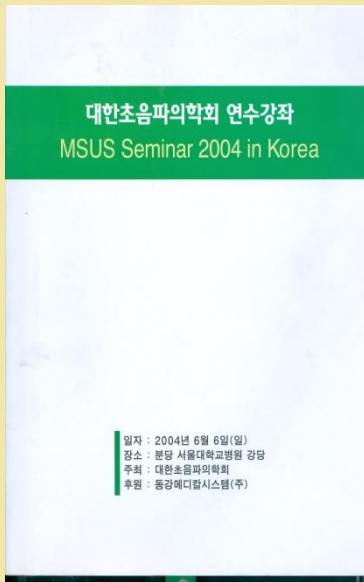
주관 : 서울대학교병원 진단방사선과
 한국방사선연구재단
 서울대학교병원 교육연구부
 후원 : 서울대학교 의학연구원
 방사선의학연구소

목 차

9:00-9:25	Cartilage diseases and Osteochondral lesion 정혜원 1
9:25-9:45	Synovial diseases-RA and RA variants 홍성현 13
9:45-10:05	Synovial diseases-Others 박진균 21
10:05-10:25	Crystal diseases 김홍식 33
10:25-10:40	휴식	
10:40-11:10	Osteoporosis and bone densitometry 양승모 39
11:10-11:40	Metabolic diseases 최정아 59
11:40-12:00	Connective tissue diseases 홍성현 69
12:00-13:20	휴식	
13:20-13:40	Hematopoietic diseases 김성문 77
13:40-14:00	Osteonecrosis and Transient bone marrow edema 류경남 83
14:00-14:20	Nerve entrapment syndrome 서진석 95
14:20-14:40	Muscle disorders 박정미 105
14:40-15:00	휴식	
15:00-15:30	MR arthrography 안중모 113
15:30-16:00	Postoperative imaging 최지영 119
16:00-16:30	MS intervention, Spine 신명진 137
16:30-16:50	MS intervention, Appendicular bone and joint 김성현 143

2003.11

2004 연수강좌



목 차

- Advances and Future of Musculoskeletal Ultrasonography..... 1
 - Bouffard, Antonio
- 어깨 초음파검사: 해부학 및 검사방법 3
 - 조길호
- Shoulder Ultrasonography: pathology 5
 - 최두희
- HRUS of elbow 11
 - Choi, Hong-Jen
- Elbow: pathology 15
 - 최경남
- Wrist and hand: anatomy with live demo 17
 - 정석현
- Wrist and hand: pathology 25
 - Choi, Hong-Jen
- US of bone and related disease 34
 - 조길호
- US of muscle 36
 - 이영환
- US of pediatric hip 40
 - 김연원
- Knee: anatomy with live demo 44
 - Bouffard, Antonio/ 이상문
- Knee: pathology 48
 - 이상문
- Ankle and foot: anatomy with live demo 54
 - 이상훈
- Ankle and foot: pathology 57
 - 최유진
- US of peripheral nerve 61
 - 이상문
- Interventional US 65
 - 이종민

2004. 6.06
분당서울대병원(조음파)

2005 연수강좌



목 차

Part. I: Clinical approach & imaging diagnosis for pain

- 2:00 - 2:20 Neck pain & cervical radiculopathy 1
 - 정진섭 (분당서울대병원 영상의학과)
- 2:20 - 2:40 Low back pain & lumbar radiculopathy 9
 - 홍성진 (분당서울대병원 신경학과)
- 2:40 - 3:00 Imaging of low back pain 15
 - 홍성훈 (서울대병원 영상의학과)
- 3:00 - 3:20 Imaging of peripheral joint for pain management 23
 - 최지영 (서울대병원 영상의학과)
- 3:20 - 3:30 Coffee break

Part. II : Interventional pain management- Video demonstration & workshop

- 3:30 - 4:10 Spine injection 32
 - 이훈우 (분당서울대병원 영상의학과)
- 4:10 - 4:50 Vertebroplasty 43
 - 김성훈 (분당서울대병원 영상의학과)
- 4:50 - 5:30 US-guided procedures for pain management 47
 - 고원훈 (연세대학교 영상의학과)

2005. 3.26
분당서울대병원(통증)



Musculoskeletal Ultrasound 연수교육 및 Workshop 2005

일시: 2005년 4월 24일 08:30-16:30
장소: 분당서울대학교 병원 강당 (지역 1동)

- 8:30- 9:40 Opening remark 1
 - 최희석
- 9:40- 9:50 Shoulder: anatomy 1
 - 조길호
- 9:50- 9:55 Shoulder: pathology 4
 - 최두희
- 9:55- 9:58 Elbow: anatomy and pathology 11
 - 최경남
- 9:58-10:20 Wrist and Hand: anatomy and pathology 17
 - 정석현
- 10:20-10:40 Coffee break
- 10:40-11:15 Knee: anatomy and pathology 21
 - 이상문
- 11:15-11:35 Ankle and Foot: Anatomy 28
 - 이상훈
- 11:35-11:55 Ankle and Foot: Pathology 33
 - 최유진
- 11:55-13:00 Lunch
- 13:00-13:20 US of Pediatric hip 37
 - 김연원
- 13:20-13:50 US of Muscle and Peripheral Nerve 41
 - 이영환
- 13:50-14:10 Mass evaluation by US 47
 - 최지영
- 14:10-14:35 Interventional US 51
 - 이종민
- 14:30-16:30 Hands-on-Workshop 51
 - 이종민, 최지영, 정석현, 이상훈, 이상문, 조길호, 최두희, 최경남, 최유진

2005. 4.24
분당서울대병원(조음파)

2006년 연수 강좌

근골격 영상의학
Musculoskeletal Imaging and Intervention

Radiology 2006

주관 : 서울대학교병원 진단방사선과
한국방사선연구재단
서울대학교병원 교육연구부
후원 : 서울대학교 의학연구원
방사선의학연구소

목 차

09:00-09:30	Osteoarthritis and Rheumatoid Arthritis	박진균(전남의대)	1
09:30-10:00	Spondyloarthropathy	홍성환(서울의대)	21
10:00-10:30	Crystal Deposition diseases	김홍식(서울의대)	29
10:30-10:50	휴 식		
10:50-11:10	DDX of Arthritis	서경진(단국의대)	35
11:10-11:40	Metabolic Bone Diseases	류경남(경희의대)	45
11:40-12:10	Nuclear Imaging in Musculoskeletal System	양승오(울지의대)	55
12:10-13:20	점 심		
13:20-13:40	Spinal Anatomy	최지영(서울의대)	71
13:40-14:10	Spinal Pain Intervention	이준우(서울의대)	85
14:10-14:40	USG-guided Intervention	고영환(서울의대)	95
14:40-15:00	휴 식		
15:00-15:30	Nerve Entrapment Syndrome	최수정(울산의대)	109
15:30-16:00	Muscle Diseases	최정아(서울의대)	119
16:00-16:40	Osteonecrosis and Related Diseases	홍성환(서울의대)	127

2006.11

2008년 연수 강좌

근골격영상의학
흔한 근골격계 질환에 대한 영상의학적 평가와 진단


Radiology 2008

주관 : 서울대학교병원 영상의학과
한국방사선연구재단
서울대학교병원 교육연구부
후원 : 서울대학교 의학연구원
방사선의학연구소

목 차

09:00-09:30	Osteoarthritis and Rheumatoid Arthritis	정혜원(울산의대)	1
09:30-10:00	Spondyloarthropathies	서경진(동국의대)	13
10:00-10:30	Crystal Deposition Diseases	김홍식(서울의대)	23
10:30-10:50	휴 식		
10:50-11:20	Metabolic Bone Diseases	문승규(건국의대)	27
11:20-11:50	Osteonecrosis and Related Diseases	류경남(경희의대)	33
11:50-13:10	점 심		
13:10-13:40	Muscle Disorders	최정아(서울의대)	43
13:40-14:10	Overuse Syndromes	최지영(서울의대)	49
14:10-14:40	Bone Marrow Imaging	김성준(연세의대)	58
14:40-15:00	휴 식		
15:00-15:40	MR Imaging of Musculoskeletal Trauma	안종모(Iowa University)	71
15:40-16:20	MR Imaging of Musculoskeletal Infection	홍성환(서울의대)	75
16:20-16:40	PET/CT Application in Musculoskeletal System	양승오(울지의대)	84

2008.11



목 차

A. Bone tumor

9:00-9:30 Plain radiograph 서진석 (연세의대) ... 1

9:30-10:00 Pathologic basis 이기범 (아주의대) ... 11

10:00-10:30 Surgical approach 신규호 (연세의대) ... 19

10:30-10:50 Coffee Break

10:50-11:20 Imaging of mineralized bone tumor 권순택 (충남의대) ... 31

11:20-11:50 Imaging of non-mineralized bone tumor ... 조재현 (아주의대) ... 44

11:50-12:20 Tumor in hands and feet 하두희 (중문의대) ... 55

12:20-13:30 Lunch

B. Joint Imaging

13:30-14:00 Imaging technique & artifacts 이영준 (인제의대) ... 74

14:00-14:30 Shoulder 류경남 (경희의대) ... 86

14:30-15:00 Wrist, hand, and elbow 조재민 (연세의대) ... 102

15:00-15:20 Coffee Break

15:20-15:50 Hip 나재범 (경상의대) ... 116

15:50-16:20 Knee 박진균 (전남의대) ... 127

16:20-16:50 Foot and ankle 이성문 (울산의대) ... 148

16:50-17:20 Pediatric musculoskeletal MRI 윤춘식 (연세의대) ... 164

**1998
9.06**

4 | Subspecial conference

5 | 송년 심포지움

1) 2006 송년 심포지움 (삼성의료원)

The 2nd International
High-Field MRI Symposium

At Samsung Medical Center
Sept. 30 (Sat), 2006
Main Auditorium (B1)

Samsung Medical Center
Sungkyunkwan University School of Medicine, Seoul, Korea

High-Field MRI Symposium

Sept 30 (Sat), 2006
Main Auditorium (B1), Samsung Medical Center,
Sungkyunkwan University School of Medicine,
Seoul, Korea

Monday 5th September

08:30 Registration and badge pick-up Main Auditorium, SMC

09:00 Welcome & Opening
Hyo Keun Lim, MD, Chairman, Department of Radiology, Samsung Medical Center, Korea

Session I. High-Field MRI Techniques
Chair: Hyo Keun Lim, MD Samsung Medical Center, Korea

09:10 Work in progress on the Achieva 3.0 T system Frank Hoggemaer, Philips Medical Systems 1

09:40 Advances in Molecular and Physiological Imaging with UHF MRI and UHF PET 조영제, 기암학회, 방사선학회 2

10:10 Coffee break (20 minutes)

Session II. Updates in Neuro MR (I)
Chair: Hyung Jin Kim, MD Samsung Medical Center, Korea

10:40 Perfusion: CASL, PASL, and VASO Frank Hoggemaer, Philips Medical Systems 3

11:10 MR Diffusion Tensor Imaging 문석준, 연세대학교 의과대학 4

11:40 Clinical Applications of fMRI and DTI 김근태, 삼성서울병원 영방과/영상의학과 11

12:00 Lunch break

Session III. Updates in Neuro MR (II)
Chair: Hong Sik Byun, MD Samsung Medical Center, Korea

13:20 Neurovascular MR - MR Angio & keyhole 김근태, 삼성서울병원 16

13:40 Stroke MRI Imaging 양승준, 연세대학교 의과대학 18

14:00 MR Imaging of Brain Tumor 김근태, 삼성서울병원 24

Session IV. New Frontiers in MRI
Chair: Kyung Soo Lee, MD Samsung Medical Center, Korea

14:20 Pre-Clinical Biomedical Imaging 이진원, 삼성서울병원 28

14:40 ¹H MR spectroscopy for human rectum 김근태, 삼성서울병원 31

15:00 Whole-Body MRI 이진원, 삼성서울병원 39

15:20 Musculoskeletal MR at 3.0 T 양재원, 삼성서울병원 48

15:40 Coffee break (20 minutes)

Session V. Updates on Body MRI
Chair: Won Jae Lee, MD Samsung Medical Center, Korea

16:00 Cardiac Applications of 3.0 T MRI: SMC Experiences 이진원, 삼성서울병원 54

16:20 Thoracic Imaging Using 3T MR 이진원, 삼성서울병원 64

16:40 3T MRI in Abdomen Imaging 김승준, 삼성서울병원 74

17:00 Prostate MR Imaging at 3T 김근태, 삼성서울병원 80

17:20 Closing remarks 이진원

2) 2009 송년 심포지움(가톨릭대학교)

대한근골격영상의학회 송년심포지움 2009

1부: 전공의 교육의 전망과 과제
2부: 영상기술-전도유망한 미래와
숙련되지 않은 현재의 조망

일시 : 2009년 12월 12일(토요일)
장소 : 가톨릭대학교 서울성모병원 별관 2층 임상강의실

주 관 : 대한근골격영상의학회

목 차

13:30-13:50 원정등록

13:50-14:00 대한근골격영상의학회 회장님 인사말씀 신명진 (울산의대)

1부: Prospect and Tasks for the Resident Training
좌장: 서경진 (동국의대), 류경남 (경희의대)

- 14:00-14:20 Resident Training-Future Strategy (전공의 교육의 미래 전략) 박정미 (가톨릭의대) 3
- 14:20-14:40 Examiner Guideline (시험문항 개발 유형) 최두희 (차의과학대학교) 6
- 14:40-15:00 "The Goals of Resident Education" -Current Status and Future (전공의 교육목표의 현황과 미래) 이상용 (전북의대) 14
- 15:00-15:20 전공의 교육 발전을 위한 기초발표와 토론 - 좌장

15:20-15:40 Coffee break

2부: Imaging Tools - the Promising Future and the Unaccustomed Present
좌장: 강홍식 (서울의대), 서진석 (연세의대)

- 15:40-16:10 Molecular Imaging for Personalized Cancer Medicine 위용민 (연세의대) 23
- 16:10-16:40 Bone Densitometry-Clinical Perspective 박일형 (경북의대) 30
- 16:40-17:10 Musculoskeletal PET-CT 양승오 (울지의대) 61
- 17:10-17:30 질문과 토론

17:30-18:00 대한근골격영상의학회 송회

5 | 우수 논문

1) 우수논문 시상

2004년 AMS(Asian musoulokeletal society) 정기학술대회를 우리나라에서 개최했고, 당시 AMS 회장이셨던 서울의대 강홍식 교수님 주관 하에 AMS 수익금을 기금으로 한 골영회 우수 논문 시상이 2006년부터 시작되었다. 이러한 우수논문 시상은 국내 영상의학과 전문의 및 전공의에 의해 전년도 SCI 등재 저널에 출판된 모든 논문에 대해 시상하였다. 시상자는 전문의나 전공의에 의해 전년도 SCI 등재 저널에 출판된 모든 논문에 대해 시상하였다. 시상자는 전문의나 전공의에 구별 없이 모두 제1저자로 했으며 1인 1편으로 제한했고, 시상은 춘계 골영회 정기 학술대회에서 이뤄졌다. 일인당 최고 300불이 지급되며 논문을 publish한 모든 사람에게 상금이 지급되는 국내 영상의학회 산하 학회 시상 가장 큰 액수의 우수논문 지원금 제도이다.

2) 우수논문 시상에 관한 규정

◇ 심사 대상 논문

전년도 1월부터 12월까지 SCI 대상 학술지에 게재된 full papers 논문으로서 논문의 내용은 근골격 분야 학문이어야 한다. 증례보고 및 임상화보 등 기타 논문은 제외한다.

◇ 시상내용

① JCR impact factor를 기준으로 다음과 같이 시상한다

0.5 - 1.0 미만	:\$500.00
1.0 - 2.0 미만	:\$1,000.00
2.0 - 4.0 미만	:\$1,500.00
4.0 -	:\$2,000.00

② 학술지의 impact factor는 당해 연도 JCR impact factor를 기준으로 하되, 당해 연도를 산출 할 수 없을 시 가장 최근 연도 impact factor를 적용한다.

③ 시상금액은 매년 12월 1일 기준 환율에 따른 한화를 지불한다.

◇ 신청자격

① 대한근골격영상연구회 회원이 제1저자에 한하여 시상한다.

② 회원 자격은 논문 제출 시까지 회비를 완납한 자에 한한다.

책임저자가 대한근골격영상연구회 회원이고 제1저자가 논문채택 당시 전공의 일 경우 신청 가능하며 시상은 제1저자에게 한다.

◇ 제출 서류

- 게재논문 별쇄 본 1부
- 논문게재 장려금 지원 신청서 1부
- 전공의가 제1저자의 경우 전공의 증빙서류 1부와 논문채택증명서 1부

◇ 제한사항

- 논문의 제1저자의 소속이 국내임이 명시되어야 한다.
- 당해 연도에는 동일인이 1회에 한하여 상금을 포상 받을 수 있다.

◇ 부칙

- 시상은 총회에서 수여한다.
- 규정에서 정한 것 이외에 관한 사항은 회장단 결의에 따른다.
- 이 규정은 총회에서 결의된 날로부터 시행한다.

3) 우수논문 응모 안내

대한근골격영상의학회(골영회)에서는 우수 학술 논문을 발표하는 회원들을 지원함으로써 회원들의 연구 능력 향상을 증진시키고자 다음과 같이 2009년 우수논문 발표자를 공모하여 지원하고자 하오니 많은 응모를 바랍니다.

1. 지원 자격

골영회 회원과 영상의학과 전공의가 대상이며 제1저자가 영상의학과 전공의인 경우 책임저자가 골영회 회원이어야 합니다. 지원금 지급은 제1저자에게 하며 1인 1편에 한하고 매년 응모 가능합니다. 골영회 회원은 논문 제출 시까지 회비를 완납한 경우에 한합니다.

2. 응모 자격 논문

2009년도 1월부터 12월까지 SCI 등재 정기학술지에 게재된 논문(증례보고 및 임상 화보 포함)으로서 논문의 내용은 근골격영상의학 분야이어야 합니다. SCI-는 제외합니다. 국내기관에서 이루어진 연구에 합니다.

3. 시상 내용

JCR impact factor를 기준으로 하며 제 2 항을 만족하는 경우 시상자의 수는 제한 없습니다.

0.5 - 1.0 미만 : U\$500-

1.0 - 2.0 미만 : U\$1,000-

2.0 - 4.0 미만 : U\$1,500-

4.0 이상 : U\$2,000-

(참고: 증례보고 및 임상화보는 1/2 금액을 시상하며 지원금은 2009년 12월 31일자 원화 기준 지급합니다.)

4. 응모 기한

- 2010년 3월 31일까지

5. 제출 서류

(1) 게재 논문 별쇄본 1부

(2) 우수논문 게재 장려금 지원 신청서

(대한영상의학회 홈페이지나 근골격영상의학회(<http://ksms.radiology.or.kr>) 홈페이지에서 다운로드 받아 작성)

(3) 영상학과 전공의가 제 1저자인 경우

-영상학과 전공의 증빙서류 1부를 첨부

6. 제출처 및 문의사항

분당서울대학교병원 영상학과 이준우 교수

(031-787-7616, joonwoo2@gmail.com)

7. 시상일 및 장소

-2010년도 골영회 춘계 심포지움

***별첨. 국제학술지 논문게재 장려금 지원신청서**

신청인:

소속 및 직위:

논 문 제 목					
게재 학술지	학술지명				
	ISSN 번호				
	발행기관				
	발표권/호			발표일자	
공동 발표자(7 인까지 기재하며 은행명, 계좌번호는 제 1 저자만 기재)	성 명	직 급	소 속	은행명	계좌번호

본인은 대한근골격영상연구회의 관리규정 및 지침을 준수하여 국제학술지에 논문을 게재하고 이에 장려금을 신청합니다.

200 년 월 일

첨 부 : 게재논문 1부 및 증빙서류

-제 1 저자가 전공의의 경우 전공의 증명서 및 논문채택증명서

대한근골격영상연구회 귀하

4) 우수논문 목록

*2006년

저자	소속	journal	종류	impact factor	시상금액
성미숙	가톨릭대 성가병원	Skeletal Radiology 2005;34:87-94	original article	0.88	\$500 (506500)
진욱	경희대학교 동서신의학병원	AJR 2005;184:1211- 1215	original article	2.384	\$1,500 (1519500)
황지영	이대목동병원	JUM 2005;24:1397-1402	original article	1.01	\$1,000 (1013000)
박은아 강흥식	서울대학교병원	Skeletal Radiology 2005; 34(2):108- 111	original article	0.88	\$250 (253250)
최자영	서울대학교병원	AJR 2005; 185:110-744	original article	2.384	\$750 (759750)
고성혜	한림대성심병원	Skeletal Radiology 2005;34:550-554	original article	0.88	\$250 (253250)
최정아	분당서울대학교 병원	AJR 2005; 184:193-199	original article	2.384	\$1,500 (1519500)
천경아	가톨릭대 의정부성모병원	AJR 2005; 184:655-660	original article	2.384	\$1,500 (1519500)
나재범	경상대병원	Radiology 2005;236:974-982	original article	5.076	\$2,000 (2026000)

총 금액
\$9,250
9370250

*2007년

저자	소속	journal	종류	impact factor	시상금액
차장규	순천향대학 부천병원	The British Journal of Radiology, 79 2006; 167-169	case report	1.394	\$500 (460000)
진욱	경희대학교 동서신의학병원	AJR 2006;187:887-893	origina l article	2.209	\$1,500 (1380000)
송호택	연세의대	JMRI 2006;23:29-35	origina l article	2.47	\$1,500 (1380000)
최윤선	을지의대	j Ultrasound Med 2006;25:1369-1373	case report	1.091	\$500 (460000)
이준우	서울의대	Invest Radiology 2006;41:553-559	origina l article	3.173	\$1,500 (1380000)
박지선	경희대학교	AJR 2006;187:364-370	origina l article	2.209	\$1,500 (1380000)
이인숙	부산대학교병원	AJR 2006;186:1778- 1782	origina l article	2.209	\$1,500 (1380000)
홍성환	서울의대	AJR 2006;186:961-966	origina l article	2.209	\$1,500 (1380000)
정준용	가톨릭의대	European radiology 2006;16:791-796	origina l article	2.437	\$1,500 (1380000)
정지영	성균관의대 삼성서울병원	J Comput Assist Tomogr.2006 May- Jun;30(3):501-6.	origina l article	1.369	\$1,000 (920000)
김희경	울산의대 아산병원	Skeletal Radiology 2006;35:648-658 2005;236:974-982	origina l article	0.98	\$500 (460000)

총 금액

\$13,000

11960000

*2008년

저자	소속	journal	종류	impact factor	시상금액
이경규	한림의대 한강성심병원	Acta Radiologica 2007 ;48(9):1020-1023(Nov)	case report	0.884	\$250 (234550)
김성준	연세대학교	Radiology 2007 Jan; 242(1): 225-2	original article	5.251	\$2,000 (1876400)
진욱	경희대학교 동서신의학병원	Journal of Ultrasound in Medicine	case report	1.189	\$500 (469100)
이준우	서울의대	AJNR	original article	2.279	\$1,500 (1407300)
이미정	연세대학교	Radiographics	pictorial essay	2.344	\$750 (703650)
최윤선	을지의대	Skeletal Radiology	original article	1.176	\$1,000 (938200)
이선주	부산 백병원	Skeletal radiology 2007; 36: S77-S81	case report	1.176	\$500 (469100)
곽규성	아주대학교	AJR Am J Roentgenol	original article	2.117	\$1,500 (1407300)
이상민	포천중문의대 분당차병원	AJR 2007;189(3):542-548	original article	2.117	\$1,500 (1407300)
권종원	삼성서울병원	AJR 2007;189(1):246-250	original article	2.117	\$1,500 (1407300)
강창호	고려대 안암병원	Clinical Radiology 2007;62: 479-486	original article	1.665	\$1,000 (938200)
정희선	김포공항 우리들 병원	Radiology:Volume 245:Number 2-	original article	5.251	\$2,000 (1876400)

		November 2007 584~590	article			
강병성	울산대병원	Skeletal Radiology; 36: S67-71	case report	1.176	\$500 (469100)	총 금액 \$19,000 16887600
윤영철	삼성서울병원	Acta Radiologica 48:8 869-874	origina l article	0.884	\$500 (469100)	
정승채	서울의대	Skeletal Radiology; 36: 67-71	case report	1.176	\$500 (469100)	
이인숙	부산의대	AJNR	origina l article	2.279	\$1,500 (1407300)	
김지영	가톨릭의대 성빈세트	Clinical Radiology 2007; 61:58-64	origina l article	1.665	\$1,000 (938200)	

*2009년

저자	소속	journal	종류	impact factor	시상금액
차장규	순천향대학교 부천병원	BJR(Anomalous insertion of the medial meniscus...)	origina l article	1.773	\$1,000 (1245000)
이준우	분당서울대학교 병원	AJR(Diffusion tensor imaging in...)	origina l article	2.47	\$1,500 (1867500)
김은영	서울 삼성병원	skeletal radiology (Atypical high location of the Wrisberg...)	origina l article	1.136	\$1,000 (1245000)
진욱	경희대학교 동서신의학병원	JUM(Sonographic findings of ruptured epidermal ...)	origina l article	1.151	\$1,000 (1245000)
권종원	삼성 서울병원	AJR (Pelvic bone complications	origina l article	2.47	\$1,500 (1867500)

		after radiation ...)			
차지 훈	삼성 서울병원	Skeletal Radiology (Ossifying fibromyxoid tumor invading ...)	case report	1.136	\$500 (622500)
이용 구	인제대학교 서울백병원	Jcat(Magnetic Resonance Imaging Findings of ...)	origina l article	1.509	\$1,000 (1245000)
최윤 선	을지의대 을지 병원	Radiographics (MR Imaging of Cartilage Repair...)	pictori al essay	2.542	\$750 (933750)
이소 연	가톨릭 중앙 의 료원	AJR(Radial Tear of the Medial Meniscal Root: ...)	origina l article	2.47	\$1,500 (1867500)
이인 숙	부산대학교병원	AJR (Microscopy Coil for Preoperative MRI of Small Soft- Tissue ...)	origina l article	2.47	\$1,500 (1867500)
차지 현	서울아산병원	skeletal radiology (Relationship between mucoid hypertrophy ...)	origina l article	1.136	\$1,000 (1245000)
명재 성	서울대학교병원	AJR(MR Diskography and CT Diskography with Gadodiamide- Iodinated...)	origina l article	2.47	\$1,500 (1876400)
최준 호	경희의료원	JUM (Sonographic Features of an Ossifying ...)	case report	1.151	\$500 (622500)
문승 규	건국대병원	JCAT (Metal artifact reduction by the alteration ...)	origina l article	1.509	\$1,000 (1245000)
김나 라	건국대병원	AJR(MR corner sign: value for...)	origina l article	2.47	\$1,500 (1867500)
최아	한림대성심병원	JUM(Lymphoma	case	1.151	\$500

총 금액
\$20,500
25522500

람		involving the ulnar nerve...)	report		(622500)
안영이	가톨릭중앙의료원, 성빈센트병원	AJR(Enchondroma Protuberans of the Hand)	case report	2.47	\$750 (933750)
곽규성	아주대학교병원	acta radiologica (Comparison study of intraarticular ...)	original article	0.972	\$500 (622500)
강창호	고려대학교병원	skeletal radiology (Conjoined lumbosacral nerve roots compromised by disk hernation...)	original article	1.136	\$1,000 (1245000)
송수진	서울대병원	skeletal radiology (Imaging Features Suggestive of ...)	original article	1.136	\$1,000 (1245000)

*2010년


저자	소속	journal	종류	impact factor	시상금액
강창호	고려대 안암병원	Skeletal Radiology 38(9): 877-85	원저	1.085	\$1,000
곽규성	아주대학병원	Acta Radiologica 50 (9)	원저	1.091	\$1,000
권종원	삼성서울병원	Clinical Radiology 64권 3호	원저	1.622	\$1,000
김여주	분당서울대병원	Radiology Volume 251: Number 1	원저	5.996	\$2,000
류혜진	서울대학교병원	European Radiology 2009; 19:3008-3014	원저	3.651	\$1,500
박순찬	경희의료원	journal of clinical ultrasound 37 (8)	증례 보고	0.843	\$250
박지	경희대학병원	European	증례	3.651	\$750

선		Radiology 2009; 19: 781-786	보고		
선혜영	분당서울대병원	AJR 193	증례 보고	2.94	\$750
송호택	연세대학교	AJR 192(4)	원저	2.94	\$1,500
오대근	삼성서울병원	AJR Volume 192, Issue 2,	원저	2.94	\$1,500
이근영	분당서울대병원	Radiology 253	원저	5.996	\$2,000
이연수	가톨릭 의대 대 전 성모병원	AJNR 30(5): 1062-1067	원저	2.745	\$1,500
이인숙	부산대학교병원	AJNR 30	원저	2.745	\$1,500
이준우	분당서울대병원	Skeletal Radiology 38:1077-1082	원저	1.085	\$1,000
정지영	삼성서울병원	Radiology Volume 250: Number 2	원저	5.996	\$2,000
진욱	경희대학교 동서신의학병원	JUM 2010/11/28	증례 보고	1.087	\$500
채은영	서울아산병원	Skeletal Radiology Aug-38	증례 보고	1.085	\$500
최진욱	삼성서울병원	JOURNAL OF COMPUTER ASSISTED TOMOGRAPHY Jan-33	원저	1.448	\$1,000
홍성환	서울대학교병원	Radiographics 2009 Mar- Apr;29(2):599-612	임상 화보	3.095	\$750
최정아	분당서울대병원	AJR 2009; 193:1347- 1353	원저	2.94	\$1,500

총 금액
\$23,500

6 | AMS 2004

1) 초청장



AMS 2004 Seoul

6th Annual Scientific Meeting of the Asian Musculoskeletal Society
September 1-3, 2004 Seoul, Korea

Theme: Bone Tumor and Osteoporosis

Welcome to **AMS 2004 Seoul**


6th Annual Scientific Meeting of the
Asian Musculoskeletal Society September 1-3, 2004
Seoul, Korea

Theme: Bone Tumor and Osteoporosis

Important Dates:
Deadline for submission of abstracts: July 31, 2004
Deadline for early bird: July 31, 2004

Contact: jacrad@radiol.snu.ac.kr

Korean Society of Musculoskeletal Radiology
Asian Musculoskeletal Society



Dear Colleagues,


I cordially invite you to the 6th annual scientific meeting of the Asian Musculoskeletal Society which will take place in Seoul from September 2 to 4, 2004. It will be another great occasion to exchange new ideas and expand our knowledge in the field of musculoskeletal radiology.

We at the local organizing committee are planning a scientific program of superb standards and memorable social activities.

I look forward to seeing you in Seoul in September, 2004.

Best regards,

Heung Sik Kang, M.D., PhD.
President
Organizing Committee of AMS 2004, Seoul



2) 2004 AMS 조직위원회

president	강흥식	서울대학교 분당병원	031-787-2200 016-9693-7601	kanghs@radcom.snu.ac.kr
vice pres	박진균	전남대학교 부속병원	062-220-5742 011-604-8976	parkjg@chonnam.ac.kr
sec gener	신명진	울산대학교 서울아산병원	02-3010-4367 017-205-4367	mjshin@amc.seoul.kr
secretary	류경남	경희대학교 부속병원	02-958-8623 011-744-4525	t2star@khu.ac.kr
	최정아	서울대학교 분당병원	031-787-7609 016-9693-6665	jacrad@radiol.snu.ac.kr
treasurer	이주혁	국립암센터	031-920-1172 011-347-2390	ju2390@ncc.re.kr
	성미숙	가톨릭대학교부천성가병원	032-340-2184	mssung99@catholic.ac.kr
advisor	박용휘	성애병원	02-262-7389	ywbahk@hanmail.net
	서수지	계명대학교 부속병원	053-250-7767	suhsj@dsmc.or.kr
	강시원	가톨릭대학교 대전성모병원	042-220-9625	kang8801@djsungmo.com
	김병근	광주기독병원	062-650-5190	bgkim@mdhouse.com
	최득린	순천향대학교부속병원	02-709-9396	dlchoi@hosp.sch.ac.kr
sci progr	서진석	연세대학교 신촌세브란스	02-361-5840 017-250-2412	jss@yumc.yonsei.ac.kr
sci exhib	양승오	울산대학교 울산부속병원	052-250-7257	soyangmd@uuh.ulsan.kr
tec exhib	문태용	부산대학교 부속병원	051-240-7387 016-561-7387	tymn@pusan.ac.kr
pub comm	박정미	가톨릭대학교여의도성모	02-3779-2037	jmpark@catholic.ac.kr
soc prog	조길호	영남대학교 부속병원	053-620-3045 011-813-3045	khcho@med.yu.ac.kr

Organizing Committee

President	:	Heung Sik Kang, M.D.
Vice-President	:	Jin Gyoon Park, M.D.
Secretary General	:	Myung Jin Shin, M.D.
Secretary	:	Kyung Nam Ryu, M.D. Jung Ah Choi, M.D.
Treasurer	:	Joo Hyuk Lee, M.D. Mi Sook Sung, M.D.
Advisor	:	Yong Whee Bahk, M.D. Soo Jhi Suh, M.D. Si Won Kang, M.D. Byong Geun Kim, M.D. Deuk Lin Choi, M.D.

Scientific Program Committee : Jin Suck Suh, M.D. (chair)

Jee Young Kim, M.D.	김지영
Sang Hoon Lee, M.D.	이상훈
Yeong Hwan Lee, M.D.	이영환
Yun Sun Choi, M.D.	최윤선
Sung Hwan Hong, M.D.	홍성환

Scientific Exhibition Committee : Seung-Oh Yang, M.D. (chair)

Soon Tae Kwon, M.D.	권순태
Min Hee Lee, M.D.	이민희
In Sup Song, M.D.	송인섭
Hye Won Chung, M.D.	정혜원
Doo Hoe ha, M.D.	하두회

Technical Exhibition Committee : Tae Yong Moon, M.D. (chair)

Young Hwan Koh, M.D.	고영환
Young Sook Kim, M.D.	김영숙
Ik Yang, M.D.	양 익
Sung Moon Lee, M.D.	이성문
Soo Jung Choi, M.D.	최수정

Publication committee : Jeong Mi Park, M.D. (chair)

Sung Moon Kim, M.D.	김성문
Sun Won Park, M.D.	박선원
Sang Yong Lee, M.D.	이상용
Jong Min Lee, M.D.	이종민
Won Hee Jee, M.D.	지원희

Social Program Committee : Kil Ho Cho, M.D. (chair)

Sung Hye Koh, M.D.	고성혜
Jae Boem Na, M.D.	나재범
Yeon Soo Lee, M.D.	이연수
Seon Kwan Juhng, M.D.	정선관
Jae Hyun Cho, M.D.	조재현

3) 제1차 조직위원회

날 짜	2004년 1월 14일 목요일	시 간	17:30
장 소	분당 서울대병원		
참 석 자	조직위	강흥식교수님, 신명진교수님, 류경남교수님, 최정아선생님	
	M & C	정덕영이사, 송민영팀장, 이재은	
차기 회의	1월 19일 17:30 (잠실롯데호텔)		
회의 항목	<input checked="" type="checkbox"/> 기획 / <input type="checkbox"/> 학술 / <input type="checkbox"/> 재정 / <input type="checkbox"/> 홍보 / <input type="checkbox"/> 전시 / <input type="checkbox"/> 인쇄제작		

1. 예산 확정

- ① 1차 수정 (장소 확정 후 Reconfirm)
 - 숙박지원: "비원호텔"의 경우 5박지원, "잠실롯데호텔"의 경우 3박 지원
 - Welcome Reception: 식사 이외의 음료 및 오뜨볼 추가
 - Gala Dinner: 공연 추가

- ② 장소 확정(서울대 OR 잠실롯데호텔)
 - 잠실롯데호텔 잠정적 결정, 1월 19일 17:30 롯데호텔 답사 이후 결정
 - 연회행사 비교견적 (별첨 참조)

- ③ 기기 임차비
 - 노트북 및 프린터기는 학회 기자재 사용

2. 업무 추진일정표

- ① 2월 10일 전체조직위원회 회의 (서울대 진단방사선과 회의실)
 - 세부 업무추진일정표 작성
 - 명확한 업무분장

- ② Poster Session은 호텔 답사 이후 확정
- ③ 학술: 초청연자 확정 시급 (1st Announce.와 직결됨)
- ④ 3월 연제 확정 4월 중순 2nd Announce. 발송

3. 국제회의 지원신청 조건 및 절차

- ① 관광공사, 학술진흥재단, 한국과학재단, 서울대학교, 대한의사협회, 대한방사선의학회 등 유관단체 조사중.

4) Program at a Glance

Time	Sep 02. Thu	Sep 03. Fri	Sep 04. Sat
7:30		Registration (07:30-17:00)	Registration (07:30-17:00)
8:00		Bone tumor I (08:00-10:00)	Special Lecture I Mark J. Kransdorf, M.D. Title : Common cartilage Lesion of bone (08:00-08:45)
			Osteoporosis I (08:45-10:05)
9:00	Registration (09:00-17:00)		
10:00	Opening Ceremony(10:00-10:30)	Coffee Break(10:00-10:20)	Coffee Break(10:05-10:25)
	Free Paper I (10:30-11:42)	Bone tumor II (10:20-12:20)	Osteoporosis II (10:25-11:45)
11:00	Lunch(11:42-13:00)		Lunch(11:45-13:00)
12:00		Lunch(12:20-13:30)	
13:00	Free Paper II (13:00-14:20)		Osteoporosis III (13:00-14:20)
14:00		Bone tumor and Intervention (13:30-15:30)	
	Coffee Break (14:20-14:30)		Special Lecture II Harry K. Genant, M.D. Title : The future of bone Imaging in osteoporosis (14:20-15:05)
	Announcement of the 7 th AMS		
	Announcement of the ISS		
	Case Presentation (14:40-14:50)		
15:00			Closing Remarks(15:05-15:30)
		Coffee Break(15:30-15:50)	
		Soft tissue tumor(15:50-17:50)	
16:00			
17:00	AMS General Meeting (17:00-18:00)	Free time	
18:00	Welcome Reception(08:00-20:00)	Banquet(18:00-19:30)	

● AMS 2004 Program (Refresher Course & Special Lecture) Bone Tumor

Date	Time	Lecture Title	Chair	Speaker	Country
Sep. 3	08:00~10:00	Bone tumor I	Wilfred		
	08:00~08:20	Imaging in staging of bone tumors	Peh, Jin	Wilfred Peh	Singapore
	08:20~08:40	Margin analysis of bone tumors: roles and limitations	Suck Suh	Shigeru Ehara	Japan
	08:40~09:00	Ultrasound in bone tumor		Sang Yong Lee	Korea
	09:00~09:20	Role of nuclear medicine in diagnosis of musculoskeletal tumor		Mi Jin Yun	Korea
	09:20~09:40	Bone tumor, pathologic basis		Kyung Rak Sohn	Korea
	09:40~10:00	Bone and soft tissue tumor-surgical view point		Kyoo-Ho Shin	Korea
	10:00~10:20	Coffee break			
	10:20~12:20	Bone tumor II			
	10:20~10:40	Radiology after limb salvage surgery for primary bone malignancy	Harvey Teo, Jin	Shih-chang Wang	Singapore
	10:40~11:00	Benign cartilagenous tumor	Gyoon Park	Vung Duy Nguyen	USA
	11:00~11:20	Osseous bone tumor		Sung-Moon Lee	Korea
	11:20~11:40	Fibrous dysplasia: radiologic- pathologic correlation		Mark J. Kransdorf	USA
	11:40~12:00	MR imaging of intra- and juxta-articular mass lesions		Masataka Uetani	Japan
	12:00~12:20	Imaging of simple bone cysts		Harvey Teo	Singapore
	12:20~13:30	Lunch			
	13:30~13:30	Bone tumor and intervention			
	13:30~13:50	Giant cell tumor: imaging features and staging	Bambang	John George	Malaysia
	13:50~14:10	Many cases of bone tumor in Jakarta	Budyatmoko,	Bambang Budyatmoko	Indonesia

			Myung Jin Shin	o Tuhin Sikdar	UK
14:10~14:30	Tumors and tumor-like lesions of the hand			Jae Hyun Cho	Korea
14:30~14:50	Tumors or tumor-like lesion in the foot			Yik Wong	Hong Kong
14:50~15:10	Percutaneous fluoroscopical guided biopsy of vertebral tumor				
15:10~15:30	CT guided and ultrasound guided biopsies in tumors of musculoskeletal system			Ashok Kumar Nath	Oman
15:30~15:50	Coffee break				
15:50~17:50	Soft tissue tumor				
15:50~16:10	US on pseudo-soft tissue-masses		John George,	Paulus Rahardjo	Indonesia
16:10~16:30	The role of MRI in differentiating soft tissue tumors from lesions mimicking soft tissue tumors		Tae Yong Moon	Sri Andreani Utomo	Indonesia
16:30~16:50	Imaging of soft tissue tumors			Lisa Wong	Hong Kong
16:50~17:10	Imaging of the hemangioma or angiomatous lesion of the bone and soft tissue			Mi Sook Sung	Korea
17:10~17:30	Lipomas: A not uncommon finding			Thomas S. G. Chee	Singapore
17:30~17:50	Neurofibroma versus neurilemmoma			Won-Hee Jee	Korea

● Osteoporosis

Date	Time	Lecture Title	Chair	Speaker	Country
Sep.4	08:00~08:45	Special lecture I			
		Common cartilage lesion of bone	Heung Sik Kang	Mark J. Kransdorf	USA
	08:45~10:05	Osteoporosis I			
	08:45~09:05	Osteoporosis: epidemiology in Asia	Suphaneewan Jaovisidha,	Hyun Koo Yoon	Korea
	09:05~09:25	Bone histomorphometry-the past, present, and the future	Yong-Koo Park	Yong-Koo Park	Korea
	09:25~09:45	Metabolic bone diseases and renal osteodystrophy		Hideharu Sugimoto	Japan
	09:45~10:05	Practical interpretation of DXA results		Seoung-Oh Yang	Korea
	10:05~10:25	Coffee break			
	10:25~11:45	Osteoporosis II			
	10:25~10:45	Fractional quantitative computed tomography for bone mineral density evaluation	Shih-chang Wang, Seoung-Oh Yang	Jong Min Lee	Korea
	10:45~11:05	Non-traumatic fracture in osteoporosis		Suphaneewan Jaovisidha	Thailand
	11:05~11:25	Assessment of vertebral fracture in osteoporosis		Harry K. Genant	USA
	11:25~11:45	MRI of painful vertebral fractures-benign or malignant?		Shih-chang Wang	Singapore
11:45~13:00	Lunch				
13:00~14:20	Osteoporosis III				
13:00~13:20	BMD and hip morphometry in patients with femoral fractures	Masataka Uetani, Seon Kwan	Seon Kwan Juhng	Korea	
13:20~13:40	Imaging characteristics of insufficiency fractures	Juhng	Masataka Uetani	Japan	
13:40~14:00	Percutaneous vertebroplasty		Ian Tsou	Singapore	
14:00~14:20	How to treat and prevent osteoporosis: clinician's comment		Chan Soo Shin	Korea	
14:20~15:05		Special lecture I			
		The future of bone imaging in osteoporosis	Shigeru Ehara	Harry K. Genant	USA
15:05~15:30	Closing remarks				

● Oral presentation schedule

번호	시간	제목	이름	소속
1	10:30~10:38	Imaging Findings of Unusual Complications as a Cause of Large Acupuncture Needles in Patients with Sprain of Back Muscle	I. Yang, J. E. Kim, S. J. Shin, S. Y. Ham, H. D. Kim, S. Y. Chung	Department of Radiology, Kangnam Sacred Heart Hospital, College of Medicine, Hallym University, Seoul, South Korea
2	10:38~10:46	Use of Magnetic Resonance Imaging to Predict the Clinical Outcome of Non-surgical treatment for Lumbar Intervertebral Disc Herniation	Soo-Jung Choi, Junghwan Kim ² , Myung Jin Shin ³ , Jae Seok Song ⁴ , Dae Sik Ryu, Eun-Hye Lee, Jae Hong Ahn, Seung Moon Jung, Man Soo Park	Department of Radiology and Orthopedic Surgery ² , Asan Foundation, GangNeung Asan Hospital, Department of Radiology and Orthopedic Surgery ² , Asan Foundation, GangNeung Asan Hospital, University of Ulsan College of Medicine
3	10:46~10:54	The effect of perineural steroid injection on failed back surgery syndrome with recurred symptoms of radiculopathy	Sang Min Lee ¹ , Myung Jin Shin ² , Sung Moon Kim ² , Sang Hoon Lee ² , Cheol Mok Hwang ² , Byeong Seong Kang ²	Department of Diagnostic Radiology ¹ , Pundang CHA General Hospital, College of Medicine, Pochon CHA University, Korea
4	10:54~11:02	Bone mineral density of the lumbar spine and knee osteoarthritis in Korean: data from the Korean arthritis study group	IH Park*, SH Lee, MS Park, ES Moon, YS Park, WS Cho, JT Suh, MC Lee, DK Bae, YJ Cho	Orthopaedics, Kyungpook University Hospital*, Taegu, Korea
5	11:02~11:10	Biomechanical evaluation of calcium phosphate cements for use with vertebroplasty	Suk Joo Hong ¹ , Youn-Kwan Park ² , Jung Hyuk Kim ³ , Soon Hyuck Lee ⁴ , Kyung	Department of Radiology ¹ , Department of Neurosurgery ² , Guro Hospital, Korea University College of Medicine

			Nam Ryu ⁵ , Cheol Min Park ¹	
6	11:10~11:18	Imaging findings with high statistical indices for osteomyelitis vs tumour	George J , FRCR Adan M , MBBS(UM)	Department of Radiology, University Malaya Medical Center, Malaysia
7	11:18~11:26	MR Findings of Ossifying Fibroma	Joon-Yong Jung ¹ , Won-Hee Jee ¹ , Sung Hwan Hong ² , Hye Won Chung ³ , Kyung-Nam Ryu ⁴ , Ji-Young Kim ¹ , Soo-A Im ¹ , Jeong-Mi Park ¹ , Mi-Sook Sung ¹ , Yeon-Soo Lee ¹ , Suk-Joo Hong ⁵ , Heung Sik Kang ²	Departments of Radiology, Catholic University Medical College ¹ , Seoul National Univ. College of Medicine ² , Samsung Medical Center ³ , Kyung Hee University ⁴ , Korea University ⁵ , Seoul, Korea
8	11:26~11:34	MR Imaging of Benign and Malignant Peripheral Nerve Sheath tumors	Ji Young Yoo, Byung Hee Lee, Kie Hwan Kim	Department of Diagnostic Radiology, Korea Cancer Center Hospital, Seoul, Korea
9	11:34~11:42	Sonographic findings of schwannoma and neurofibroma	Chang Ho Kang, Sang Hoon Lee, Jeong Ah Ryu, Doo Hoe Ha, Seong Moon Kim, Myung Jin Shin	Department of Radiology, Asan Medical Center, University of Ulsan College of Medicine, Seoul, Korea
10	13:00~13:08	MR imaging of Intact Posterior Cruciate Ligament Graft: in Arthroscopically Proven 21 cases	Young Cheol Yoon ¹ , Hye Won Chung ¹ , Sang Hee Choi ¹ , Jin-Hwan Ahn ²	Department of Diagnostic Radiology ¹ , Samsung Medical Center, Sungkyunkwan University School of Medicine, Seoul, South Korea
11	13:08~13:16	Injury of the tibiofibular ligament of the Ankle: Assessment with Contrast-Enhanced 3D-FSPGR MR Imaging	SeongJoon Kim, Jin-Suck Suh, Yong-Min Huh, Ho-Taek Song	Department of Diagnostic Radiology ¹ and Research Institute of Radiological Science, ² Department of

				Orthopedic Surgery, Yonsei University College of Medicine, Seoul, Korea
12	13:16~13 :24	Is Indirect MR Arthrography Useful in Diagnosis of Acetabular Labral Lesions of the Hip?	Jung-Ah Choi ^{1,2} , Kyung-Hoi Koo ³ , In-Sook Lee ^{1,2} , Joon Woo Lee ^{1,2} , Joon Bum Goo ¹ , Ja-Young Choi ¹ , Sung Hwan Hong ¹ , Heung Sik Kang ^{1,2}	Department of Radiology and Institute of Radiation Medicine, Seoul National University College of Medicine ¹ Department of Radiology, Seoul National University Bundang Hospital ² Department of Orthopedic Surgery, Seoul National University Bundang Hospital ³
13	13:24~13 :32	Reliability of 16-slice MDCT for pre-operative evaluation of total knee arthroplasty: Comparison with intra-operative measurements	In Sook Lee, Jung-Ah Choi, Joon Woo Lee ¹ , Joon Bum Koo, Ja-Young Choi, Sung Hwan Hong ² , Young Hwan Koh ³ , Il Kyu Han, Tae Kyun Kim ⁴ , Heung Sik Kang ¹	Department of Radiology, Seoul National University Bundang Hospital ¹ , Department of Radiology, Seoul National University Hospital ² , Department of Radiology, Boramae Hospital ³ Department of Orthopedic Surgery, Seoul National University Bundang Hospital ⁴
14	13:32~13 :40	Enthesitis of Achilles Tendon in Patients with Spondyloarthropathy: Imaging Findings and Pathogenesis	Sang-young Lee ¹ , Kyung-ho Chung ¹ , Sang-il Lee ² , Wan-hee Yoo ²	Dept of Radiology ¹ and Internal Medicine ² , Chonbuk National University Medical School, and Research Institute of Clinical Medicine, Republic of Korea
15	13:40~13 :48	Ultrasonography of the Trigger Fingers: On the Emphasis of the Findings of Annular Pulley	Hye Won Chung ^{1,2} , Sung Hwan Hong ¹ , Heung Sik Kang ¹	Department of Radiology and Institute of Radiation Medicine ¹ , Seoul National Univ. College of Medicine, Department of

				Radiology, Samsung Medical Center ² , Sungkyunkwan University School of Medicine, Seoul, Korea
16	13:48~13:56	Comparison between Power Doppler Ultrasonography and Nailfold Capillaroscopy for the Assessment of Microvasculature in Patients with Raynaud's Phenomenon : A preliminary report	Sang-young Lee ¹ , Young-min Han ¹ Sang-il Lee ² , Wan-hee Yoo ² ,	Dept of Radiology ¹ and Internal Medicine ² , Chonbuk National University Medical school, and Research Institute of Clinical Medicine, Republic of Korea
17	13:56~14:04	Model to Quantify Lymph Node Enhancement with Indirect Ultrasound Lymphography	Sang-Hee Choi	Department of Radiology, Samsung Medical Center, Sungkyunkwan University School of Medicine, Seoul, Korea
18	14:04~14:12	Increasing the Sensitivity of Kellgren-Lawrence Method in Evaluating the Stage of Knee Osteoarthritis by Additional Femorotibial Angle Measurement	Reny Luhur Setyani, Kahar Kusumawijaya, Angela B.M. Tulaar, Joedo Prihartono	Radiologic Departement, CiptoMangunkusumo Hospital, Jakarta-Indonesia
19	14:12~14:20	The Flexor Hallucis Longus : Tenographic Technique and Correlation of Imaging Findings with Surgery in 39 Ankles	Jae-Boem Na ^{1,2} , A. Gabrielle Bergman ^{1,3} , Lawrence M Oloff ⁴ , Christopher F. Beaulieu ¹	Department of Radiology, Stanford University Medical Center, Stanford, CA ² Department of Radiology, Gyeongsang National University, College of Medicine, Jinju, Korea ³ Franklin and Seidelmann Virtual Radiologists, El Dorado Hills, CA. ⁴ Sports, Orthopaedics and Rehabilitation, Redwood City, CA

5) (2004)년도 연수교육 실시결과 보고서

주관기관: 대한영상의학회

교육종류	교육일시	교육 제목	강사	강의시간	장소	참석인원	비고
강의	2004년 9월 2일	Imaging Findings of Unusual Complications as a Cause of Large Acupuncture Needles in Patients with Sprain of Back Muscle	Ik Yang	10:30~10:38	롯데호텔 서울·잠실	146명	
		Use of Magnetic Resonance Imaging to Predict the Clinical Outcome of Non-surgical treatment for Lumbar Intervertebral Disc Herniation	Soo-Jung Choi	10:38~10:46			
		The effect of perineural steroid injection on failed back surgery syndrome with recurred symptoms of radiculopathy	Sang Min Lee	10:46~10:54			
		Bone mineral density of the lumbar spine and knee osteoarthritis in Korean: data from the Korean arthritis study group	Il Hyung Park	10:54~11:02			
		Biomechanical evaluation of calcium phosphate cements for use with vertebroplasty	Suk Joo Hong	11:02~11:10			
		Imaging findings with high statistical indices for osteomyelitis vs tumour	John George	11:10~11:18			

교육종류	교육일시	교육 제목	강사	강의시간	장소	참석인원	비고
강의	2004년 9월 2일	MR Findings of Ossifying Fibroma	Joon-Yong Jung	11:18~11:26	롯데호텔 서울·잠실	146명	
		MR Imaging of Benign and Malignant Peripheral Nerve Sheath tumors	Ji Young Yoo	11:26~11:34			
		Sonographic findings of schwannoma and neurofibroma	Chang Ho Kang	11:34~11:42			
		MR imaging of Intact Posterior Cruciate Ligament Graft: in Arthroscopically Proven 21 cases	Young Cheol Yoon	13:00~13:08			
		Injury of the tibiofibular ligament of the Ankle: Assessment with Contrast-Enhanced 3D-FSPGR MR Imaging	Seong Joon Kim	13:08~13:16			
		Is Indirect MR Arthrography Useful in Diagnosis of Acetabular Labral Lesions of the Hip?	Jung-Ah Choi	13:16~13:24			
		Reliability of 16-slice MDCT for pre-operative evaluation of total knee arthroplasty: Comparison with intra-operative measurements	In Sook Lee	13:24~13:32			
		Enthesitis of Achilles Tendon in Patients with Spondyloarthropathy: Imaging Findings and Pathogenesis	Sang-Young Lee	13:32~13:40			
		Ultrasonography of the Trigger Fingers: On the Emphasis of the Findings of Annular Pulley	Hye Won Chung	13:40~13:48			
		Comparison between Power Doppler Ultrasonography and Nailfold Capillaroscopy for the Assessment of Microvascularity in Patients with Raynaud's Phenomenon : A preliminary report	Sang-Young Lee	13:48~13:56			

교육종류	교육일시	교육 제목	강사	강의시간	장소	참석인원	비고
강의	2004년 9월 2일	Model to Quantify Lymph Node Enhancement with Indirect Ultrasound Lymphography	Sang-Hee Choi	13:56~14:04	롯데호텔 서울·잠실	146명	
		Increasing the Sensitivity of Kellgren-Lawrence Method in Evaluating the Stage of Knee Osteoarthritis by Additional Femorotibial Angle Measurement	Reny Luhur Setyani	14:04~14:12			
		The Flexor Hallucis Longus : Tenographic Technique and Correlation of Imaging Findings with Surgery in 39 Ankles	Jae-Boem Na	14:12~14:20			
		Dr. Soetomo Hospital / Airlangga University. Surabaya	Sri Andreani Utomo	14:40-14:50			
		Pamela Youde Nethersole Eastern Hospital	Florence Cheung	14:50-15:00			
		University Malaya Medical Centre	John George	15:00-15:10			
		Nagasaki University Graduate School of Medical Sciences	Shoichiro Takao	15:10-15:20			
		Singapore General Hospital and *KK Women's and Children's Hospital	Kenneth Sheah	15:20~15:30			
		Korea Cancer Center Hospital	Ji Young Yoo	15:30~15:40			
		The Catholic University of Korea , Kangnam St. Mary's Hospital	Chae-Hun Lim	15:40~15:50			
		Seoul National University	Ja-Young Choi	15:50~16:00			
		Ewha Womens University	Ji Young Hwang	16:00~16:10			
		Asan Medical Center	Jeong Ah Ryu	16:10~16:20			
		Yonsei University College of Medicine	Sung Jun Kim	16:20~16:30			

교육종류	교육일시	교육 제목	강사	강의시간	장소	참석인원	비고
강의	2004년 9월 2일	Seoul National University (Bundang)	Jung-Ah Choi	16:30~16:40	롯데호텔 서울·잠실	146명	
		Samsung Medical Center	Hye Won Chung	16:40~16:50			
		The Catholic Univ. of Korea, St. Mary Hospital	Jung Eun Choi	16:50~17:00			
		Tan Tock Seng Hospital	Ian Tsou	17:00~17:10			
		Dr. Soetomo Hospital / Airlangga University, Surabaya	Sri Andreani Utomo	14:40-14:50			
		Pamela Youde Nethersole Eastern Hospital	Florence Cheung	14:50-15:00			
		University Malaya Medical Centre	John George	15:00-15:10			
		Nagasaki University Graduate School of Medical Sciences	Shoichiro Takao	15:10-15:20			

교육 종류	교육일 시	교육 제목	강사	강의시 간	장소	참석 인원	비 고
강의	2004 년 9월 3일	Imaging in staging of bone tumors	Wilfred Peh	08:00 ~08:20	롯데 호 텔 서울· 잠실	203 명	
		Margin analysis of bone tumors: roles and limitations	Shigeru Ehara	08:20 ~08:40			
		Ultrasound in bone tumor	Sang Yong Lee	08:40 ~09:00			
		Role of nuclear medicine in diagnosis of musculoskeletal tumor	Mi Jin Yun	09:00 ~09:20			
		Bone tumor, pathologic basis	Kyung Rak Sohn	09:20 ~09:40			
		Bone and soft tissue tumor- surgical view point	Kyoo-Ho Shin	09:40 ~10:00			
		Benign cartilagenous tumor	Vung Duy Nguyen	10:40 ~11:00			
		Osseous bone tumor	Sung-Moon Lee	11:00 ~11:20			
		Fibrous dysplasia: radiologic- pathologic correlation	Mark J. Kransdorf	11:20 ~11:40			
		MR imaging of intra- and juxta-articular mass lesions	Masataka Uetani	11:40 ~12:00			
		Imaging of simple bone cysts	Harvey Teo	12:00 ~12:20			
		Giant cell tumor: imaging features and staging	John George	13:30 ~13:50			
		Many cases of bone tumor in Jakarta	Bambang Budyatmoko	13:50 ~14:10			
		Tumors and tumor-like lesions of the hand	Tuhin Sikdar	14:10 ~14:30			
		Tumors or tumor-like lesion in the foot	Jae Hyun Cho	14:30 ~14:50			
		Percutaneous fluoroscopical guided biopsy of vertebral tumor	Yik Wong	14:50 ~15:10			
		CT guided and ultrasound guided biopsies in tumors of musculoskeletal system	Ashok Kumar Nath	15:10 ~15:30			
		US on pseudo-soft tissue-masses	Paulus Rahardjo	15:50 ~16:10			
The role of MRI in differentiating soft tissue tumors from lesions mimicking soft tissue tumors	Sri Andreani Utomo	16:10 ~16:30					

교육 종류	교육일 시	교육 제목	강 사	강의시 간	장소	참석 인원	비 고
강의	2004 년 9월 3일	Imaging of soft tissue tumors	Lisa Wong	16:30 ~16:50	롯데호 텔 서울· 잠실	203 명	
		Imaging of the hemangioma or angiomatous lesion of the bone and soft tissue	Mi Sook Sung	16:50 ~17:10			
		Lipomas: A not uncommon finding	Thomas S. G. Chee	17:10 ~17:30			
		Neurofibroma versus neurilemmoma	Won-Hee Jee	17:30 ~17:50			
강의	2004 년 9월 4일	Common cartilage lesion of bone	Mark J. Kransdorf	08:00~ 08:45	롯데호 텔 서울· 잠실	162 명	
		Osteoporosis: epidemiology in Asia	Hyun Koo Yoon	08:45~ 09:05			
		Bone histomorphometry—the past, present, and the future	Yong-Koo Park	09:05~ 09:25			
		Metabolic bone diseases and renal osteodystrophy	Hideharu Sugimoto	09:25~ 09:45			
		Practical interpretation of DXA results	Seoung-Oh Yang	09:45~ 10:05			
		Fractional quantitative computed tomography for bone mineral density evaluation	Jong Min Lee	10:25~ 10:45			
		Non-traumatic fracture in osteoporosis	Suphaneewan Jaovisidha	10:45~ 11:05			
		Assessment of vertebral fracture in osteoporosis	Harry K. Genant	11:05~ 11:25			
		MRI of painful vertebral fractures—benign or malignant?	Shih-chang Wang	11:25~ 11:45			
		BMD and hip morphometry in patients with femoral fractures	Seon Kwan Juhng	13:00~ 13:20			
		Imaging characteristics of insufficiency fractures	Masataka Uetani	13:20~ 13:40			
		Percutaneous vertebroplasty	Ian Tsou	13:40~ 14:00			
		How to treat and prevent osteoporosis: clinician's comment	Chan Soo Shin	14:00~ 14:20			
The future of bone imaging in osteoporosis	Harry K. Genant	14:20~ 15:05					

6) 결과 통보서

국제회의 유치 및 개최 지원결과 통보서

1. 행사개요

가. 행사명

○ 국 문 : 제 6 차 아시아근골격계의학회 정기학술대회

○ 영 문 : 6th AMS Annual Scientific Meeting 2004

나. 기 간 : September 2-4, 2004

다. 장 소 : 잠실 롯데호텔

라. 주 최 : 대한근골격계영상연구회

마. 주 관 : 대한영상의학회

바. 규 모 : 11 개국 223 명 (외국인 참가자수 : 25 명)

2. 지원받은 사항

-프로그램북 제작

3. 추진성과

대한관광공사의 지원으로 안내 책자 제작이 원활하게 진행되었으며

외국인 참가자들에게 좋은 홍보의 기회가 되었다고 판단됨.

4. 향후계획

현재 구체적인 계획은 없으나, 상기 학회가 아시아 회원국에서 교대로

진행되므로 추후 다시 개최될 가능성이 있음.

7) 명찰

-전문의 명찰

6th Annual Scientific Meeting of
the Asian Musculoskeletal Society

Delegate

연수교육 평점카드

발행번호 _____

1. 성명 : _____

2. 면허번호 : _____

3. 교육주제 : 2004년도 제6차 아시아근골격계
방사선의학회 학술대회

4. 교육일시 : 2004년 9월 2일~4일

5. 승인평점 : 16평점

위 사실을 확인함

교육기관 **대한영상의학회**

연수교육 평점카드

발행번호 _____

1. 성명 : _____

2. 면허번호 : _____

3. 교육주제 : 2004년도 제6차 아시아근골격계
방사선의학회 학술대회

4. 교육일시 : 2004년 9월 2일~4일

5. 승인평점 : 16평점

위 사실을 확인함

교육기관 **대한영상의학회**

Receipt

No. _____

Name : _____

Amount : _____

Detail : (Registration /Accompany Person / Banquet)

Received with thanks

Sep. _____, 2000

Organizing Committee
of 6th AMS Annual Scientific Meeting 2004

Receipt

No. _____

Institution : _____

Name : _____

Amount : _____

Detail : (Registration /Accompany Person / Banquet)

Sep. _____, 2000

Organizing Committee
of 6th AMS Annual Scientific Meeting 2004

Lunch Coupon (Sep.4)

Lunch Coupon (Sep.4)

Lunch Coupon (Sep.3)

Lunch Coupon (Sep.3)

Lunch Coupon (Sep.2)

Lunch Coupon (Sep.2)



6th Annual Scientific Meeting of
the Asian Musculoskeletal Society

Delegate

No. _____ **Receipt**


Name : _____

Amount : _____

Detail : (Registration / Accompany Person / Banquet)

Received with thanks
Sep. _____, 2004

Organizing Committee
of 6th AMS Annual Scientific Meeting 2004



No. _____ **Receipt**

Institution : _____


Name : _____

Amount : _____

Detail : (Registration / Accompany Person / Banquet)

Sep. _____, 2004

Organizing Committee
of 6th AMS Annual Scientific Meeting 2004



Lunch Coupon (Sep.4)











Lunch Coupon (Sep.3)



Lunch Coupon (Sep.2)



 6th Annual Scientific Meeting of the Asian Musculoskeletal Society		 6th Annual Scientific Meeting of the Asian Musculoskeletal Society	
<hr/>		<hr/>	
Exhibitor		Exhibitor	
Lunch Coupon (Sep.4)		Lunch Coupon (Sep.4)	
Lunch Coupon (Sep.3)		Lunch Coupon (Sep.3)	
Lunch Coupon (Sep.2)		Lunch Coupon (Sep.2)	

제 2장. 국외 활동

- 논문
- 학회 및 전시 발표

1 | 골영희 20년사 발표 (논문, 전시, 공연, 출간)

번호	년도	제목	발표자	학회
	1980	십이지장 악성종양의 방사선학적 고찰	김귀언, 박창윤, 서진석, 임수진.	대한방사선의학회지 1980년 16권 1호 p.125-134
	1981	맹장의 종괴음영과 맹장벽의 부분적 결손상에 대한 방사선학적 고찰	김동익, 박창윤, 서진석, 김귀언	대한방사선의학회지 1981년 17권 2호 p.319-327
논문	1982	Radiologic Manifestation of Typhoid Perforation of Ileum on Plain Abdomen	In Kyu Park, Won Wha Lee, Kyung Jin Suh, Woo Youn Ra, Yong Joo Kim.	Journal of Korean Radiological Society 23(1):206-210
		Tc-99m-HIDA를 이용한 간.담도계 질환의 임상적 연구	서진석 이종두, 유형식, 박창윤, 정태섭, 김기황	대한방사선의학회지 1982년 18권 1호 p.139-148
		임파정체를 동반한 질환의 방사선학적 고찰	정태섭 박찬규, 서진석, 김귀언, 박창윤, 이종두	대한방사선의학회지 1982년 18권 3호 p.510-517
석사 논문	1983	Findings of Simple Chest Radiograph in Clonorchiasis. Master's Thesis. 폐흡충의 단순흉부방사선소견	Kyung Jin Suh	Department of Radiology, Postgraduate School, Kyungpook University
논문		Radiologic Evaluation of Cervical Spine Fractures	Kyung Jin Suh, Chang Bok Rhee, In Kyu Park, Myung Za Lee, Duk Sik Kang	Journal of Korean Radiological Society 1983; 19(4):865-872
	1985	방사성동위원소를 이용한 위장관 출혈의 진단	이길우, 성기준, 박창윤, 유형식, 이종태, 서진석	대한방사선의학회지 1985년 21권 2호 p.246-252
		신결핵의 초음파 소견	서진석, 유형식, 성기준, 이종태	대한 1985년 21권 2호 p.328-333
		결장중복 1예 보고	서진석, 이길우	대한방사선의학회지 1985년 21권 6호 p.999-1003
논문	1986	CT Findings of Malignant Tumors of Maxillary Sinus	Choon Wook Ryu, Tae Hun Kim, Kyung Jin Suh, Yong Joo Kim, Duk Sik Kang	The Kyungpook University Medical Journal 1986; 29(1):62-69
		Buerger병	조휘율, 서진석, 박창윤	대한방사선의학회지 1986년 22권 2호 p.238-244

		관골구 골절의 전산화단층촬영	정호영, 이길우, 서진석, 박창윤	대한방사선의학회지 1986 년 22 권 2 호 p.249-253
		척추결핵의 방사선학적 고찰	이경상, 박창윤, 서진석	대한방사선의학회지 1986 년 22 권 2 호 p.259-266
논문	1987	Percutaneous Transluminal Angioplasty of Ilio-Femoro- Popliteal Artery	Byung Won Jang, Kyung Jin Suh, Tae Hun Kim, In Kyu Park, Yong Joo Kim, Duk Sik Kang	Journal of Korean Radiological Society 1987; 23(1):40-47
논문		Min Chul Shim. Pneumoreduction of Intussusception During Infancy and Childhood	Sik Kang, Min Chul Shim	. Journal of Korean Radiological Society 1987; 23(1):147-153
		동맥류성 골낭종	지 훈, 서진석	대한방사선의학회지 1987 년 23 권 6 호 p.1014-1022
논문	1988	Bronchial Artery Embolization in the Management of Hemoptysis	Jin Chul Kim, Yong Kil Kim, Choon Wook Ryu, Kyung Jin Suh, Tae Hun Kim, Yong Joo Kim, Duk Sik Kang, Tae Hoon Jung	Journal of Korean Radiological Society 1988; 24(2):187-195
논문		Neurofibromatosis with Vertebral Artery A-V Fistula & Cervical Meningocele	Yong Joo Kim, Kyung Jin Suh, Tae Hun Kim, Duk Sik Kang, Yeun Mook Park, June Sik Park	Journal of Korean Radiological Society 1988; 24(3):411-416
논문		. CT-Guided Fine-Needle Biopsy	Young Kil Kim, Tae Hun Kim, Kyung Jin Suh, Yong Joo Kim, In Kyu Park, Duk Sik Kang	Journal of Korean Medical Association 1988; 31(10):1-6
		Low incidence of deep vein thrombosis after cementless total hip replacement	Kim, Y.H., Suh,J.S	J. of Bone and Joint Surg. vol. 70-A:878- 882, 1988
		비이온성 저삼투질농도의 조영제 iopromide(ultravist)의 임상이용과 부작용	이종태, 서진석, 이연희, 서정호	대한방사선의학회지 1988 년 24 권 2 호 p.324-329
		원발성 골종양의 전산화단층촬영에 대한 고찰 : 골반골의 골파괴 병소의 평가에 대한 의의	서진석, 박창윤, 이은주	대한방사선의학회지 1988 년 24 권 4 호 p.648-655

		골육종 : 임상적 측면과 일반 X-선 필름의 유용성	서진석, 박창윤, 김응조	대한방사선의학회지 1988 년 24 권 6 호 p.1107-1113
		만성 고관절증에 있어서 전산화 단층촬영 : 무혈성 골괴사와 퇴행성 관절염의 비교	김명진, 서진석, 이종두, 박창윤	대한방사선의학회지 1988 년 24 권 6 호 p.1114-1121
		Low incidence of deep vein thrombosis after cementless total hip replacement	Kim, Y.H., Suh,J.S.	J. of Bone and Joint Surg. vol. 70-A:878-882, 1988
논문	1989	CT of Extremity Tumorous Conditions	Kyung Jin Suh, Tae Hun Kim, Yong Joo Kim, Duk Sik Kang, Byung Won Jang, Sung Hak Park	Journal of Korean Radiological Society 1989; 25(1):127-133
논문		Ultrasonographic Findings of Thyroid Carcinoma.	Tae Hun Kim, Kyung Jin Suh, Yong Joo Kim, Duk Sik Kang	Journal of Korean Radiological Society 1989; 25(3):387-392
논문		Percutaneous Transhepatic Variceal Obliteration of Intractable Bleeding of Gastroesophageal Varices	Yong Joo Kim, Kyung Jin Suh, Tae Hun Kim, Duk Sik Kang	Journal of Korean Radiological Society 1989; 25(5):672-679
		Teaching slide book of Bone tumors.	Suh, J-S	Book and slides published by Euyoung Slide Press, Seoul Korea, 1989
		골육종 37예의 전산화단층촬영 평가	서진석, 박창윤	대한방사선의학회지 1989 년 25 권 1 호 p.99-105
		3단계 골스캔의 임상적 의의	김선희, 박창윤, 서진석	대한방사선의학회지 1989 년 25 권 2 호 p.305-313
		장골의 표층에 발생한 골육종: 9 예의 방사선학적 검사와 조직학적 검사 소견의 고찰.	서진석, 박창윤, 정순희	대한방사선의학회지 1989년 25권 5호 p.786-792
논문	1990	Percutaneous Transhepatic Biliary Drainage: Analysis of 175 Cases	Kyung Jin Suh, Sang Kwon Lee, Tae Hun Kim, Yong Joo Kim, Duk Sik Kang	Journal of Korean Radiological Society 1990; 26(4):632-639
논문		Radiographic and Histopathologic Changes after Endobronchial Instillation of Various Contrast Agents	Sang Kwon Lee, Tae Ho Kim, Ho Suk Lee, Kyung Jin Suh, Tae Hun Kim, Yong Joo Kim, Jung Sik Kwak,	. Journal of Korean Radiological Society 1990; 26(4):727-734

			Duk Sik Kang	
		천장골 관절의 정량적 골 주사 검사.	서진석, 박창윤, 서정호	대한방사선의학회지 1990년 26권 2호 p.389-394
		후시성 골육종	김명준, 서진석, 박창윤	대한방사선의학회지 1990년 26권 5호 p.940-943
		다발성 골수종 : 45예 -단술 골 촬영과 골주사 소견을 중심으로	양희철, 서진석, 박창윤	대한방사선의학회지 1990년 26권 5호 p.1038-1046
구연		Primitive Neuroectodermal Tumor in Posterior Fossa	Suh KJ, Kim TH, Kim YJ, Kang DS	Korean Radiological Society Scientific Meeting, Seoul, Korea, Apr 28, 1990
전시		CT of Midline Lethal Granuloma	Lee HS, Kim TH, Suh KJ, Kim TH, Kim YJ, Kang DS	Korean Radiological Society Scientific Meeting, Seoul, Korea, Apr 28, 1990
구연		Fibrous Lesions of Bones	Suh KJ, Lee HS, Lee SK, Kim YJ, Kang DS	46th Scientific Assembly and Annual Meeting of the Korean Radiological Society, Seoul, Korea, Oct 26-27, 1990
전시		Ultrasonography of the Neck Mass	Kim TH, Suh KJ, YJ Kim, Kang	46th Scientific Assembly and Annual Meeting of the Korean Radiological Society, Seoul, Korea, Oct 26-27, 1990
	1991	Radiologic case study : Frostbite	Galloway,H.R., Suh,J.S., Parker, S., Griffiths, H.J.	Orthopedics vol. 14: 191-200, 1991
		Radiologic case study: Cuboid subluxation	Everson, L.I., Galloway, H.R., Suh,J-S., Benninghoff,K.S., Griffiths,H.J	Orthopedics vol. 14: 1037-1048, 1991
		Bursitis in association with solitary osteochondromas presenting as mass lesions	Griffiths, H.J., Thompson, R.C., Galloway, H.R., Everson, L.I. and Suh,J-S	Skeletal Radiol. Vol. 20:513-516,1991
논문		Percutaneous Gastrostomy: A	Tae Ho Kim, Ho Suk	Journal of Korean

		Report of Twenty-Seven Cases	Lee, Yong Joo Kim, Tae Hun Kim, Kyung Jin Suh, Duk Sik Kang	Radiological Society 1991; 27(3):377-382
논문		Tomography of Lethal Midline Granuloma	Ho Suk Lee, Tae Ho Kim, Kyung Jin Suh, Tae Hun Kim, Yong Joo Kim, Duk Suk Kang	Journal of Korean Radiological Society 1991; 27(4):513-517
논문		Primitive Neuroectodermal Tumors in the Posterior Fossa: Excluding Medulloblastoma Based on Pathology	Kyung Jin Suh, Tae Hun Kim, Yong Joo Kim, Duk Sik Kang, Sun Young Kim, Youn Kyung Shon	Journal of Korean Radiological Society 1991; 28(1):149-155
논문		Sternocostoclavicular Hyperostosis	Kyung Jin Suh, Yong Joo Kim, Duk Sik Kang, Byung Chul Park	Journal of Korean Radiological Society 1991; 28(3):445-447
논문		Multiple Aneurysms in A Patient with Ehlers-Danlos Syndrome: Angiography with Complication	Kyung Jin Suh	The Kyungpook University Medical Journal 1991: 31(3);278-284
		고해상 CT 를 이용한 특발성 폐섬유화증의 활성도 판정	이진성, 임정기, 한만청, 김주완, 서진석	대한방사선의학회지 1991년 27권 1호 p.55-59
구연		An Intracapsular Osteoid Osteoma on MRI: Misdiagnosed as a Malignant Bone Tumor	Suh KJ, Lee JM, Kim YJ, Kang DS	47th Scientific Assembly and Annual Meeting of the Korean Radiological Society, Seoul, Korea, Oct 25-26, 1991
전시		MR Findings of Neurilemmoma	Kim KB, Lee JM, Sung YS, Suh KJ, Kang DS.	47th Scientific Assembly and Annual Meeting of the Korean Radiological Society, Seoul, Korea, Oct 25-26, 1991
전시		Pulmonary Alveolar Proteinosis.	Sung YS, Suh KJ, Kim TH, Kim YJ, Kang DS.	47th Scientific Assembly and Annual Meeting of the Korean Radiological Society, Seoul, Korea, Oct 25-26, 1991
논문	1992	Bronchial Artery Embolization:	Young Soon Sung,	Journal of the Korean

	Clinical Analysis of 129 Cases	Kyung Jin Suh, Yong Joo Kim	Radiological Society, 1992; 28(4):505-512
박사 논문	Tumor Necrosis Factor-as an Autocrine Growth Factor for Normal Human B-Cells. Ph. D. Thesis. 정상 사람 B 세포에 대한 자가 성장인자로서의 종양괴사인자	Kyung Jin Suh	Department of Immunology, Postgraduate School, School of Medicine, Junpook National University, Junju, Korea, 1992
	Magnetic resonance Imaging in the diagnosis of synovial disease.	<i>Suh, J-S</i> , Griffiths, H.J., Galloway H.R. and Everson L.I	Orthopedics Vol 15: 1-5, 1992
	MRI and Sports injuries	Galloway,H.R., Suh, J-S, Everson, L.I. and Griffiths, H.J	Orthopaedics Vol.15:249-256, 1992
	Magnetic resonance Imaging of the shoulder. Current problems in Diagnostic	Boorstein, J.M., Kneeland J.B., Dalinka, M.K., Iannotti,J.P. and Suh,J-S.	Radiology Vol. 21:1-27, 1992
	Peripheral (extracranial) nerve tumors:Correlation of MR imaging and histologic findings	<i>Suh,J-S</i> , Abenzoza,P., Galloway,H.R.,Everson,L.I., and Griffiths,H.J	Radiology1992; 183:341-346
구연	CT Guided Bone Biopsy: Diagnosis of Spinal Diseases	Suh KJ, Kang DS, Chae JM	48th Scientific Assembly and Annual Meeting of the Korean Radiological Society, Seoul, Korea, Oct 29-31, 1992
구연	CT Scan of the Scaphoid Nonunion	Suh KJ, Kang DS, Kim PT	48th Scientific Assembly and Annual Meeting of the Korean Radiological Society, Seoul, Korea, Oct 29-31, 1992
구연	Carpal Tunnel Syndrome	Suh KJ, Sung YS, Shim JI, Kim WH, Kang DS	48th Scientific Assembly and Annual Meeting of the Korean Radiological Society, Seoul, Korea, Oct 29-31, 1992
전시	Imaging Manifestation of Pleural Masses.	Ryum HK, Kim WH, Kim TW, Park OW,	48th Scientific Assembly and Annual

			Shim JI, Suh KJ, Kim YJ, Kang DS	Meeting of the Korean Radiological Society, Seoul, Korea, Oct 29-31, 1992
		Sequential Tc-99m MDP bone scans after cementless total hip arthroplasty in asymptomatic patients	Kim HS, Suh JS, Han CD, Kim YH, Lee JD	RSNA, 1992
논문	1993	Neurilemmoma of Extremities: MR Findings	Ki Bum Kim, Kyung Jin Suh , Duk Sik Kang	Journal of the Korean Radiological Society 1993; 29(1):39-45
논문		Teleradiology(TELEACE)System: Results of a Field Trial.	Jong Min Lee, Gi Bum Kim, Yeung Soon Seong, Kyung Jin Suh , Duk Sik Kang	Journal of the Korean Radiological Society 1993; 29(2):332-338
논문		MRI Findings of Neurilemmoma of the Extremities: Pathologic Correlation	Choong Gon Choi, Heung Sik Kang, Joo Wan Kim, Kyung Jin Suh , Ho Chul Kim, Chi Sung Song	Journal of the Korean Radiological Society 1993; 29(4):814-819
		장골에서 발생한 거대세포종 : 변연경화 소견의 의의	김희진, 서진석, 박창윤	대한방사선의학회지 1993년 29권 2호 p.307-311
		전립선 선암의 조직학적 분화도와 99mTc-diphosphonate 골 스inti그라피 소견과의 연관성.	이소진, 박창윤, 이종두, 서진석, 함진경, 조남훈	대한방사선의학회지 1993년 29권 6호 p.1356-1360
		The use of MRI in the diagnosis of benign and malignant bone and soft tissue tumors	Griffiths, H.J., Galloway, H.R., Thompson R.C., Suh, J-S., Nelson, T.E., Everson, L.I., Edlin, J.P., Lynn, B.J. and Lang, D	Australas Radiol 1993; 37:35-39
		A computed tomographic analysis of Changes in the spinal canal after lumbar interbody fusion	Kim, N.H., Kim, H.K., Suh, J-S	Clin. Orthop. 286:180-191, 1993
구연		CT Guided Bone Biopsy.	Kyung Jin Suh	Asian-Pacific Congress of Cardiovascular Interventional Radiology. Hilton Hotel, Seoul, Korea, May 27, 1993

전시		Treatment of Arterial Pseudoaneurysm in Extremity by Transcatheter Embolization Using Thrombin	K.H.Cho, S.Y. Kim, B.H. Park	The first Asian-Pacific Congress of Cardiovascular & Interventional Radiology May 24-27, 1993, Seoul Hilton hotel, Seoul, Korea (pp. 177).
Oral presentation		Bone and gallium scans in the evaluation of therapeutic response in bone lymphoma	Moon TY, Kim EE, Legaspi JR, Chung JK, Park JM, Kim YC, Kim BS	The 10th ESMRMB, Rome, Italy, 1993.06.03
전시		MR Imaging of the Carpal Tunnel Syndrome	Kim SW, Kim WH, Yang KS, Suh KJ, Kim YJ, Kang DS	49th Scientific Assembly and Annual Meeting of the Korean Radiological Society, Seoul, Korea, Oct 28-30, 1993
전시		Sequential changes of traumatic vertebral compression fracture on MRI	Mi Sook Sung, Seog H. Park, Kyung S. Shinn	ARRS, 1993, San Francisco, CA
		MR imaging appearance of distal femoral cortical irregularity	Suh JS, Cho JH, Shin KH, Won JH, Park SJ, Shin DH, Kim SJ	RSNA, 1993
presentation		Role of FDG PET in evaluation of therapeutic responses in bone lymphoma	Kim EE, Moon TY	The 79th RSNA, Chicago, USA, 1993.11.30
논문	1994	MR Findings of intravertebral Vacuum cleft	Sung Mun Lee, Soo Jhi Suh, Kyung Jin Suh	Journal of the Korean Radiological Society 1994; 31(1):31-34
논문		Recent Advances in MRI: Clinical Applications	Kyung Jin Suh	Journal of Korean Society of MR Technology 1994; 1:15-21
		Soft tissue hemangiomas: MR manifestations in 23 patients	Suh JS, Whang GJ, Han SB	Skelet Radiol 1994: 621-625
		MR imaging diagnosis of tuberculous spondylitis	Kim NH, Lee HM, Suh JS	Spine 1994;19:2451-2455
구연		Ultrasonography of Achilles Tendon Rupture in Trauma: Value in Decision-Making for Treatment"	K.H.Cho	The 7th Congress of World Federation for Ultrasound in Medicine and Biology (WFUMB), Jul 17-22, 1994,Sapporo,

				Hokkaido, Japan Vol 20, supplement1, pp s193 (구연 번호: No:9-2-4)
pres enta tion		Efficacy of MRI for therapeutic evaluation of bone lymphoma	Moon TY, Kim EE, Kim BS, Lee SH, Kim KI	The 8th JKRC, Yamanashi, Japan 1994.07.23
구연		Os Acromiale: MR Findings and Associated Pathology	Kyung Jin Suh, P.F.J. Tirman, L.S. Steinbach, C.G. Peterfy, H.K. Genant	50th Scientific Assembly and Annual Meeting of the Korean Radiological Society, Seoul, Korea, Oct 20-22, 1994
구연		Monochromatic Computed Tomography of the Calcium and Phosphorus in the Cancellous Bone using Synchrotron Radiation	Suh KJ, Woo H, Kim YJ, Kim TH, Kang DS. Dolbnya IP, Pindyurin VF, Mesentsev NA	50th Scientific Assembly and Annual Meeting of the Korean Radiological Society, Seoul, Korea, Oct 20-22, 1994
구연		Magic-Angle Phenomenon: A Cause of Increased Signal Intensity in the Superior Glenoid Labrum of the Shoulder on Short TE MR Images	Kyung Jin Suh, C.G. Peterfy, P.F.J. Tirman, L.S. Steinbach, H.K. Genant	80th Scientific Assembly and Annual Meeting of the Radiological Society of North America, Chicago, USA, Nov 27-Dec 2, 1994
전시		MR Imaging of Bone Tumors: Monitoring of Response to Chemotherapy Using 3-D Quantification of Tumor Volume: Short-Term Precision	Lang P, Suh KJ , Grampp S, Peterfy CG, Gooding C, Genant HK	80th Scientific Assembly and Annual Meeting of the Radiological Society of North America, Chicago, USA, Nov 27-Dec 2, 1994
전시		MR imaging of cystic lesions around the knee	Mi Sook Sung, Jung I. Yim	RSNA, 1994
전시		Regional bone changes in deep soft tissue hemangiomas	Mi S. Sung, Jung I. Yim	RSNA, 1994 Chicago, IL
		Discoid meniscus of the knee: Bilaterality, morphologic classifications, and types of tear on with MR imaging	Shin MJ, Park CM, Kim JH, Kwon ST	Scientific assembly and annual meeting of RSNA. 1994 (80) SP 1456, Chicago, USA
논문	1995	Variations in the Accessory Structures of the Clavicle: Findings at Chest Radiographs and Dry	Min Suk Chung, Kyung Jin Suh, In Hyuk Chung, Kang	Journal of the Korean Radiological Society 1995; 32(4):597-590

	Bones	Joo	
논문	CT und MRT bei Elastofibrom	Lang PH, Suh KJ, Grampp S, Steinbach L, Steiner E, Peterfy C, Tirman P, Schwickert H, Rosenau W, Genant HK	Radiologe 1995; 35:611-615
구연	Os Acromiale: MR Findings and Associated Pathology	Kyung Jin Suh, P.F.J. Tirman, L.S. Steinbach, C.G. Pterfy, H.K. Genant	European Congress of Radiology, Vienna, Austria, Mar 5-10, 1995
	Imaging of the musculoskeletal system with spiral CT	Vincent M. Bonaldi, Rethy K. Chhem, Laurent Sarazin, Kil-Ho Cho, & Patricia M. Bret	Congress '95 of Canadian Association of Radiologist (CAR). Montreal CANADA, Palais des Congress de Montreal, Jun, 1995 program book of 1995 CAR (p.33)
구연	Osteoid Osteoma: CT Guided Nidus Localization	Kyung Jin Suh, Il Hyung Park	Asian-Pacific Musculoskeletal Tumor Society, Tokyo, Japan, Jun 12-14, 1995
전시	"Utilization of Spiral CT for joint Examination: Preliminary Result with & without intra-articular contrast injection" (in French).	VM Bonaldi, L.Sarazin, RK Chhem, KH Cho, PM Bret.	Congress of French Society of Radiology, Paris, France, Oct. 23-27, 1995.
구연	Shoulder MR Arthrogram with IV Contrast: Application to the Recurrent Shoulder Dislocation	Kyung Jin Suh	1st Annual Meeting of Korean Magnetic Resonance Society. Seoul, Korea, Nov 4, 1995
전시	Cystic masses of the knee: Characteristic US features for the differential	R.K. Chhem, V.M. Bonaldi, L. Sarazin, E. Cardinal, KH Cho	RSNA scientific program. Radiol.(p)supplement: 197:470
구연	<i>Vascularized fibular graft for the treatment of osteonecrosis of the femoral head: radiographs and Tc-99m-MDP bone scan</i>	Mi Sook Sung, Hae Gui Lee, Hyung Min Kim, Kyung Sub Shinn	RSNA, 1995
구연	Acute stage of Whiplash injury: analysis with MR imaging	Seung Eun Jung (resident), Mi Sook	RSNA, 1995

			Sung, Jung Ik Yim, Kyung Sub Shinn	
전시		Acute stage of Whiplash injury: analysis with MR imaging	Mi Sook Sung, Seung Eun Jung, Jung Ik Yim, Kyung Sub Shinn	RSNA, 1995
		Differentiation of hepatocellular carcinoma with bile duct invasion from intrahepatic cholangiocarcinoma: Value of arterial phase dynamic CT with a higher intravenous injection rate of contrast material	Cho JS, Kim DH, Kwon ST, Kim JH, Song. CJ	Scientific assembly and annual meeting of RSNA. 1995 (81) SP 64, Chicago, USA
논문	1996	MR Imaging of Kienbock Disease	Byun KH, Suh KJ, Oh HH, Kim TG, Lee SG, Rheom HK, Kim YJ, Kang DS, Cheong HY	Journal of the Korean Radiological Society 1996; 34(5): 657-662
논문		Osteoid Osteoma: Preoperative CT Guided Nidus Marking	Kyung Jin Suh, Il Hyung Par	Journal of Koran Radiological Society 1996; 35(5):787-792
논문		A Client Expert System for Remote Medical Diagnosis based on OLE/COM	Seok Beom Ko, Sung Jin Choi, IL Kon Kim, Kyung Jin Suh	Journal of Korean Medical Information Society 1996; 2:401- 407
		Hypertrophic and osteosclerotic bone change associated with pustulosis palmaris and plantaris	Suh JS, Shin KH	Skelet Radiol 25;379- 380, 1996
		MR imaging appearance of distla femoral cortical irregularity(cortical desmoid)	Suh JS, Cho JH, Shin KH, Won JH, Park SJ, Shin DH, Kim SJ.	JCAT 20;328-332, 1996
		MR imaging of tuberculous arthritis: clinical and experimental studies	Suh JS, Lee JD, Cho JH, Kim MJ, Han DY, Cho NH.	JMRI 6:185-189, 1996
		Chondromalacia of the knee: evaluation with a fat-suppression three-dimensional SPGR imaging after intravenous contrast injection.	Suh JS, Cho JH, Shin KH, Kim SJ.	JMRI 1996; 6:884-888
구연		MR findings of the lumbar isthmic spondylolisthesis: Differences between involved levels	Kwon ST, HJ Lee, Kim SM, Shin MJ	First International Symposium of Musculoskeletal Magnetic Resonance

			Imaging. January 22-25, 1996, San Francisco, USA
구연	. MR Imaging of Neurotrophic Joint: 23 of Leprotic Ankles	Kyung Jin Suh, Yong Joo Kim, Duk Sik Kang, Sung Hak Park	First International Symposium Musculoskeletal Magnetic Resonance Imaging, San Francisco, USA, Jan 22-25, 1996
구연	MR Imaging of Multiple Neurilemmoma in the Extremity	Kyung Jin Suh, Yong Joo Kim, Duk Sik Kang	First International Symposium Musculoskeletal Magnetic Resonance Imaging. San Francisco, USA, Jan 22-25, 1996
구연	Radiologic Findings After Injection of Methylprednisolone into Simple bone Cyst	Kyung Jin Suh , Kun Woo Kim, Yong Joo Kim, Duk Sik Kang, Il Hyung Park	51st Scientific Assembly and Annual Meeting of the Korean Radiological Society, Seoul, Korea, Apr 26-27, 1996
구연	MR Imaging of tuberculous Arthritis in the Wrist	Kyung Jin Suh, Yong Joo Kim, Duk Sik Kang	51st Scientific Assembly and Annual Meeting of the Korean Radiological Society, Seoul, Korea, Apr 26-27, 1996
전시	MR Imaging of Kienbock's Disease	Kyung Whan Byun, Kyung Jin Suh , Yong Joo Kim, Duk Sik Kang	51st Scientific Assembly and Annual Meeting of the Korean Radiological Society, Seoul, Korea, Apr 26-27, 1996
전시	MR Imaging of the Temporomandibular Joint: Relationship between the Amount of Joint Effusion and the disk Displacement and the Presence of Pain.	Kyung Ho Kim, Kyung Jin Suh , Hyun Whan Oh, Young Sun Kim, Yong Joo Kim, Duk Sik Kang, Jae Gap Choi	51st Scientific Assembly and Annual Meeting of the Korean Radiological Society, Seoul, Korea, Apr 26-27, 1996
구연	Radiologic Findings After Injection of Methylprednisolone Acetate	Kyung Jin Suh, Yong Joo Kim, Duk Sik	American Roentgen Ray Society, San

	into Simple Bone Cyst.	Kang	Diego, USA, May 5-10, 1996
구연	Biceps tendon sheath fluid : Correlation with Arthroscopic Features in 24 Patients	In sup Song	1996년 ARRS
poster	Arterio-venous fistula in the extremity: non-surgical treatment	K-H Cho, BY Seo, KB, Kwon	The 2 nd Congress of the Asian Vascular Society, Jun 2-4, 1996, Seoul, Korea
구연	MR Imaging of Occult Traumatic Knee Dislocations	정선관	ICR abstract 1996.06.09
구연	Osteoid Osteoma: Preoperative CT Guided Nidus Marking for Minimal Bone Resection	Kyung Jin Suh, Yong Joo Kim, Duk Sik Kang	9th Scientific Assembly of the Korean-Japanese Radiological Society, Yongpyung, Korea, June 21-22, 1996
전시	Is Margin-definition in MRI Reliable: A Study with a Wall-Free Phantom.	YS Kim, KJ Suh , DS Kang	European Society of Neuroradiology 22nd Congress. Milan, Italy, September 17-21, 1996
전시	High Resolution MR Imaging of Rabbit Brain with 1.5 Tesla Scanner	YS Kim, KJ Suh , MJ Park, DS Kang	European Society of Neuroradiology 22nd Congress. Milan, Italy, September 17-21, 1996
전시	Brachial Plexus Injury Caused by Dog Bite: A Case Report	박동식, 정선관	American Association of Electrodiagnostic Medicine abstract book 1996.10.03 미국
구연	Vacuum Phenomena in the Spine: Hypersignal Intensity on T1-WI as Susceptibility Artifact	Kyung Jin Suh, Yong Sun Kim	52st Scientific Assembly and Annual Meeting of the Korean Radiological Society, Seoul, Korea, Oct 17-19, 1996
구연	Glenohumeral MR Arthrogram with Intravenous Adminstrated Gd-DTPA: Evaluation of Clinical Utility, and Effect of Exercise time , and Amount of Contrast Media.	Kyung Jin Suh, Yong Sun Kim, Yong Joo Kim, Duk Sik Kang	52st Scientific Assembly and Annual Meeting of the Korean Radiological Society, Seoul, Korea, Oct 17-19, 1996

전시	MR Imaging of the Compressive Neuropathy on Upper Extremity	Suh KJ , Shin HY. Kim YJ, Kang DS	52st Scientific Assembly and Annual Meeting of the Korean Radiological Society, Seoul, Korea, Oct 17-19, 1996
전시	MR Imaging of the Brodie's Abscess in Pediatric Patients	Lee SK, Suh KJ , Cho GH, Lee SM, Kim YJ, Kang DS.	52st Scientific Assembly and Annual Meeting of the Korean Radiological Society, Seoul, Korea, Oct 17-19, 1996
전시	Temporomandibular Joint: Clinical and MR Findings of Hypermobile Joint	Kim YW, Suh KJ , Kim YJ, Kang DS	52st Scientific Assembly and Annual Meeting of the Korean Radiological Society, Seoul, Korea, Oct 17-19, 1996
전시	MR Imaging of the Extraabdomial Fibromatosis	Lee HW, Lee SM, Suh SJ, Cho GH, Suh KJ	52st Scientific Assembly and Annual Meeting of the Korean Radiological Society, Seoul, Korea, Oct 17-19, 1996
전시	Differntiation between Tuberculus and Pyonic Abscess: Utility of MR Imaging in a Patient with Chronic Infectious Arthritis	Park WK, Choi JO, Cho GH, Suh KJ , Lee SK, Whang MS, Park BW	52st Scientific Assembly and Annual Meeting of the Korean Radiological Society, Seoul, Korea, Oct 17-19, 1996
전시	Ultrasonography of Posterior Cruciate Ligament:Normal & Tear	K.H.Cho, B.H.Park, Rethy Chhem	The 6 th Conference of Musculoskeletal Ultrasound Society, Hotel du Parc, Montreal, Canada, Oct, 1996
구연	MR Imaging of Redundant Nerve Roots: Findings and Utility of Sagittal, Axial, Coronal and MR Myelography of the Lumbar Spine	Kyung Jin Suh, Yong Sun Kim, Yong Joo Kim, Duk Sik Kang	96 The Annual Meeting of Korean Society of Magnetic Reonance in Medicine, Seoul Korea, Ritz Calton Hotel, Korea, Nov 16, 1996

구연		Glenohumeral MR Arthrogram with Intravenous Adminstrated Gd-DTPA: Evaluation of Clinical Utility, and Effect of Exercise time , and Amount of Contrast Media	Kyung Jin Suh, Yong Sun Kim, Yong Joo Kim, Duk Sik Kang	82nd Scientific Assembly and Annual Meeting of Radiologic society of North America, Chicago, U.S.A., Dec 1-Dec 6, 1996
exhibit		Synovial plicae: comparison of MR appearance of plica syndrome and normal plicae (scientific exhibit)	Jee WH, Kim HB, Choe BY, et al	82nd Scientific Assembly and Annual Meeting of Radiological Society of North America 1996
		Ischemic necrosis of the entire femoral head	Ryu KN, Kim EJ, Yoo MC, Sartoris DJ, Resnick D	1996 RSNA
		Tuberculous tenosynovitis and bursitis: imaging findings in 21 cases	Jaovisidha S, Chen CK, Ryu KN, Sirwongpairat P, Sartoris DJ, Resnick D	1996 RSNA
구연		Congenital Bilateral Perisylvian Syndrome: MR Imagings and Brain SPECT Findings	정경호, 한영민, 이상용, 김종수, 최기철, 손명희, 김연희, 김형일	American Roentgen Ray Society 미국, Sandiego 1996
exhibit		MR findings of fibrous dysplasia (scientific exhibit)	Jee WH, Jung HS, Park JM, et al	The 96th Annual Meeting of the American Roentgen Ray society San Diego 1996
exhibit		Value of resistive index of the intrascrotal artery in scrotal inflammatory disease (scientific exhibit)	Jee WH, Choi BG, et al	The 96th Annual Meeting of the American Roentgen Ray society San Diego 1996
구연		Cortical dysplasia as a cause of epilepsy : MRI findings	정경호, 한영민, 이상용, 김종수, 최기철, 손명희, 김형일, 이민철	Inaugural congres of asian oceanian epilepsy Seoul, Korea 1996
논문	1997	Redundant Nerve Roots of the Cauda Equina: MR Findings	오규현, 이정만, 정학영, 이영환, 성낙관, 정덕수, 김옥동, 이상권,	대한방사선의학회지 37권 1호 139-144 1997

		서경진	
논문	Transjugular Intrahepatic Portosystemic Shunt in Patients with Active Variceal Bleeding Due to Portal Hypertension and Portal Vein Thrombosis	H.W. Shin,, H.K. Rheum, S.K. Lee, J.M. Lee, Y.S. Kim, K.J. Suh, T.H. Kim, Y.J. Kim	Journal of Koran Radiological Society 1997; 37:597-603
논문	방사선치료실 주변의 선량 측정	서경진, 이정범, 김재철	경북의대지 1997;38(2)161-164
논문	A Relationship between Amount of Joint Effuison, Disk Displacement and Presence of Pain in the Temporomandibular Joint: MR Imaging	KH Kim, KJ Suh, KW Kim, KN Jeon, HH Oh, HK Ryeom, SK Lee, YS Kim, DS Kang JK Choi, YH Lee	Journal of Koran Radiological Society 1997; 36:149-153
논문	Ossified Soft tissue Recurrence of Giant Cell Tumor: Three Case Report	K.J. Jeon, K.J. Suh, S.K. Lee, K.H. Cho	Journal of Koran Radiological Society 1997; 36:887-890
논문	Brodie's Abscess in Pediatric Patients: MR Imaging Findings	S. K Lee, K.J. Suh, H.K. Rheum, Y. S. Kim, K. H. Cho, S. M. Lee, Y. W. Lee, Y.J.Kim,, D.S. Kang	Journal of Koran Radiological Society 1997; 37:153-159
논문	Simple Bone Cyst: Radiologic Changes after Injection of Steroid	K.W. Kim,, K.J. Suh, I.H. Park, H.K. K.H. Kim, K.N. Jeon, Y. S. Kim, S.K. Lee, H.K. Reyom, J.M. Lee, Y.J. Kim, D.S. Kang.	Journal of Koran Radiological Society 1997; 37:515-522
	MR Differential Diagnosis of tuberculous abscess from pyogenic infection in Extremities	K.H.Cho, R.K. Chhem, and B.H.Park	European Radiology 1997;7 , supplement: S-77, No.386
	Tendinous insertion of semi-membranous muscle to lateral meniscus	Kim YC, Yoo WK, Suh JS, Chung IH, Tanaka S	Surg Radiol Anatomay 1997;19:365-369
	. Anatomy and magnetic Resonance imaging of the posterolateral structures of the knee	Kim YC, Chung IH, Yoo WK, Suh JS, Kim SJ, Park CI	Clin Anatomy 1997;10:397-404
	Contrast enhancement pattern and frequency of previously unoperated lumbar discs on MRI	Hwang KJ, Suh JS, Na JB, Lee HM, Kim NH	JMRI 1997;7:575-578
	A Solenoid-like coil producing transverse RF fields for MR imaging.	Jeong EK, Kim Dh, Kim MJ, Lee SH, Suh JS, Kwon YK	J Magn Reson 1997;127:73-79

	Venous malformation: sclerotherapy with a mixture of ethanol and lipiodol.	Suh JS, Shin KH, Na JB, Won JY, Han SB	Cardiovas Intervent Radiol 1997;20: 268-273
	Magnetic resonance imaging of the wrist in defining remission of rheumatoid arthritis	Lee JS, Suh JS, Yoon MJ, Lee SK	J of Rheumatol 1997;24:1304-1308
	MR imaging of male infertility with an endorectal surface coil	Kim MJ, Lee JT, Lee MS, Suh JS, Yoo HS	Abdom Imaging 1997;22: 348-353
	Sequential Tc-99m MDP bone scans after cementless total hip arthroplasty in asymptomatic patients	Kim HS, Suh JS, Han CD, Kim YH, Lee JD	Clin Nucl Med 1997; 22;6-12
전시	MR differential diagnosis of abscess in tuberculous osteomyelitis from pyogenic osteomyelitis in extremities.	KK.Bae, KH Cho, MS Hwang, BH Park	AJR 1997;168(3): 171
전시	Value of ultrasonography in evaluation of the posterior cruciate ligament in the knee	DH Cho, KH Cho, MS Hwang, BH Park	AJR 1997;168(3): 174
전시	Septic Shoulder: US Features	T.Y.Bae, R.K.Chhem, E.Cardinal, K.H.Cho, V.M. Bonaldi	AJR 1997;168(3): 208
구연	Osteoid osteoma: Preoperative CT guided nidus marking	K.J. Suh, I.H. Park, Y.J. Kim, D.S. Kang.	European Congress of Radiology 97, Vienna, Austria, March 2-7, 1997
구연	MR imaging of tuberculous arthritis in the wrist	K.J. Suh, Y. S. Kim, Y.J. Kim, D.S. Kang	European Congress of Radiology 97, Vienna, Austria, March 2-7, 1997
	Non-Surgical Treatment for Arterial Pseudo-aneurysm occurred in Extremities	K-H Cho, BH Park, SM Lee, H Ki	The 3rd Asian-Pacific Congress of Cardiovascular and Interventional Radiology 1997, April 6-11, World congress Center, Melbourne, Australia
구연	Bowel changes after superselective arterial embolization in dogs: the effect embolic materials and levels	한영민, 이상용, 정경호, 손명희, 김중수, 최기철,	Asian Oseanian Vascular interventional Radiology 호주 멜버른 1997
구연	약성 신증양의 색전술시	진공용, 한영민,	Asian Oseanian

	색전물질인 99% 무수에탄올과 99% 무수에탄올/리피오돌 혼합액의 비교	이상용, 정경호, 손명희, 김종수, 최기철	Vascular interventional Radiology 호주 멜버른 1997
구연	Intracortical Fibrous Dysplasia of the tibia in Young Adult Patients	K. J. Suh, I.H. Park, J. M. Chae	The annual Meeting of Korean Radiologic Society. Hyundai Hotel, Kyungju, Korea, April 18-19, 1997
전시	Prominent Epidural Fat in the Lumbar Spine: Evaluation of Imagings and Clinical Findings	J. Y. Kim, K. J. Suh, Y. S. Kim, Y. J. Kim, D.S. Kang	The annual Meeting of Korean Radiologic Society. Hyundai Hotel, Kyungju, Korea, April 18-19, 1997
전시	Signal Alterations in the Bone marrow and Soft Tissue Around the Hip Joint on MRI: Can Differentiate Septic Arthritis from Transient Synovitis?	Y. W. Kim, S.K. Lee, K. J. Suh, Y. J. Kim, D.S. Kang	The annual Meeting of Korean Radiologic Society. Hyundai Hotel, Kyungju, Korea, April 18-19, 1997
전시	Stress Fracture: MR Findings in Long Bone	J. N. Jeon, K. J. Suh, Y. J. Kim, D.S. Kang	The annual Meeting of Korean Radiologic Society. Hyundai Hotel, Kyungju, Korea, April 18-19, 1997
전시	MR Imaging of the glomus tumor of the Finger.	H.Y. Park, K. J. Suh, P. T. Kim, Y. J. Kim, D.S. Kang	The annual Meeting of Korean Radiologic Society. Hyundai Hotel, Kyungju, Korea, April 18-19, 1997
구연	Vacuum Phenomenon in the Spine as Hypersignal Intensity on MR Images	K. J. Suh	2nd International Symposium on Musculoskeletal MRI. San Francisco, California, USA. June 1-5, 1997
	MR Imaging of Glomus Tumor of the Finger	H.W. Shin, K. J. Suh	2nd International Symposium on Musculoskeletal MRI. San Francisco, California, USA. June 1-5, 1997
구연	Intravenous Shoulder MR Arthrogram	Kyung Jin Suh	China-Korea Medical Conference 97. International

			Convention Center, Beijing, China, July 8-10, 1997
전시	Usefulness of Ultrasound-Guided Automated Core Biopsy of Nonpalpable mass	Sang Kwon Lee, Kyung Jin Suh	China-Korea Medical Conference 97. International Convention Center, Beijing, China, July 8-10, 1997
구연	Glenohumeral MR Arthrogram with Intravenously Administered Gd-DTPA	Kyung Jin Suh	The 2nd Intercongress SICOT 97. Grand Hyatt, Seoul, Korea. August 28-31, 1997
전시	MR Imaging of the glomus Tumor of the Finger	Hyun Woon Shin, Kyung Jin Suh	The 2nd Intercongress SICOT 97. Grand Hyatt, Seoul, Korea. August 28-31, 1997
전시	US of PCL of the knee US findings of ischial tuberosity burisits US of bone lesions in extremities	KH Cho	The 4th Simposio Internacional Sobre Ecografia Musculoesequetica) San Sebastian, Spain, Sep 15-19, 1997
전시	US findings of ischial tuberosity bursitis	KH Cho	The 7 th Annual Congress (1997) Musculoskeletal US Society, Genova, Italy
exhibit	Gadolinium-enhancement on fast spin-echo MR imaging: impact on diagnosis of meniscal tears and differentiation of acute & chronic ligament tears (scientific exhibit)	Jee WH, Choe BY, Kim JM, et al	5th International Society of Magnetic Resonance in Medicine 1997
	Signal alterations in the Bone Marrow around the Hip Joints on MR Imaging: Can Differentiate Septic Arthrtis from Transient Synovitis?	Lee SK, Kim YS, Suh KJ, Ryeom HK, Kim YJ, Kang DS	Supplement to Radiology 1997; 205:256. 83rd Scientific Assembly and Annual Meeting of the Radiological Society of North America, Chicago, USA, Nov 30-Dec 5, 1997
전시	A Quantitative Measurement of Fat/Muscle Ratio: New MR	Chang Y, Kim YS, Suh KJ, Kang DS	Supplement to Radiology 1997;

	Imaging Approach		205:617. 83rd Scientific Assembly and Annual Meeting of the Radiological Society of North America, Chicago, USA, Nov 30-Dec 5, 1997
구연 과 전시	Evaluation of arcuate ligament complex injuries of knee with MR imaging	Mi Sook Sung, Hae Gui Lee	CUM LAUDE 수상 RSNA 1997
구연	Evaluation of the anterior cruciate ligament of the knee: comparison between semiflexion truesagittal and extension sagittal oblique positions during MR imaging	Pereira EH, Ryu KN, Ahn JW, Kayser FM, Bielecki D, Resnick D	RSNA 1997
구연	MR imaging diagnosis of discoid meniscal tears	Ryu KN, Kim IS, Ahn JW, Bae DK, Sartoris DJ, Resnick D	RSNA 1997
구연	Non-ossifying fibroma: MR imaging characteristics with radiopathologic correlation	Jee WH, Choe B, Kang HS, Suh K, Suh JS, Ryu KN	RSNA 1997
scien tific pape r	Non-ossifying fibroma: MR Imaging characteristics with radiopathologic correlation	Jee WH, Choe BY, Kang HS, Suh KJ, Suh JS, Ryu KN	83rd Scientific Assembly and Annual Meeting of Radiological Society of North America 1997
exhi bit	Correlation between bone mineral density and skin thickness on CT (scientific exhibit)	Jee WH, Choe BY, Kwon TA, et al.	83rd Scientific Assembly and Annual Meeting of Radiological Society of North America 1997
exhi bit	Evaluation of the effects of high dose radiation on dog thigh muscle by follow-up MR imaging and P-31 MRS (scientific exhibit)	Choe BY, Jee WH, Suh TS, et al	83rd Scientific Assembly and Annual Meeting of Radiological Society of North America 1997
구연	Inverse Relationship of Osteoporosis and Osteoarthritis: Effect of Dengerative disease of	정선관, Peter Kopylay, Jeffrey Carr, Leon Lenchik	미방사선의학회 연례학술대회초록집 1997.11.30

		the Lumbar Spine on Bone Mineral Density		
구연		Focal corticla dysplasia : Correlation of MR findings with pathologic grading	정경호, 이상용, 최기철, 김형일, 한영민, 김중수, 손명희, 이민철	american society of neuroradiology 토론토 1997
		Power versus color Doppler sonography: comparison of diagnostic efficacy in acute pyelonephritis (scientific paper)	Jee WH, Choe BY, Kim SY, et al	The 97th Annual Meeting of the American Roentgen Ray society 1997
exhibit		Gestational trophoblastic neoplasia: efficacy color Doppler sonography (scientific exhibit)	Jee WH, Song SW, Byun JY, et al	The 97th Annual Meeting of the American Roentgen Ray society 1997
논문	1998	Intramedullary fat necrosis of multiple bones associated with pancreatitis. Ahn BC	Lee J, Suh KJ, Chun KA, Sohn SK, Lee KB, Kim CK	Journal of Nuclear Medicine, 1998;39:1401-1404
논문		Nonossifying fibroma: characteristics at MR imaging with pathologic	WH Jee, BY Choe, HS Kang, KJ Suh, JS Suh, KN Ryu, YS Lee, IY Ok, JM Kim, KH Choi, and KS Shinn	correlationRadiology 1998; 209: 197-202
		Ultrasound of Ankle & Foot	KH Cho	Congress of AFSUMB'98 (Asian Federation of Science and Ultrasound in Medicine and biology), Taipei, Taiwan, Oct. 22-27, 1998 J Medical Ultrasound, 1998;6(3):293-294 (supplement)
		Ultrasound of Bone & Bone-Related Diseases	KH Cho	Congress of AFSUMB'98 (Asian Federation of Science and Ultrasound in Medicine and biology), Taipei, Taiwan, Oct. 22-27, 1998 J Medical Ultrasound, 1998;6(3):303-304

			(supplement)
전시	골내 지방종의 자기공명영상 소견	박영찬, 이영환, 성낙관, 정덕수, 김옥동, 서경진, 조길호	대한방사선의학회 제 54차 학술대회 (추계) - 서울 초록집 1998; 111-112
전시	In vivo High Resolution MR Imaging: Extrinsic and Intrinsic Ligaments of the Wrist	서경진, 이성문, 이영환, 조길호, 서수지, 정대철	대한방사선의학회 제 54차 학술대회(추계) 서울 초록집 1998; 385-385
전시	MR Imaging of the Brachial Plexus: Anatomy and Study Techniques	서경진, 이성문, 이영환, 조길호, 서수지, 정대철	대한방사선의학회 제 54차 학술대회 (추계) 서울 초록집 1998; 385-385
	Vascular leiomyoma of an extremity: MR imaging pathologic correlation.	Hwang JW, Ahn JM, Kang HS, Suh JS, Kim SM, Seo JW	AJR 1998;171:981-985
	Minimizing artifacts caused by metallic implants at MR imaging: experimental and clinical studies	Suh JS, Jeong EK, Shin KH, Sho JH, Na JB, Kim DH, Han CD	AJR 1998;171:1207-1213
	MR imaging of Nonossifying fibroma	Ji WH, Suh KJ, Ryu KN, Kang HS, Suh JS et al	Radiology 1998;209:197-202
	Multiple schwannomas	Shin KH, Moon SH, Suh JS, Jahng J-S	Clin Orthop 1998;357:171-175.
Oral presentation	Value of anterior capsular stripping in MRA(magnetic (Oral presentation) resonance arthrography	Ik Yang	the 8th ASIAN & OCEANIAN CONGRESS OF RADIOLOGY(AOCR'98) 1998 . 4 . 5-8. KOBE. JAPAN
전시	Interpretation and Reporting of Dual Energy X-ray Absorptiometry (DEXA) Scans	Leon Lenchik, Seon-Kwan Juhng	1998 ARRS abstract book 1998.04.26 미국
논문	Rober Clarkson."MR study of water exchange and cell membrane permeability in rat liver cells using a tissue-specific MR contrast agent"	Yongmin Chang, Yong Sun Kim, Sang Kwon Lee, Hun Kyu Ryeom, Jong Min Lee, Kyung Jin Suh, Yong Joo Kim, Duk Sik Kang	JKSMRM, vol. 2, pp. 73-82, Jun. 1998
Lecture topic	Ultrasound of normal foot and ankle Ultrasound of foot and ankle	KH Cho	ATL musculoskeletal Ultrasound Education Course, ATL Learning

s	pathology Ultrasound of Elbow pathology		Center, Seattle, Jan 29-31, 1998
Lecture	ATL musculoskeletal Ultrasound Education Course: Ultrasound of Elbow pathology Ultrasound for knee pathology	KH Cho	ATL musculoskeletal Ultrasound Education Course, ATL Learning Center, Seattle, Jun 04-06, 1998
Lecture	Ultrasound of Tumor & Pseudo-tumor of the Hand Ultrasound of Ankle & Foot: normal & pathology	KH Cho	The 8th Annual Congress of Musculoskeletal Ultrasound Society, Sep. 09-12, 1998 Sheraton Seattle Hotel & Tower, Seattle Washington, USA
Lecture	Ultrasound of Normal Ankle & Foot Ultrasound of Bone & Bone-Related diseases	KH Cho	Introduction to Musculoskeletal Ultrasound", Michener Institute, Toronto, Canada, Sep.19-20, 1998
presentations	Subchondral cysts of the humeral head: MR imaging findings	Young Cheol Yoon, Kyung Nam Ryu, Yup Yoon, Yong Gil Rhee	54 th Annual Meeting of Korean Radiological Society, Seoul, Korea, October 15-17, 1998
poster	Clinical usefulness of "extended-field-of view" ultrasonographic imaging in the superficial lesions.	Ik Yang	The 5th Congress of Asian Federation of Societies for Ultrasound in Medicine and Biology(AFSUMB '98), Taipei, Taiwan, 1998.10.24
구연	MR Imaging Evaluation of Thoracolumbar Fractures.	박정미, 원유동	ARRS annual meeting
구연	Cystic Lesions in the Popliteal fossa.	박정미, 김지영	1998 RSNA
구연	Myxoid liposarcoma	박정미,	1998 RSNA
전시	Tuberculous Arthritis versus Rheumatoid Arthritis in Knee Joint.	박정미, 임연수	1998 RSNA
전시	Tibial stress Fx	박정미,	1998 RSNA
구연	Chondroblastoma : MR imaging	Jee WH, Choi KH,	1998 RSNA

전시	characteristics with pathologic correlation	Park YK, Ryu KN, Suh JS, Suh KJ, et al	
구연	Deep infrapatellar bursa : MR imaging study	Kyung Nam Ryu, Yup Yoon	1998 RSNA
구연	Diagnosis of SLAP lesions using MR arthrography of the shoulder	Kyung Nam Ryu, Yup Yoon	1998 RSNA
전시	Avulsion Fractures about the Knee:Review of Clinical Presentations and imaging Findings	정선관,임현수,백형철,고창재,이강모,임형근,원종진	RSNA 초록집 1998.11.29 시카고,미국
Exhibited	Capsular tear of the shoulder: role of MR arthrography	Kwon ST, Kang HS, Rhee KJ, Byun KY, Chung YS, Chun KJ	RSNA. 1998 (84) SE 775MK, Chicago, USA
Exhibited	Acetabular labral tear of the hip: Role of MR arthrography	Chun KJ, Kwon ST, Hwang DS, Chung YS, PaeK CH, Lee WS	Scientific assembly and annual meeting of RSNA. 1998 (SE) 774MK, Chicago, USA
Presented	Acetabular labral tear of the hip: Role of MR arthrography	Chun KJ, Kwon ST, Hwang DS, Chung YS, PaeK CH, Lee WS	Scientific assembly and annual meeting of RSNA. 1998 (SP) 215, Chicago, USA
Exhibited	Chondroblastoma: reactive changes on MR imaging correlated with histopathology	CHUNG HW, Hong SH, Kim J, Lee SH, Yeon KM, Kang HS	84th Scientific Assembly and Annual Meeting of RSNA, 1998, Chicago
Presented	Indirect Sign of ACL Injury on SPECT: Comparison with MRI and Arthroscopy	CHUNG HW, YH Kim, Hong SH, Kim SS, Chung KY, Seong SC, Kang HS	84th Scientific Assembly and Annual Meeting of RSNA, 1998, Chicago
scientific paper	Chondroblastoma: MR imaging characteristics with pathologic correlation	Jee WH, Choi KH, Park YK, et al	84th Scientific Assembly and Annual Meeting of Radiological Society of North America 1998
scientific paper	Plain radiographs versus MR imaging: comparison of prognostic efficacy in Legg-Calve-Perthes disease based on two-year follow-up evaluation	Jee WH, Lee YJ, Choi KH, et al	84th Scientific Assembly and Annual Meeting of Radiological Society of North America 1998
exhibit	MR distinction between multiple myeloma and metastasis involving the spine	Lee YJ, Jee WH, Choi KH, et al	84th Scientific Assembly and Annual Meeting of

				Radiological Society of North America 1998
scientific paper		Benign versus malignant vertebral compression fractures: distinction with fast spin-echo MR imaging with Gadolinium-enhancement	Jee WH, Lee BY, Choe BY, et al	98th Annual Meeting of the American Roentgen Ray Society 1998
구연		MR Imaging of Repair Process following Periosteal Autograft for Canine Articular Cartilage Defects	Mi Sook Sung, Chang H Jung, Young S Kim	RSNA 1998
전시		Myxoid Liposarcomas: Enhance MR images with Histologic Correlation	Mi Sook Sung, Heong S. Kang, Jin S. Suh, Jeong H Lee, Jung M Park, Jee Y Kim, Hae G Lee	RSNA, 1998
전시		MR imaging of Bursitis around the Hip	Kyung J Lee (resident), Mi S. Sung, Won Jong Yu, Hae G Lee	RSNA, 1998
논문	1999	Septic arthritis versus transient synovitis at MR imaging: preliminary assessment with signal intensity alterations in bone marrow	Sang Kwon Lee, Kyung Jin Suh, Yong Woon Kim, Hun Kyu Ryeom, Yong Sun Kim, Jong Min Lee, Yongmin Chang, Yong Joo Kim, Duk Sik Kang	Radiology, vol. 211, pp. 459-465, May 1999
		Variation of meniscofemoral ligaments at anatomy and MR imaging	Cho JM, Suh JS, Na JB, Cho JH, Kim YC, Yoo WK, Lee HY, Chung IH	Skelet Radiol 1999;28:189-195
		Correlation of laminated MR appearance of articular cartilage with histology; ascertained with artificial landmarks on the cartilage	Kim DJ, Suh JS, Jeong EK, Shin KH, Yang WI	JMRI 1999;10:57-64
		Role of inflamed synovial volume of the wrist in defining remission of rheumatoid arthritis with gadolinium-enhanced 3D-SPGR MR imaging	Huh YM, Suh JS, Jeong EK, Lee SK, Lee JS, Choi BW, Kim DK	JMRI 1999;10:202-208.
		Chondroblastoma: MR characteristics with pathologic correlation	Jee W-H, Park Y-K, McCauley TR, Choi K-H, Ryu K-N, Suh	J CAT 1999;23:721-726

		JS, Suh KJ, Cho JH, Lee JH, Park JM, Lee YS, Ok IY, Kim JM	
	Arm pain in a 24-year-old woman(subacute osteomyelitis).	Shin KH, Shin SJ, Suh JS, Yang WI.	Clin Orthop. 1999;361:245-249; 261-263
	Treatment of tuberculosis of the Sacroiliac joint.	Kim NH, Lee HM, Yoo JD, Suh JS	Clin Orthop 1999;358:215-222
구연	Avascular necrosis of the hip in patients with aplastic anemia.		European Society of MusculSkeletal Radiology
	Bone metastases of the extremities : evaluation with MR imaging	천경아,박정미,성미숙,김지영,지원희,김현숙,이연수,김의녕,김영주,박석희	ECR 19990301 Vienna
전시	Bone metastases of extremities :evaluation with MR imaging.		ECR 19990301
oral presentations	Evaluation of CT air bronchogram sign in malignant solitary pulmonary lesions	<u>Choi JA</u> , Kim HS, Oh YW, Kang EY	11 th European Congress of Radiology Meeting, 3.7.-3.12. 1999. Vienna, Austria.
oral presentations	Square index of liver segment: follow-up in liver cirrhosis	Hong KT, <u>Choi JA</u> , Kim CJ, Park CM, Cha IH	11 th European Congress of Radiology Meeting, 3.7.-3.12. 1999. Vienna, Austria.
Student & Resident lecture	Imaging of Osteogenic tumor Imaging of Infectious bone diseases	KH Cho	University of Saskatchewan, Saskatoon, CANADA, 1999. 04.10-11
lecture	TNT course (Training New Trainers) in musculoskeletal ultrasound (Ultrasound of Elbow Pathology Ultrasound of Elbow Pathology Ultrasound of Ankle Pathology)	KH Cho	University of Saskatchewan, Saskatoon, CANADA, Apr.10-16. 1999
lecture	Ultrasound of rotator cuffs in the shoulder ultrasound of bursae: Shoulder, elbow, hip & Knee	KH Cho	ASDIR (Asian-Oceanian Seminars on Diagnostic & Interventional

			Radiology), Singapore, Apr.16-18, 1999
lecture	Ultrasound of bone & bone-Related diseases Ultrasound of common pathology of the hand & wrist	KH Cho	The 9 th Congress of Musculoskeletal Ultrasound Society Sep. 24-28, 1999 Hotel Crowne Plaza Panamericano, Buenos Aires, Argentina.
구연	Parosteal osteosarcoma of the scapula	Park YK, Ryu KN	ISS 1999
전시	Chondromalacia of the knee ; Sagittal, Gd-enhanced, fat-suppression 3D SPGR imaging	김성준, 서진석, 이상훈, 조재민	ISMRM, 1999
Oral presentation	Tibial stress fracture induced by flexor digitorum longus muscle activity	Moon TY, Jung HW, Park CH.	6th ESSR, Edinburgh Scotland, (1999.10.09)
presentations	A study to assess by means of MR arthrography the causal relationship between anterior capsular attachment type and anterior instability of the glenohumeral joint	<u>Young Cheol Yoon,</u> Kyung Nam Ryu, Yup Yoon, Yong Gil Rhee	55 th Annual Meeting of Korean Radiological Society, Seoul, October 21-23, 1999
	Imaging of Dermatofibrosarcoma Protuberans with Pathologic correlation	김성문, 신명진, 안중모, 성미숙, 천경아, 정동해	85th annual meeting, Radiological society of North 19991101 Chicago, USA
구연	MR Evaluation of Rotator Cuff Tears : Comparison of Turbo Spin-Echo STIR and Fat-Suppressed Turbo Spin-Echo T2-weighted Images	천경아, 안보영, 김영주, 김기태	85th annual meeting, Radiological society of North 19991101 Chicago, USA
전시	Peroneal nerve palsy: MR imaging findings	J. Kim, S. Kim, YH Park, M Sung, KH Cho	: 1999년 RSNA annual meeting Supplement to radiology 1999;213: p. 541
전시	Ischial bursitis: Ultrasonography, CT, and MR features	SM Kim, KS Kim, MJ Shin, J Ahn, KH Cho, J. Chang	1999년 RSNA annual meeting Supplement to radiology 1999;213: p. 543
post	CT manifestations of variable late	<u>Choi JA,</u> Hong KT,	85 th Scientific

er/exhibit	sequelae of tuberculous pleurisy	Kim J, Oh Y, Kang E	Assembly and Annual Meeting of Radiological Society of North America. 11.28-12.3.1999, Chicago, IL, USA
Exhibits	Experimentally induced pyogenic arthritis of rabbit knees: comparative study of MR imaging and pathology.	Hong SH, Koh SH, Chung HW, Lee KW, Kim JJ, Kang HS	. RSNA 1999
Exhibits	Experimentally induced acute osteomyelitis in rabbit: comparative study of sonography and histopathology	Cheon JE, Kang HS, Chung HW, Hong SH, Kim JJ	. RSNA 1999
Exhibits	MR imaging of multiple myeloma: emphasis on extraosseous involvement	Moon SG, Hong SH, Kang HS, Ahn JM, Kim SM, Shin MJ	RSNA 1999
전시	Diagnosis of meniscocapsular separation: MR imaging criteria and diagnostic pitfalls	De Maeseneer M, Lenchik L, Ryu KN, Roy VF, Osteaux MJ	RSNA 1999
전시	Radiologic findings of musculoskeletal sparganosis	Cho J, Suh J, Kim B, Lee K, Ryu KN, Park J	RSNA 1999
전시	Spectrum of the Epidermoid cyst	Mi Sook Sung, Hyun Wook Im, Won Jong Woo, Hae Giu Lee	RSNA1999
전시	Radiologic Evaluation of pathologic lesions involving the mandible and maxilla: histopathologic correlation	최시성,민병철,정선관,원종진	북미방사선학회 초록집 시카고,미국 1999.11.28
전시	CT Evaluation of Deep Venous Thrombosis in lower limb	노병석,김은아,윤권하,최시성,정선관,원종진	북미방사선학회 초록집 시카고,미국 1999.11.28
포스터	Patterns of Disc Enhancement in Tuberculosis and Pyogenic Spondylitis: Is there Any Difference?	이상용	북미방사선학회(RSNA) 미국, 시카고 1999
구연	Fluoroscopi-Guided Metallic Stent Placement for the Palliative Treatment of Malignant Gastric	김종수, 이정민, 한영민, 이상용, 정경호, 신영열,	American Roentgen Ray Society New Orleans, LA 1999
구연	Randomized Trial Comparing Transarterial Oily Chemoembolization and Transarterial Gelfoam	김종수, 이정민, 한영민, 이상용, 정경호,	American Roentgen Ray Society New Orleans, LA 1999

		Embolization in Spontaneous Rupture of Hepatocellular Carcinoma		
		Meniscal tear patterns: categorization with fast spin-echo MR imaging (scientific paper)	Jee WH, Jun DJ, Kim JM, Lee YJ, Choi BG, Choi KH	99th Annual Meeting of the American Roentgen Ray Society 1999
		Osteonecrosis in patients with systemic lupus erythematosus: MR imaging and scintigraphic evaluation (scientific paper)	Jee WH, Jun DJ, Cho SM, Kim SH, Kang HS, Ryu KN, Cho CS, Chung SK, Choi KH	99th Annual Meeting of the American Roentgen Ray Society 1999
논문	2000	Alveolar soft part sarcoma: MR and angiographic findings	in-Suck Suh, Jaemin Cho, Sang Hoon Lee, Kyoo-Ho Shin, Woo Ick Yang, Jeong Hoon Lee, Jae-Hyun Cho, Kyung Jin Suh, Young Joon Lee, Kyung Nam Ryu	Skeletal Radiol 2000; 29:680-689
		Different patterns of photopenia of the femoral head on bone scan using Tc-99m MDP with acute irritable hip in the preschool children: Comparison with MR findings	Ryu YH, Lee JD, Yoon CS, Jeon TJ, Park HW, Suh JS	JOURNAL OF NUCLEAR MEDICINE A 41 (5): 384 Suppl. S MAY 2000
구연		Bone bruises:MR characteristics and histological correlation in the young pig	Ryu KN	ECR 2000
		Patellar metastasis from a squamous cell carcinoma of the larynx	<u>Choi</u> YS, Yoon YK, Kwak HY, Song IS	AJR Am J Roentgenol 2000;174:1794-1795
논문		High signal intensity on T1-weighted MR image related to vacuum cleft in the intravertebral disk: clinical and phantom study	Tae Gyun Chung, Yong Sun Kim, Yongmin Chang, Sang Kwon Lee, Young Hwan Kim, Hun Kyu Ryeom, Jong Min Lee, Chang Hyon Lee, Tae Hun Kim, Kyung Jin Suh	J Korean Radiol Soc, vol. 43, pp. 651-656, Dec. 2000

	Subcutaneous and musculoskeletal sparganosis: imaging characteristics and pathologic correlation	Cho J-H, Lee K-B, Yong T-S, Kim B-S, Park H-B, Ryu K-N, Park J-M, Lee S-Y, Suh J-S	Skeletal Radiol 2000;29:402-408
	Alveolar soft part sarcoma: MR and angiographic findings	Suh JS, Cho JM, Lee SH, Shin KH, Yang WI, Lee JH, Cho JH, Suh KJ, Lee YJ, Ryu KN.	Skeletal Radiol 2000;29:680-689
	Myxoid liposarcoma: appearance at MR imaging with histologic correlation	Sung MS, Kang HS, Suh JS, Lee JH, Park JM, Kim JY, Lee HG	Radiographics 2000;20:1007-1019.
	Tumor volume change as a predictor of chemotherapeutic response in osteosarcoma.	Shin KH, Moon SH, Suh JS, Yang WI	Clin Orthop 2000;376:200-208
	Growing mass on the medial aspect of the right proximal leg.	Park HJ, Shin KH, Yang WI, Suh JS	Clin Orthop 2000;380:279
oral presentations	The efficacy of abduction and external rotation of the shoulder in MR arthrography in revealing tears of the anterior glenoid labrum	Choi JA, Kim MG, Kim B, Cha S	12 th European Congress of Radiology Meeting, 3.5.-3.10. 2000. Vienna, Austria.
oral presentations	Preoperative evaluation of gastric cancer: Value of CT during gastric arteriography (CTGA)	Kim HS, Choi JC, Choi JA, Park CM, Cha IH	12 th European Congress of Radiology Meeting, 3.5.-3.10. 2000. Vienna, Austria
전시	injury patterns of the extensor mechanism of the knee: MR imaging		유럽방사선의학회 오스트리아 2000.03.05 유럽방사선의학회 초록집
구연	Evaluation of marrow status and vascularity in the proximal femoral metaphysis and diaphysis	박정미	European Society of MusculSkeletal Radiology
Presented	Adhesive capsulitis of the shoulder: MR arthrography	TI Han, HJ Kim, KW Lee, ST Kwon	. European Radiology Association & Congress 2000 (SP) 1124, Vienna, Austria
presentations	MR findings of lumbar epidural varix	Kyung Nam Ryu, Young Cheol Yoon, Woo Suk Choi	56 th Annual Meeting of Korean Radiological Society, Kyungju, Korea, April 21-22, 2000

구연	MR Imaging appearance of meniscocapsular separations of the medial meniscus	정선관,이강모,원종진	Korea-Janpan Radiology Congress abstract book 2000.06.09
lecture	Ultrasound of bursal pathology Ultrasound of bone & bone-Related lesions	KH Cho	The 10 th Congress of Musculoskeletal Ultrasound Orchard Hotel Singapore, Singapore Society Jul. 12-16, 2000
lecture	Ultrasound of the ankle	KH Cho	Pakistan, Burwin Institute of Ultrasound in Canada, Asian branch one day seminar, Lahor ,Pakistan Nov-19, 2000
구연	Sacrococcygeal Chordoma: MR Imaging in 30 Patients	Mi Sook Sung, Hae Gui Lee	ISS 2000
	Diagnosis of dental cavity and osteoporosis using terahertz transmission images	Jaeyoung Ryu, Yuchul Jung, Seungyong Baek, Jongjoo Lee, Sora Kim, Joungho Kim, Kwon ST	International Conference on Ultrafast Phenomena 2000, USA
Exhibition	Superior labrum anterior posterior lesions: diagnostic value and pitfalls of MR arthrography	Young Cheol Yoon, Kyung Nam Ryu	The 86 th Scientific Assembly and Annual Meeting, Radiological Society of North America, McCormick Place, Chicago, Illinois, November 26-December 01, 2000
Exhibition	Anterior labral tear of the shoulder: evaluation with MR arthrography and correlation with arthroscopy	Young Cheol Yoon, Kyung Nam Ryu	The 86 th Scientific Assembly and Annual Meeting, Radiological Society of North America, McCormick Place, Chicago, Illinois, November 26-December 01, 2000
Exhibition	Soft tissues masses: Sonographic imaging findings.	Kyung Nam Ryu, Young Cheol Yoon	The 86 th Scientific Assembly and Annual Meeting, Radiological

			Society of North America, McCormick Place, Chicago, Illinois, November 26-December 01, 2000
	Superior Labral anterior posterior (SLAP) lesions of the glenoid labrum: reliability and accuracy of diagnosis with MR arthrography (scientific paper)	Jee WH, McCauley TR, Katz LD, Matheny JM, Ruwe PA, Daigneault JP	86th Scientific Assembly and Annual Meeting of Radiological Society of North America 2000
	MR diagnosis of meniscal tears in patients with acute anterior cruciate ligament tears (scientific paper)	Jee WH, McCauley TR, Kim JM, Choi KH	86th Scientific Assembly and Annual Meeting of Radiological Society of North America 2000
	Grade 2C signal of the meniscus at MR imaging: clinical significance (scientific poster)	Jee WH, McCauley TR, Galloway MT, Lynch K, Jokl P	86th Scientific Assembly and Annual Meeting of Radiological Society of North America 2000
	Sacroiliitis in patients with ankylosing spondylitis: association of MR findings with disease activity (scientific poster)	Jee WH, McCauley TR, Lee SH, Choi KH	86th Scientific Assembly and Annual Meeting of Radiological Society of North America 2000
	MR findings of myositis and myositis-Mimicking disease	김지영,천경아,박영하,김원영	86th Scientific Assembly and Annual Meeting of Radiological Society of North America 2000
전시	MR Imaging of Extensor Mechanism Injuries of the Knee	정선관,윤권하,최시성,노병석,김창근,원종진	RSNA Scietific Assembly and annual meeting program 2000.11.26
구연	Chondrocalcinosis in the pelvis in an elderly male population:degenerative etiology and data indicating much higher prevalence than	Feng SA, Chung CB, Bielecki DK, Ryu KN, Resnick D	RSNA 2000

		previously recorded		
전시		Experimetal muscular injury in rabbit: correlation between sonographic imaging findings and histopathologic features	Ryu KN, Kim HJ, Sung DW	RSNA 2000
전시		The Usefulness of T2-weighted Oblique Coronal MR Imaging in the Differential Diagnosis between Complete and Partial Anterior Cruciate Ligament Tears	Jae-Chan Shim, Ghi Jai Lee, Ho Kyun Kim	RSNA 2000년
구연		Comparison of Current Contrast-enhanced MR Imaging and Combined CTAP and Biphasic CTHA for the Preoperative Evaluation of Hepatocellular~	이정민, 이상용, 김중수, 곽효성,	Radiological Society of North America 미국, 시카고 2000
구연		Ankle Ligaments:Comparison of MR Arthrography with Conventional MR Imaging in Amputated Feet	이상용, 김중수, 유재성,	Radiological Society of North America 미국, 시카고 2000
구연		Medial Ankle Ligaments and Spring Ligament:13 MHz High-Frequency Sonography in Amputated Feet	이상용, 한영민, 김인환	Radiological Society of North America 미국, 시카고 2000
	2001	Magnetic resonance imaging of articular cartilage	<i>Suh J-S</i> , Lee SH, Jeong E-K, Kim D-J	Eur. Radiol 2001;11:2015-2025.
		Evaluation of chondromalacia of the patella with axial inversion recovery-fast spin echo imaging	Lee SH, <i>Suh JS</i> , Cho JM, Kim SJ, Kim SJ	JMRI 2001; 13:412-416.
		Calcified subcutaneous fat necrosis induced by prolonged exposure to cold weather: a case report	Lee SK, Lee JH, Han CH, Ahn YM, <u>Choi YS</u> , Kim IO	Pediatr Radiol 2001;31:294-295
		Intra-articular ganglion cysts of the knee: clinical and MR Imaging features	Kim MG, Kim BH, Choi JA, Lee NJ, Chung KB, <u>Choi YS</u> , Cho SB, Lim HC	Eur Radiol 2001;11:834-840
구연		MR appearances of tuberculous spondylitis with treatment	박정미,천경아 .	European Society of MusculSkeletal Radiology
		Trancatheter Fluoroscopy-Guided Sclerotherapy for Treatment of Greater Saphenous Vein reflux		The 2nd Korea-Japan Joint Meeting for Vascular Surgery 2001.07.20
Exhi		Dynamic US of the snapping iliotibial	<u>Yun Sun Choi</u> , Baek	IPR 2001 Scientific

bitio n	band	Young Song, Sang Hyun Paik, Sook Ja Yoon, Yong Kyu Yoon	Exhibition
구연	osteosarcoma of the foot	Park YK, Ryu KN	ISS 2001 ,09
강의	Ultrasound of the bone and bone-related diseases Ultrasound of the bursa I & II.	KH Cho	The 11 th Congress of Musculoskeletal Ultrasound Society Oct. 07-11, 2001 Omni Shoreham hotel, Washington D.C., USA
	MR imaging of the central insertions of the menisci: normal and pathologic findings in cadaveric and clinical study.	Kwon ST, Kim JY, Park JG, Chung CB, Cho JH, Resnick DL	87th Scientific assembly and annual meeting of RSNA. 2001 (EE) 0304, Chicago, USA
Pres ente d	MR imaging features in 12 patients with chronic subacromial/subdeltoid bursitis with rice bodies: rheumatoid arthritis and tuberculosis with emphasis on differentiation features	Chanchairujira K, Chung CB , Kwon ST, Chiewvit P, Asavamongkolkul A, Resnick DL	87th Scientific assembly and annual meeting of RSNA. 2001 (SP) 1205, Chicago, USA
Pres ente d	Central insertions of the knee: MR appearance and features allowing differentiation from Bucket-Handle tears-clinical and cadaveric study	JY Kim, ST Kwon , JH Cho, CB Chung, DL Resnick	87th Scientific assembly and annual meeting of RSNA. 2001 (SP) 261, Chicago, USA
exhi bit	Benign peripheral nerve sheath tumors: discrimination of neurofibroma from neurilemoma with MR imaging	Oh SN, Jee WH, McCauley TR, Ryu KN, Suh JS, Lee JH, Park JM, Chun KA, Sung MS, Kim KJ, Choi KH	87th Scientific Assembly and Annual Meeting of Radiological Society of North America 2001
exhi bit	Compression fractures of the spine: discrimination of metastatic from acute osteoporotic fractures with fast spin-echo MR imaging	Jung HS, Jee WH, McCauley TR, Ha KY, Choi KH	87th Scientific Assembly and Annual Meeting of Radiological Society of North America 2001
구연	Diagnostic Value of MR Imaging in Differentiation of Cervical Disk Herniation from Osteophytes	천경아	RNSA 87th Scientific Assembly and Annual Meeting
	Benign peripheral nerve sheath	Oh SN, Jee WH,	RSNA 2001

	tumors:discrimination of neurofibroma from neurilemoma with MR imaging	McCauley T, Ryu KN, Lee J, Choi K et al	
전시	Imaging findings of congenital anomalies of the spine	Ryu KN, Ryu JK	RSNA 2001
구연	Differential diagnosis of superior labrum anterior-posterior(SLAP) lesion type II from superior sublabral recess by MR arthrography	Kwon SH, Ryu KN	RSNA 2001
구연	Kissing contusion between posterolateral tibial plateau and lateral femoral condyle: associated injuries	Hong HP, Ryu KN	RSNA 2001
	Pulse-Inversion Harmonic US with Microbubble Contrast Agent: Contrast enhancement Pattern Analysis for Characterization of Hepatocellular Carcinoma, Metastasis and Hemangioma	K Yoon, E.A.Kim, S.H Park, K.Park, S.Juhng, J.Won	RSNA 2001 RSNA 초록 Chicago, Illinois
전시	Compound Sonographic Imaging: Comparision of Fundamental, Tissue Harmonic, and Pulse Inversion Harmonic Imaging	E.A.Kim, K.Yoon, S.H.Park, S.Juhng, J.Won	RSNA 초록
전시	Chest wall Disease:Review of Radiologic Features	S.Juhng, J.Roh, K.Lee, S.Choi, J.Won	RSNA 초록
	Multipaner Reformation Images with Multidetector-Row CT in the Biliary Tract and Pancreatic Disease	K.Yoon, E.A.Kim, S.H.Park, Y.Kim, S.Juhng, J.Won	RSNA 초록
구연	The Usefulness of T2-weighted Oblique Coronal MR Imaging in the Differential Diagnosis between Complete and Partial Anterior Cruciate Ligament Tears	Shim Jae-Chan, Lee Ghi Jai, Ryu Seok Jong, Bang Sun Woo, Kim Ho Kyun	ARRS 2001년
Lecture topic	Musculoskeletal ultrasound as a problem-solving	KH Cho	The 2 nd annual one-day international seminar on ultrasound Burwin institute of Ultrasound Canada-Asian branch.Pearl continental hotel, Lahore, Pakistan, Dec. 30, 2001

	2002	Feasibility of ultrasound examination in posterior ligament complex injury of thoracolumbar spine fracture	Moon S-H, Park M-S, Suk K-S, Suh J-S, Lee S-H, Kim N-H, Lee H-M.	Spine 2002;27:2154-2158
		Dynamic sonography of external snapping hip syndrome	Choi YS, Lee SM, Song BY, Paik SH, Yoon YK	J Ultrasound Med 2002;21:753-758
교육		Musculoskeletal ultrasound	KH Cho	Musculoskeletal ultrasound: practical training workshop, Lahore, Pakistan (organized by The Burwin Institute of Ultrasound CANADA – Asian-Oceanian Branch) Jan. 1-3, 2002
Lecture		Basic principles and indications: musculoskeletal ultrasound MRI & ultrasound of the shoulder: normal and pathological appearance	KH Cho	International Radiological Conference in Pakistan. Marriott Karachi Hotel, Karachi, Pakistan Jan. 4-5-2002
구연		Avascular necrosis of hip following bone marrow transplantation: MR appearance	박정미, 박창숙, 한성태	European Society of Musculoskeletal Radiology
전시		Strategy for assessment of tumor and tumor-like lesions around joints	Mi-Sook Sung, Hae G Lee	European Congress of Radiology, Vienna, 2002.03
		Diagnostic Accuracy of multislice CT angiography in detection of intracranial aneurysms: comparison with conventional angiography	최시성, 정선관, 원종진	AJNR 40th Annual Meeting 2002.05.20 AJNR 40th Annual Meeting 초록
Lecture		US of normal knee US of the posterior cruciate ligament of the knee	KH Cho	Kurs i ultralyddiagnostikk ved lidelser i muskelog skjelettapparatet. Norsk Idrettsmedisinsk Institutt (NIMI), 노르웨이

			스포츠의학회 주관, Ullevål Stadion, Oslo Norway, May, 31- Jun 1, 2002
pres enta tion	Radiographic features of skeletal small round cell tumours	Moon TY	The 4th AMS, Yogyakarta, Indonesia (2002.06.01)
	Pitfalls encountered in MR imaging of patients with brain tumors:review article	최시성, 정선관, 원종진	AJNR 40th Annual Meeting 2002.06.21
구연	Ultra sonographic findings in shoulder involvement in rheumatoid arthritis	천경아	12th annual conference on musculoskeletal ultrasou 20020801 bruxelles
Exhi bited	Ultrasonographic appearance of desmoid tumor: A case of a 17 year-old boy with MR and histopathologic correlation	CHUNG HW, Kang HS, Kim JE, Oh JH	12th Annual Conference on Musculoskeletal Ultrasound, 2002, Brussels
Lect ure	Ultrasound of bursae Ultrasound of the bone	KH Cho	The 12 th Annual congress of Musculoskeletal Ultrasound Society, Brussels, Belgium, Sep 2002
구연	Osteosarcoma in the maxillary sinus	Park YK, Ryu KN	ISS 2002.09
exhi bit	Can we determine T2 signal of musculoskeletal tumorous conditions on fat-suppressed fast spin-echo MR imaging	Hwangbo S, Jee WH, Kim SU, Lee YS, Choi KH	101st Annual Meeting of the American Roentgen Ray Society 2002
exhi bit	Aneurysmal bone cysts: MR findings according to radiologic evolutional phases	Hwangbo S, Jee WH, Kim SU, Ryu KN, Suh JS, Lee JH, Park JM, Chun KA, Sung MS, Choi KH	101st Annual Meeting of the American Roentgen Ray Society 2002
Lect ure	Elbow ultrasound Ultrasound of soft tissue masses	KH Cho	The first Asian Musculoskeletal Ultrasound course in Singapore. National University of Singapore, Nov-9-10, 2002

Prese ntati on	MR imaging findings of painful type II accessory navicular bone requiring surgical treatment: correlation with surgical and pathologic studies	<u>Yun Sun Choi</u> , Kyung-tae Lee, Heung Sik Kang, Yong Kyu Yoon	RSNA 2002 Scientific Presentation
Exhi bitio n	Dynamic ultrasound of the external snapping hip syndrome.	<u>Yun Sun Choi</u> , Sung Moon Lee, Baek Young Song, Yong Kyu Yoon	RSNA 2002 Scientific Exhibition
oral pres enta tions	MRI of ACL reconstruction with quadriceps tendon graft: a prospective study with focus on T2 signal intensity and contrast enhancement	<u>Choi JA</u> , Kim JE, Lee MC, Lee SH, Kang HS	88 th Scientific Assembly and Annual Meeting of Radiological Society of North America. 12.1-12.6.2002, Chicago, IL, USA
oral pres enta tions	Posterior epidural fat on sagittal MR images: Can it help distinguishing between isthmic and degenerative spondylolisthesis?	<u>Choi JA</u> , Kim JE, Myung J, Oh K, Kang HS	88 th Scientific Assembly and Annual Meeting of Radiological Society of North America. 12.1-12.6.2002, Chicago, IL, USA
oral pres enta tions	Malignant melanoma: Is there a difference in signal intensity between extremity and head and neck?	Son K, <u>Choi JA</u> , Kim JE, Jung H, Kim J, Kang HS	88 th Scientific Assembly and Annual Meeting of Radiological Society of North America. 12.1-12.6.2002, Chicago, IL, USA
scien tific pape r	Ankle ligament tears: diagnostic accuracy of MR imaging	Jee WH, Jung NY, Chu IT, Kim SU, Byun JY	88 th Scientific Assembly and Annual Meeting of Radiological Society of North America 2002
scien tific pape r	MR Imaging features of chondromyxoid fibroma	Cho SH, Jee WH, Cho HK, Ryu KN, Suh JS, Cho JH	88 th Scientific Assembly and Annual Meeting of Radiological Society of North America 2002

scientific paper, corresponding author		Discrimination of tuberculous spondylitis from pyogenic spondylitis with MR imaging	Jung NY, Jee WH, Ha KY, Park CK, Byun JY	88th Scientific Assembly and Annual Meeting of Radiological Society of North America 2002
scientific paper, corresponding author		Discrimination of intervertebral disk extrusion from protrusion with MR imaging	Kim JY, Jee WH, Ha KY, Park CK, Cho SH, Byun JY	88th Scientific Assembly and Annual Meeting of Radiological Society of North America 2002
scientific paper, corresponding author		Subchondral abnormalities of the knee at plain radiography and MR imaging: association of cartilage abnormalities	Kim HR, Jee WH, Kim JM, Kim YS, Cho SH, Byun JY	88th Scientific Assembly and Annual Meeting of Radiological Society of North America 2002
구연		Lateral incomplete discoid tear: differed rom normally shaped lateral meniscal tear?	Ryu KN, Ko KR	RSNA Dec, 2002, Chicago
구연 전시		MR imaging features of chondromyxoid fibroma	Cho SH, Jee WH, Cho KH, Ryu KN, Suh JS, Cho JH	RSNA Dec, 2002, Chicago
구연		MR findings of ischiogluteal bursitis as a buttock pain	KH Cho	RSNA Dec, 2002, Chicago
구연		Anatomy of the Muscle and tendon of the Foot: Correlation of MR Findings with those of Cadaveric Dissection.	이상용,	RSNA(북미방사선학회) USA,시카고 2002
전시		MR features of chondromyxoid fibroma	KH Cho	RSNA2002, Radiology 2002;225(p):461
논문	2003	슬관절 병변의 영상진단	서경진	Arthritis today 2003; 13:56-61
		MR evaluation of radiation	Lee S-H, Suh J-S,	Korean J of Radiology

	synovectomy of the knee with intra-articular injection of Holmium-166-chitosan complex in patients with rheumatoid arthritis:results with four months follow up	Kim H-S, Lee J-D, Song J-S, Lee S-K	2003;4:170-178
	Pharmacokinetic modeling of phagocytic activity of the liver using superparamagnetic iron oxide nanoparticles in dynamic MR imaging.	Na J-B, Suh J-S, Huh Y-M, Kim S-J, Cha S-W, Lee S-H	Yonei medical journal 2003;44:429-437
구연	1.The diagnostic usefulness of CT-guided needle biopsy or aspiration in infectious spondylitis 2. The diagnostic value of CT-guided needle biopsy or aspiration of spine	C-M. Hwang, M. Shin, S.Kim, S. Lee	ECR2003
poster/exhibit	Various manifestations of metastasis of osteosarcoma.	Kim S, Kang H, <u>Choi JA</u>	15 th European Congress of Radiology Meeting, 3.9.-3.14. 2003. Vienna, Austria
Presentation	Radiological findings of first naviculocuneiform coalition	<u>Yun Sun Choi</u> , Sung Moon Kim, Joong Mo Ahn, Sang Jin Bae, Myung Jin Shin, Yong Kyu Yoon	ECR 2003 Scientific Presentation
	Motor fMRI in Acute deep cortical infomotion	정경호, 한영민, 이상용, 정수현,	유럽자기공명학회(ESMRMB) 2003
전시	MR Imaging of Muscle Tear Appearing as a Pseudotumor	정선관,김은아,윤권하,최시성,노병석,원종진	ARRS abstract book 2003.05.04 미국
전시	Patellofemoral impingement and clicking of the knee: Diagnostic value of sagittal MR imaging with arthroscopic correlation	Mi Sook Sung, Hae Gui Lee	ARRS2003
전시	Spectrum of the calcific tendonitis of the shoulder and pelvis: Ultrasonography and MR	Mi Sook Sung	ARRS2003
Lecture	panel discussion (8 cases) us of bone and bone-related pathology	KH Cho	Lecture for Resident Doctors in Radiology", Henry Ford Hospital, May, 2003
포스	Atypical imaging features of soft-	김지영,천경아,성미숙	American Roentgen

터	tissue hemangioma	,김현진,박영하	Ray Society 20030504
구연	Imaging of bone forming tumor	박정미,김지영,성미숙 ,지원희,천경아	10th Annual meeting of European Society of Musculo 20030613 Aarhus, Denmark
Pres ente d	Distinguishing between Isthmic Lumbar Spondylolisthesis and Degenerative Spondylolisthesis: Usefulness of a Fat Interposition Sign on Midline Sagittal MR Images	Kwon ST, Chung CB, Park JG, Byun KY, Rhee KJ, Renick D	103rd Scientific assembly and annual meeting of ARRS. 2003 (SP) 242, San Diego, USA
Pres ente d	Tears of the Central Root Ligaments of the Menisci of the Knee: Assessment of MR Imaging	Kwon ST, Lee HJ, Ahn JM, Kim SM, FJP Tirmam, Shin MJ	. 103rd Scientific assembly and annual meeting of ARRS. 2003 (SP) 300, San Diego, USA
exhi bit	Discogenic lumbar pain: association with CT discography and MR imaging (educational exhibit)	Lim CH, Jee WH, Son BC, Kim YS, Ha KY, Park CK	89th Scientific Assembly and Annual Meeting of Radiological Society of North America 2003
oral pres enta tions	MRI of ACL reconstruction with Quadriceps tendon graft: a prospective study with focus on changes in donor site	<u>Choi JA</u> , Lee MC, Lee SH, Kim JE, Hong SH, Kang HS	89th Scientific Assembly and Annual Meeting of the Radiological Society of North America, 2003. 11. 30 - 12. 5., Chicago, IL, USA
oral pres enta tions	MR Imaging Findings of Kimura Disease in the Soft Tissue of Upper Extremity	<u>Choi JA</u> , Lee GK, Kong KY, Chung HW, Suh JS, Ahn JM, Lee YJ, Cho KH, Park JG, Kang HS	89th Scientific Assembly and Annual Meeting of the Radiological Society of North America, 2003. 11. 30 - 12. 5., Chicago, IL, USA
oral pres enta tions	Enhancing Disc Lesions on Spinal MR Imaging: Multiple Myeloma vs. Metastatic Tumors	Choi JY, Hong SH, <u>Choi JA</u> , Chung HW, Kang HS.	89th Scientific Assembly and Annual Meeting of the Radiological Society of North America, 2003.

			11. 30 - 12. 5., Chicago, IL, USA
oral presentations	Ultrasonography of the Trigger Fingers: On the Emphasis of the Findings of Annular Pulley.	Chung HW, Hong SH, <u>Choi JA</u> , Choi JY, Song CS, Kang HS	89th Scientific Assembly and Annual Meeting of the Radiological Society of North America, 2003. 11. 30 - 12. 5., Chicago, IL, USA
poster/exhibit	Tuberculous Arthritis Revisited: Differentiation from Rheumatoid Arthritis on MR Imaging.	<u>Choi JA</u> , Koh SH, Koh YH, Hong SH, Ahn JM, Kang HS	89th Scientific Assembly and Annual Meeting of the Radiological Society of North America, 2003. 11. 30 - 12. 5., Chicago, IL, USA
포스터	Soft tissue masses of the foot: MR imaging with pathologic correlation	천경아, 구영미, 김지영, 송선화, 이은정, 김기태	RSNA 20031130 Chicago, USA
poster	Subtraction Postprocessing MR Imaging in Postoperative Patients with Metallic Hardware	<u>차장규</u> , 홍현숙, 조준희, 김대호	2003년 RSNA
전시	Bone tumors in the hand: Imaging features according to tumor types	Kim SW, Park JS, Park YK, Ryu KN	2003년 RSNA
구연	Avulsion fractures by the cruciate ligaments in the knee: Are the ligaments intact or not?	Kim SW, Park JS, Ryu KN	2003년 RSNA
구연	Diagnostic accuracy of MR imaging according to the classification of meniscal tears	Kim SW, Park JS, Hong HP, Ryu KN	2003년 RSNA
구연	Osteolysis in long standing-total hip replacement: Spectrum of CT and radiographic findings in 16 cases	Park JS, Hong HP, Ryu KN	2003년 RSNA
Presented	Ultrasonography of the Trigger Fingers: On the Emphasis of the Findings of Annular Pulley	CHUNG HW, Hong SH, Choi JA, Choi JY, Song CS, Kang HS	Presented at the 89th Scientific Assembly and Annual Meeting of RSNA, 2003, Chicago
구연	The Second fracture of the lateral tibial condyle-Injuries assessed with MR imaging	Deuk Lin Choi, MD	Scientific meeting of the college of Radiology Academy

				of Medicine of Malaysia & 5th Annular scientific meeting of the Asian Musculoskeletal Society, Langkawi, Malasia 2003.12.11-14
논문	2004	주관절의 자기공명영상	서경진	단국의대학술지 2004; 5(1): 43-50
논문		Sonography of Bone and Bone-Related Diseases of the Extremities	Kil-Ho Cho, MD, Young-Hwan Lee, MD, Sung-Moon Lee, MD Muhammad Usman Shahid, MD, Kyung Jin Suh, MD, Joon Hyuk Choi, MD	J Clin Ultrasound 2004; 2:511-521
논문		The effect of nuclear Overhauser enhancement in liver and heart 32-P NMR spectra localized by 2D chemical shift technique	Yongmin Chang, Hun-Kyu Ryeom, Jong-min Lee, Yong-Sun Kim, Sang-Kwon Lee, Kyung-Jin Suh, Sung-Jin Bae	Journal of Korean Society of Magnetic Resonance in Medicine 2004; 8:94-99 (2004. 12. 15)
		Extraaxial Neurofibroma versus Neurilemmoma: Discrimination with MR Imaging	Jee W-H, Oh S-N, McCauley TR, Ryu K-N, Suh J-S. etc	AJR 2004;183:629-633
		Intravascular papillary endothelial hyperplasia of the extremities: MR imaging findings with pathologic correlation.	Lee SH, Suh J-S, Lim B-I, Yang WI, Shin K-H	Eur Radiol 2004 ;14:822-826
		Simultaneous Acquisition of Perfusion and Permeability from Corrected Relaxation Rates with Dynamic Susceptibility Contrast Dual Gradient Echo	Kim EJ, Kim DH, Huh YM, Lee SH, Suh J-S.	Magn Reson Imaging 2004;22:307-314
		Synovitis and soft tissue impingement of the ankle: assessment with enhanced 3D-FSPGR MR imaging	Huh Y-M, Suh J-S, Song H-T, Lee J-W	JMRI 2004;19:108-116
		Soft tissue impingement syndrome of the ankle: diagnostic efficacy of MRI and clinical results after arthroscopic treatment	Lee JW, Suh JS, Huh YM, Moon ES, Kim SJ	Foot Ankle Int. 2004 Dec;25(12):896-902

	MR Imaging Findings of painful type II accessory navicular bone: correlation with surgical and pathologic studies	Choi YS, Lee KT, Kang HS, Kim EK	Korean J Radiol 2004;5:274-279
구연	뇌피질이형성증의 뇌표면 묘출영상(Brain surface rendering imaging of cortical dysplasia)	정경호, 한영민, 이상용	European Congress of Radiology 오스트리아빈 2004
구연	Primary and secondary lung malignancy treated with percutaneous radio-frequency ablation: Signal patterns with MR imaging	진공용, 한영민, 이상용	European Congress of Radiology 오스트리아빈 2004
구연	Primary and secondary lung malignancy treated with percutaneous radio-frequency ablation : Evaluation with follow-up helical CT	진공용, 한영민, 이상용, 김상원, 임영수, 정경호,	European Congress of Radiology 오스트리아빈 2004
Poster	Osteoarthritis of the Knee- Comparison of Radiography & MR Imaging	Deuk Lin Choi, MD	10th Asian Oceanian Congress of Radiology(AOCR), Singapore 2004.4.28-5.1
presentation	Imaging findings of unusual complications as a cause of large acupuncture needles in patients with sprain of the back muscle	Ik Yang	AMS, Seoul, Korea 2004.9.2-4
Poster	Clinical utility of immersion method using water-bath in ultrasonographic evaluation of the distal extremity lesions	Ik Yang	AMS, Seoul, Korea 2004.9.2-4
Poster	High-resolucional US findings of common nontumorous conditions at upper and lower extremities	Ik Yang	AMS, Seoul, Korea 2004.9.2-4
Poster	MRI Findings of the Humeral Avulsion of the Inferior Glenohumeral Ligament (HAGL)	Yeon Hee Oh, Philip F. Tirman, Kyung Jin Suh, Soon Kim, Geun Seok Yang, Sung Woo Kim	The 6 th AMS Annual Scientific Meeting, 2004 September 2-4, Lotte Hotel Seoul Jamsil, Seoul, Korea
Poster	Failure of Biodegradable Fixation Devices after Arthroscopic Labral Repair	Yeon Hee Oh, Philip F. Tirman, Young Soo Kim, Kyung Jae Yoo, Kyung Jin Suh, Soon Kim, Geun Seok Yang,	The 6 th AMS Annual Scientific Meeting 2004 September 2-4, Lotte Hotel Seoul Jamsil, Seoul, Korea

		Sung Woo Kim	
pres enta tion	MR imaging of intact posterior cruciate ligament graft: in arthroscopically proven 21 cases	Young Cheol Yoon, Hye Won Chung, Sang-Hee Choi, Jin Hwan Ahn	The 6 th Asian Musculoskeletal Society Annual Scientific Meeting 2004, Seoul, Korea, September 2-4, 2004
oral pres enta tions	Is indirect MR arthrography useful in diagnosis of acetabular labral lesions of the hip?	<u>Choi JA</u> , Koo KH, Lee IS, Lee JW, Goo JB, Choi JY, Hong SH, Kang HS	6th Annual Scientific Meeting of the Asian Musculoskeletal Society, 2004. 9.2-4. Seoul, Korea
oral pres enta tions	Reliability of 16-slice MDCT for pre-operative evaluation of total knee arthroplasty: Comparison with intra-operative measurements	Lee IS, <u>Choi JA</u> , Lee JW, Koo JB, Choi JY, Hong SH, Koh Yh, Han IK, Kim TK, Kang HS.	6th Annual Scientific Meeting of the Asian Musculoskeletal Society, 2004. 9.2-4. Seoul, Korea
post er/e xhibi t pres enta tions	Bright soft tissue masses of the extremities on MR imaging: The spectrum of diseases	Koo JB, Hong SH, Choi JY, Lee JW, Lee IS, Kang HS, Koh YH, <u>Choi JA</u>	6th Annual Scientific Meeting of the Asian Musculoskeletal Society, 2004. 9.2-4. Seoul, Korea
post er/e xhibi t pres enta tions	Finger masses revisited: MR imaging with microcoil and pathologic correlation	Lee IS, <u>Choi JA</u> , Lee JW, Koo JB, Choi JY, Hong SH, Koh YH, Oh JH, Kang HS.	6th Annual Scientific Meeting of the Asian Musculoskeletal Society, 2004. 9.2-4. Seoul, Korea
post er/e xhibi t pres enta tions	Radiologic-pathologic correlation of musculoskeletal angiomatous lesions with an emphasis on radiologic differential diagnosis	Choi JY, Hong SH, <u>Choi JA</u> , Chung HW, Kang HS.	6th Annual Scientific Meeting of the Asian Musculoskeletal Society, 2004. 9.2-4. Seoul, Korea
post er/e xhibi t pres enta tion	Ultrasound elastography: Application in musculoskeletal diseases	Choi JY, Hong SH, Koo JB, <u>Choi JA</u> , Lee IS, Lee JW, Koh YH, Kang HS.	6th Annual Scientific Meeting of the Asian Musculoskeletal Society, 2004. 9.2-4. Seoul, Korea

tions			
포스터	Atypical imaging features of soft-tissue hemangioma	김지영,천경아,성미숙,박영하	AMS 2004 20040902 한국 서울
	US Imaging of Muscle Injury in Lower Extremity	KH Cho	AFSUMB2004 (Asian Ultrasound Society), Japan, 2004
scientific paper	MR Findings of Ossifying Fibroma	Jung JY, Jee WH, Hong SH, Chung HW, Ryu KN, Kim JY, Im SA, Park JM, Sung MS, Whang IY, Lee YS, Hong SJ, Kang HS	6th Asian Musculoskeletal Society Meeting 2004
presentation	Liposclerosing Myxofibrous Tumor (case presentation)	Lim CH, Jee WH, Jung ES, Chung YG	6th Asian Musculoskeletal Society Meeting 2004
구연	The Usefulness and Limitation of Power Doppler Ultrasonography for the Assessment of Enthesitis in the Patients with Spondylarthropathy: A Preliminary Report	이상일, 이상용, 유완희, 정경호, 김상균	Asia Pacific League of Associations for Rheumatology Congress Jeju,Korea 2004
포스터	Enthesitis of Achilles Tendon in Patients with Spondylarthropathy: Imaging Findings and Pathogenesis	이상용, 정경호, 이상일, 유완희	Asia Pacific League of Associations for Rheumatology Congress Jeju,Korea 2004
포스터	Comparison between Power Doppler Ultrasonography and Naifold Capillaoscopy for the Assessment of Microvascularity in Patients with Raynaud's Phenomenon: A Preliminary Report	김상균, 이상용, 이상일, 유완희, 정경호	Asia Pacific League of Associations for Rheumatology Congress Jeju,Korea 2004
	US of Large Joints: Comparison with MR	KH Cho	APLAR2004 (Asian-Pacific League against Rheumatology), Jeju, Korea, 2004
	Limb salvage surgery with recycled autograft augmented with vascularized fibular graft	강용구,정양국,박원종,이승구,박정미,이안희	the 4th meeting of APMSTS
presentation	MR imaging of intact posterior cruciate ligament graft: in arthroscopically proven 21 cases	Young Cheol Yoon, Hye Won Chung, Sang-Hee Choi, Jin Hwan Ahn	60 th Annual Meeting of Korean Radiological Society, Seoul, Korea, October 20-22, 2004

pres enta tion	Posterior labral tear in patient with posterior instability of the shoulder	Young Cheol Yoon, Hye Won Chung, Sang-Hee Choi, Seung-Ho Kim	60 th Annual Meeting of Korean Radiological Society, Seoul, Korea, October 20-22, 2004
exhi bitio n	Imaging of congenital vascular malformation (CVM) in peripheral vascular system: emphasis on non-invasive techniques	Young Cheol Yoon, Young Soo Do, Hye Won Chung, Sang-Hee Choi, In Wook Choo, Hong Sik Byun	60 th Annual Meeting of Korean Radiological Society, Seoul, Korea, October 20-22, 2004
oral pres enta tions	Reliability of 16-slice MDCT for pre-operative evaluation of total knee arthroplasty: Comparison with intra-operative measurements	. Lee IS, <u>Choi JA</u> , Kim TK, Choi JY, Hong SH, Kang HS	90th Scientific Assembly and Annual Meeting of the Radiological Society of North America, 2004. 11. 28 - 12. 3., Chicago, IL, USA
post er/e xhibi t pres enta tions	Ultrasound elastography: Application in musculoskeletal diseases	Choi JY, Hong SH, Koo JB, Koh YH, <u>Choi JA</u> , Kang HS	90th Scientific Assembly and Annual Meeting of the Radiological Society of North America, 2004. 11. 28 - 12. 3., Chicago, IL, USA
post er/e xhibi t pres enta tions	Finger masses revisited: MR imaging with microcoil and pathologic correlation	Lee IS, <u>Choi JA</u> , Choi JY, Oh JH, Hong SH, Kang HS	90th Scientific Assembly and Annual Meeting of the Radiological Society of North America, 2004. 11. 28 - 12. 3., Chicago, IL, USA
exhi bitio n	Imaging of congenital vascular malformation (CVM) in peripheral vascular system: emphasis on non-invasive techniques.	Young Cheol Yoon, Young Soo Do, Yeon Hyeon Choe, Hye Won Chung, Sang Hee Choi, Joong Mo Ahn	The 90 th Scientific Assembly and Annual Meeting, Radiological Society of North America, McCormick Place, Chicago, Illinois, November 28-December 03, 2004
exhi bit	Adhesive Capsulitis of the Shoulder: Evaluation with MR Arthrography (educational exhibit)	Jung JY, Jee WH, Chun HS, Kim YS, Chung YG, Kim JM	90th Scientific Assembly and Annual Meeting of Radiological Society of North America

			2004	
exhibit		The evaluation of finger masses on MRI using microscopy coil : correlation with pathologic and surgical findings	In Sook Lee, MD ^{1,4} , Jung-Ah Choi, MD ^{1,4} , Joon Woo Lee, MD ^{1,4} , Ju Hwan Oh, MD ² , Ja-Young Choi, MD ⁴ , Sung-Hwan Hong, MD ⁴ , Joon Bum Koo, MD ⁴ , Heung Sik Kang ^{1,4} , MD, So Yeon Park, MD	RSNA 2004
poster		Value of 16-Slice MDCT in Pre-Operative Evaluation of Total Knee Arthroplasty: Reliability Analysis Including Comparison with Intra-Operative Measurements	In Sook Lee, M.D. ^{1,2} , Jung-Ah Choi, M.D. ^{2,3} , Tae Kyun Kim, M.D. ⁴ , Il Gyu Han, M.D. ⁴ , Joon Woo Lee, M.D. ^{2,3} , Heung Sik Kang, M.D.	RSNA 2004
poster		Anomalous Insertion of the Medial Meniscus to the Anterior Cruciate Ligament: Golf Club Sign at MR Imaging	차장규, 민경대, 박성진, 박재성, 이해경	RSNA 2004
전시		Role of MR Imaging in Entrapment and Compressive Neuropathies	김성준, 최진영, 송호택, 허용민, 서진석, 서범천, 김승민	RSNA 2004
구연		Injury of the Tibiofibular Syndesmosis of the Ankle: Assessment with Contrast-Enhanced 3D-FSPGR MR Imaging	김성준, 허용민, 서진석, 송호택, 이진우	RSNA 2004
	2005	Imaging Findings of Kimura's Disease in the Soft Tissue of the Upper Extremity	Choi JA, Lee GK, Kong KY, Hong SH, Suh JS, Ahn JM, Lee YJ, Cho KH, Park JG, Choi JY, Kang HS	AJR Am J Roentgenol. 2005 Jan;184(1):193-9
		Sacrococcygeal chordoma: MR imaging in 30 patients	Sung MS, LeeGK, Kang HS, Kwon ST, Park JG, Suh JS, Cho GH, Lee SM, Chung MH, Resnick D	Skeletal radiology 2005 Feb; 34; 87-94.
논문		발목관절의 자기공명영상	서경진	. 단국의대학술지 2005; 6(1): 21-32

논문	급성 화농성 견관절염의 자기공명영상: 관절경적 소견과의 비교 연구	서경진, 전인호, 천상호, 서재성, 고상훈, 최창혁	대한견주관절학회지2005; 8(2):110-116
	MRI of Acute Septic Arthritis of the Shouldder Joint; correlation with Arthroscopic Findings	Kyung Jin Suh, In Ho Jeon, Sang Ho Cheon, Jae Sung S대, Sang Hun Ko and Change Hyuk Choi.	J of Korean Shoulder and Elobw Society. 2005; 8(2):110-111
논문	Carpal Tunnel Syndrome due to Lipo-fibromatous Harmatoma of the Mediannerve. -A case Report-	Il-Hyung Park, Poong-Teak Kim, Kyung-Jin Suh, In-Ho Jeon	The Journal of the Korean Society for Surgery of the Hand 2005:10(2) 79-82
논문	확산 경사자장의 방향수에 따른 분할 비등방성 뇌자기공명영상의 잡음에 대한 히스토그램 분석	장용민 이영주·김용선·강덕식 ·손철호·우성구·서경진	대한영상의학학회지2005; 52(2): 87-92
논문	Metastatic Bone tumors with Sunburst Periosteal Reaction.	Gyung Kyu Lee, Hye Won Chung, Heung Sik Kang, Jin Gyoon Park, Kil Ho Cho, Young Hwan Lee, Sung Moon Lee, Joingmin Lee, Jeong Mi Park, Ik Won Kang, Eil Seong Lee, Dae Hyun Hwang, Seon Jeong Min, Kyung Jin Suh	Journal of Koran Radiological Society 2005: 52(6)419-426
논문	A Case of Pilomatricoma in the Upper Arm: Sonographic and MR imaging Findings	Gyung Kyu Lee, Kyung Jin Suh	Journal of Koran Radiological Society 2005; 52(6):427-430
	Nanoscale size effect of magnetic nanocrystals and their utilization for cancer diagnosis via magnetic resonance imaging (MRI)	Jun YW, Huh YM, Choi JS, Lee JH, Song HT, Kim SJ, Yoon S, Kim KS, Shin JS, Suh JS, Cheon JW	J Am Chem Soc 2005;127(16):5732-3
	Surface modification of magnetic nanocrystals in the development of highly efficient magnetic resonance probes for intracellular labeling.	Song HT, Choi JS, Huh YM, Kim SJ, Jun YW, Suh JS, Cheon JW	J Am Chem Soc 2005;127:9992-9993
	In vivo magentic resonance	Huh YM, Jun YW,	J Am Chem Soc

	detection of cancer by using multifunctional magnetic nanocrystals	Song HT, Kim SJ, Choi JS, Lee JH, Yoon S, Kim KS, Shin JS, <i>Suh JS</i> , Cheon JW.	2005;127:12387-12391
	Intracellular Translocation of Superparamagnetic Iron Oxide Nanoparticles Encapsulated with Peptide-Conjugated Poly (D,L lactide-co-glycolide)	Lee SJ, Jeong JR, Shin SC, Huh YM, <u>Song HT</u> , Suh JS, Chang YH, Jeon BS, Kim JD	Journal of Applied Physics, 2005;97: 10Q913 online.
	The Role of Popliteal Lymph Nodes in Differentiating Rheumatoid Arthritis from Osteoarthritis by Using	Huh YM, Kim SJ, <i>Suh JS</i> , Song HT, Song K, Shin KH	CE KJR 2005; 6(2): 117-124.
	Tumor volume change after chemotherapy as a predictive factor of disease free survival for osteosarcoma.	Moon SH, Shin KH, Suh JS, Yang WI, Noh JK, Hahn SB.	Yonsei Medical Journal 2005;46:119-124
	A shearing osteochondral fracture of the humeral head following an anterior shoulder dislocation in a child	<u>Choi YS</u> , Potter HG, Scher DM	HSSJ 2005;1:100-102
구연	MR Findings for Differentiating stable & unstable Osteochondritis Dissecans-Reappraise the MRI Criteria.	Deuk Lin Choi,MD	7th Annual Scientific Meeting of Asian Musculoskeletal Society, 2005.4.2. Sri Lanka
Poster	MR imaging findings of acute rhabdomyolysis	ST Kwon, I Yang	(ECR) 2005.3.4-8
	MR Image Findings of Acute Rhabdomyolysis	S. <u>Kwon</u> , K. Jung, I. Yang, Y. Kim, Y. Choi, J. Cha	ECR 2005 (EP) C-0723:497, Vienna, Austria
	Image findings of ruptured Baker's cyst.	MH Park, ST Kwon, JY Ohm, BS Shin, YM Kim	ECR 2005 (EP) C-0699: 492, Vienna, Austria
구연	Development of Universal Microbubble ultrasound contrast agent for molecular targeting:In-vitro and In-vivo experimental study	김은아, 최규실, 채권우, 이영환, 윤성언, 정선관, 윤권하	ISMRM 초록 2005.04.20
Poster	Pathologically confirmed solitary bone metastasis evaluation by planar bone scan underlying lung cancer correlation	SY Ham, SO Yang, I Yang	World congress of thoracic imaging and diagnosis in chest disease

	with CT / MR findings		Italia Flolance, 2005.5.8-12
구연	Patellar fractures following total knee replacement	천경아,K. Ohashi,D.L. Bennett,G.Y. El-khoury	105th annual meeting of American Roentgen Ray Society 20050515 New Orleans
전시	Easily Overlooked Fractures at the Lower Extremity	정선관, 김은아, 이영환, 윤성언, 최시성, 노병석	International Skeletal Society 32nd Annual Refresher Course 초록 2005.05.21 미국
	Clinical presentation of Langerhans' cell histiocytosis	정양국,이승구,박원종,이안희,박정미,강용구	the 5th meeting of APMSTS
	Langerhans' cell histiocytosis in patients younger than 2 years	정양국,이승구,박원종,이안희,박정미,강용구	the 5th meeting of APMSTS
	Clinical outcome of stage IIB osteosarcomas in the long bones	정양국,강용구,이승구,김형민,박원종,이안희,박정미	13th ISOLS
전시	Kimura's disease involving the proximal humerus and surrounding skeletal muscles	정양국,강용구,박경신,이안희,박정미,이승구	13th ISOLS
presentation	Morphological appearance of contrast-MR imaging in soft tissue solid tumors	Moon TY	The 14th JKRC, Sapporo, Japan (2005.06.11)
Poster	Clinical utility of immersion method using water-bath in ultrasonographic evaluation of the distal extremity lesions.	Ik Yang	AIUM. USA, Orlando. 2005. 6.19-22
Lecture	US of the shoulder: pathology US of the elbow US of the knee US of the ankle and foot	KH Cho	The 3 rd Int'l Ultrasound symposium (Gazi Univ), Sep 16-18, Ankara, TURKEY, 2005
Oral presentation	16 Slice MDCT arthrography in the evaluation of labral and rotator cuff lesions of the shoulder. A preliminary study with comparison of direct MR arthrography and arthroscopic correlation	<u>Choi JA</u> , Lee IS, Oh JH, Lee JW, Choi J-Y, Hong SH, Koh YH, Kang HS	The International Skeletal Society 2005 Meeting. 2005.9.26-10.1. Singapore.
poster/e	16 slice multidetector CT arthrography in the evaluation of	<u>Choi JA</u> , Lee IS, Oh JH, Lee JW, Kim JY,	The International Skeletal Society 2005

exhibition	pathologic lesions of the shoulder. A preliminary study with comparison with direct MR arthrography and arthroscopic correlation.	Kang HS	Meeting. 2005.9.26-10.1. Singapore.
구연	Adamantinoma	Park YK, Han JS, Ryu KN	ISS 2005,09
전시	Ultrasonography of muscle and nerve	Mi Sook Sung	BEST POSTER Award 수상 International skeletal society (ISS) 32th annual meeting 2005, Singapore.
presentation	Root ligament transaction of medial meniscus: MR findings of arthroscopically confirmed 48 cases	SooHo Bae, Sang-Hee Choi, Jin Hwan Ahn, Hye Won Chung, Young Cheol Yoon	61 st Annual Meeting of Korean Radiological Society, Seoul, Korea, October 19-21, 2005
presentation	Do the additional oblique magnetic resonance imaging of the knee improve diagnostic efficacy for anterior cruciate ligament injury?	Jun Young Park, Young Cheol Yoon, Sang-Hee Choi, Hyun Pyo Hong, Hye Won Chung	61 th Annual Meeting of Korean Radiological Society, Seoul, Korea, October 19-21, 2005
presentation	Comparison of thin-section proton density weighted MR imaging with multiplanar reconstruction (MPR) technique to conventional MR imaging of the knee for the diagnosis of internal derangement of the knee using a 3-Tesla MR machine	Hyun Pyo Hong, Young Cheol Yoon, Sang-Hee Choi, Jun Young Park, Hye Won Chung	61 th Annual Meeting of Korean Radiological Society, Seoul, Korea, October 19-21, 2005
presentation	Spontaneous healing of anterior cruciate ligament (ACL) injuries. Is it possible to predict the degree of ligament insufficiency by MR imaging after healing?	Hyun Pyo Hong, Jun Young Park, Young Cheol Yoon, Sang-Hee Choi, Hye Won Chung	61 th Annual Meeting of Korean Radiological Society, Seoul, Korea, October 19-21, 2005
	Ultrasound of the shoulder: Normal anatomy"	KH Cho	The 15 th Annual congress of Musculoskeletal Ultrasound Society, Rosen Plaza hotel in Orlando, Miami, FL, USA, Nov-06, 2005
포스터	COMP-angiopoietin-1 Ameliorates Renal Tissue damage in Unilateral	김원, 문상옥, 이상용, 성미정,	미국신장학회 미국, 필라델피아 2005

	Ureteral Obstruction mouse model	김덕훈, 이식, 박성광,	
포스터	The usefulness of power Doppler ultrasonography for the diagnosis of Raynaud's phenomenon in undifferentiated connective tissue disease	이상일, 류완희, 이상용, 이명수	미국류마티스학회 샌디에고, 미국 2005
포스터	The usefulness and limitation of power Doppler ultrasonography for the assessment of enthesitis in the patients with spondylarthropathy	이상일, 류완희, 이상용, 이명수,	미국류마티스학회 샌디에고, 미국 2005
presentation	Root ligament transection of medial meniscus: MR findings of arthroscopically confirmed 48 cases	SooHo Bae, Sang-Hee Choi, Jin Hwan Ahn, Hye Won Chung, Young Cheol Yoon.	The 91 st scientific Assembly and Annual Meeting, Radiological Society of North America, McCormick Place, Chicago, Illinois, November 27-December 02, 2005
presentation	Diagnostic value of MR arthrography for evaluation of rotator cuffs and biceps tendons	Hyun Pyo Hong, Hye Won Chung, Sang-Hee Choi, <i>Young Cheol Yoon</i> , Jun Yong Park, Min Hee Lee.	The 91 st scientific Assembly and Annual Meeting, Radiological Society of North America, McCormick Place, Chicago, Illinois, November 27-December 02, 2005
Oral presentation	16 slice multidetector CT arthrography in evaluation of labral and rotator cuff lesions of the shoulder: a preliminary study with comparison of findings with direct MR arthrography and arthroscopic findings	<u>Choi JA</u> , Lee IS, Lee JW, Kwack K, Kwon JW, Kang HS	91st Scientific Assembly and Annual Meeting of the Radiological Society of North America, 2005. 11. 27 - 12. 2., Chicago, IL, USA
Oral presentation	Optimization of the mixture ratio of iodinated contrast and gadolinium for simultaneous direct MR and CT arthrography	Choi JY, Kang HS, Hong SH, Jun WS, Moon SG, <u>Choi JA</u> , et al	91st Scientific Assembly and Annual Meeting of the Radiological Society of North America, 2005. 11. 27 - 12. 2., Chicago, IL, USA
Oral pres	Percutaneous spine injection: consideration for improving	Lee JW, Kim SH, <u>Choi JA</u> , Kang HS	91st Scientific Assembly and Annual

entation	treatment effect.		Meeting of the Radiological Society of North America, 2005. 11. 27 - 12. 2., Chicago, IL, USA
poster/exhibit	The unusual but interesting spinal diseases: MR imaging-operative-pathologic correlation	Jun WS, Lee JW, Kim SH, Kang HS, <u>Choi JA</u> , Hong SH, et al	91st Scientific Assembly and Annual Meeting of the Radiological Society of North America, 2005. 11. 27 - 12. 2., Chicago, IL, USA
poster/exhibit	Radiologic findings of various complications after spine surgery	Kwack KS, Lee JW, Kim SH, <u>Choi JA</u> , Hong SH, Kang HS	91st Scientific Assembly and Annual Meeting of the Radiological Society of North America, 2005. 11. 27 - 12. 2., Chicago, IL, USA
poster/exhibit	Subchondral lesions of the femoral head: pathologic spectrum, multimodality imaging	Moon SG, Hong SH, Choi JY, Jun WS, <u>Choi JA</u> , Kang HS, et al	91st Scientific Assembly and Annual Meeting of the Radiological Society of North America, 2005. 11. 27 - 12. 2., Chicago, IL, USA
poster/exhibit	Various complications in imaging-guided spine intervention	Kwon JW, Lee JW, Kim SH, <u>Choi JA</u> , Kwack KS, Kang HS	91st Scientific Assembly and Annual Meeting of the Radiological Society of North America, 2005. 11. 27 - 12. 2., Chicago, IL, USA
Exhibits	The unusual but interesting spinal diseases: MR imaging-operative-pathologic correlation	Jun WS, Lee JW, Kim SH, Chung SG, Kim KJ, Kim HJ, Choi JY, Hong SH, Kang HS	RSNA 2005
Oral presentation	Therapeutic effect of selective nerve root block for sciatica: intra-versus extraepineural injection	Lee JW, Kim SH, <u>Choi JA</u> , Kang HS	91st Scientific Assembly and Annual Meeting of the Radiological Society of North America, 2005. 11. 27 - 12. 2., Chicago, IL, USA

post e		16 Slice Multidetector CT Virtual Arthroscopy: Application to Labral Lesions of Shoulder Joint	차장규,민경대,박성진,김대호,이혜경	2005년 RSNA
pres enta tion		A Pragmatic Protocol for Reduction of the Metal Artifact and Radiation Dose in Multi-Slice CT of the Spine; Cadaveric Evaluation after Cervical Pedicle Screw Placement	In Sook Lee, M.D. ^{1,2} , Hak Jin Kim, M.D. ^{1,2} , Byung Kwan Choi, M.D. ³ , Yeon Joo Jeong, M.D. ^{1,2} , Tae Hong Lee, M.D. ^{1,2} , Tae-Yong Moon, M.D. ^{1,2} , Dong Won Kang ⁴	RSNA 2005 oral presentation
전시		Quantitative MR imaging or early degenerative changes in articular cartilage	SJ Lee, YM Park, JH Yoon, SJ Choi, CK Eun, SS Jeong	Radiological Society of North American(RSNA) , Chicago, USA 2005, Nov 27
포스 터		Radiographic image findings of the skin lesion	김지영,천경아,안명임,박영하	RSNA 20051201 미국
전시		Characteristic appearance of skeletal cortical and juxtacortical lesions on MR imaging.	김성준, 허용민, 송호택, 김세훈, 신규호, 서진석	RSNA 2005
전시		MRI Features of Atypical Skeletal Giant Cell tumor: Results from Retrospective Review of 118 Cases	이성아, 김성준, 송호택, 허용민	RSNA 2005
전시		Overcoming Orthopedic Metal Artifact in State-of-the-art Imaging Modalities of High Magnetic Field MR Imaging and Multidetector CT : Theories and Tips with Pros and Cons	이미정, 김성준, 이성아, 송호택, 허용민, 서진석	RSNA 2005
	2006	Magnetic Resonance Imaging: Fast Spin Echo Image	Dong Soo you, young Seok Lee, Jee Young Lee, You Me Kim, Kyung Jin Suh	Dankook Medical Journal 2006; 7(1): 1-8
		Arthroscopic Management of Septic Arthritis of the Shoulder Joint	In-Ho Jeon, Chang-Hyuk Choi, Jae-Sung Seo, Kyung-Jin Seo, Sang-Hun Ko, and Jin-Young Park.	J. Bone Joint Surg. Am., 2006; 88: 1802-1806
논문		A Case of Dialysis-related Amyloidosis of the Hip and Cervical Spine: Imaging Findings	Gyung Kyu Lee, M.D., Ik Won Kang, M.D., Seon Jung	Journal of the Korean Radiological Society 2006; 54 (5):435-439

		Min, M.D., Seong Whi Cho, M.D., Seok Woo Kim, M.D., Woo Young Jang, M.D., Seon-Joo Lee, M.D., Kyung Jin Suh, M.D	
	MR Imaging Findings of Acute Gouty Arthritis	Gyung Kyu Lee., Jee Young Lee, Jin-Suck Suh., Jae-Boem Na., Ik Yang., Ik Won Kang, Eil Seong Lee., Dae Hyun Hwang, Seong Whi Cho, Seon Jung Min., Eun-Sook Ko, Kyung Jin Suh	Journal of the Korean Radiological Society 2006; 55(2):165-171
논문	MR Findings of Hypoxic Brain Damage: Relation to Time Elapse and Prognosis of Patients.	Kyung Jin Suh, Chae Hoon Kang, Dong Soo Yoo, Sang Joon Kim	J Korean Soc. Magn. Reson. Med 2006; 10:8-15
	Anatomic variations and MR imaging of the intermalleolar ligament	Oh CS, Won HS, Hur MS, Chung IH, Kim S, Suh JS, Sung KS	AJR 2006;186:943-947
	Anterior inferior labral lesions of recurrent shoulder dislocation evaluated by MR arthrography in an adduction internal rotation(ADIR) position	Song HT, Huh YM, Kim SJ, Kim SJ, Shin KH, <i>Suh JS</i>	JMRI 2006;23:29-35
	Sonographic evaluation of a tibial periosteal ganglion with an intraosseous component	<u>Choi YS</u> , Kim B-S, Kim DH, Chun TJ, Yang S-O, Choi KH	J Ultrasound Med 2006;25:1369-1373
포스터	MR arthrography of rotator interval complex: pictorial review	신유리,천경아,김기태,권오수	ECR 20060303 Vienna, Austria
포스터	MR differentiation of low-grade chondrosarcoma from enchondroma	선우희정,지원희,조재현,김지영,천경아,홍석주,정혜원,성미숙,이연수,정양국	ECR 20060303 Vienna, Austria
포스터	Extracranial Langerhans cell histiocytosis: Plain radiographic and MR features according to evolutionary phases	손정민,지원희,홍석주,김지영,성미숙,류경남,임수아,천경아,이연수,조재현	ECR 20060303 Vienna, Austria
전시	How often multiple myeloma can involve posterior elements of the spine?	박정미,김선기,지원희	European Society of Musculoskeletal Radiology

exhibit	Partial-thickness Tears of Rotator Cuff: Diagnosis with MR Arthrography including ABER View (educational exhibit)	Choi BB, Jee WH, Jung JY, Chun HJ, Kim YS, Kim JM	European Congress of Radiology 2006
exhibit	Extracranial Langerhans Cell Histiocytosis: Plain Radiographic and MR Features according to Evolutional Phases (educational exhibit)	Son JM, Jee WH, Hong SJ, Kim JY, Sung MS, Ryu KN, Im SA, Chun KA, Lee YS, Cho JH, Chung YG, Ok IY	European Congress of Radiology 2006
exhibit	MR Differentiation of Low-Grade Chondrosarcoma from Enchondroma (educational exhibit)	Sunwoo HJ, Jee WH, Cho JH, Kim JY, Chun KA, Hong SJ, Chung HW, Sung MS, Lee YS, Chung YG	European Congress of Radiology 2006
구연	TREATMENT OF METASTATIC RENAL CELL CARCINOMA IN BONE	IH Park, KJ Suh*	The 6th Meeting of Asia Pacific Musculoskeletal tumor society. Jan 18-20, 2006 Chiang Mai, Thailand
강의	ultrasound of bursae	KH Cho	The 16th annual conference of musculoskeletal ultrasound society (Seoul), April 2006
외부수련	권희진 동아대학교병원 4 년차. 근골격계	서경진	2006. 4. 1- 4. 30
외부수련	이종률 부산보훈병원과장. 근골격계	서경진	2006. 4. 10-13
Lecture	Topic 1: Rotator cuff of the shoulder-normal and pathological sonographic appearance. Topic 2: Ultrasound of the hand and wrist-normal and pathological sonographic appearance	KH Cho	Lecture in "A Sunday of Ultrasound", organized by College of Radiology, Academy of Medicine of Malaysia & WFUMB, April-16-2006
강의	MR imaging anatomy of the knee joint	Ryu KN	JSS 2006.04
구연	MR arthrographic analysis of SLAP lesions with an emphasis on	최선영,천경아,김기태,권오수	ARRS 20060430 Vancouver, Canada

	accompanying various shoulder abnormalities		
post er/e xhibi t pres enta tions	The Value of MR Imaging Using Microscopy Coil in Evaluation of Finger Masses: Correlation with Pathologic and Surgical Findings	Lee IS, <u>Choi JA</u> , Oh JH, Kang HS	14 th Scientific Meeting and Exhibition, 2006.5.6-5.12. Seattle, Washington, USA
구연	Comparison study of MR-arthrography and Arthroscopy in PTRCT	권오수,천경아	JOA 20060519 Japan
강의	Ultrasound of muscle injury diagnosed with cine clip	<u>KH Cho</u>	WFUMB2006
Exhi bitio n	High-resolution sonography of the wrist and hand: pictorial review of ultrasonic anatomy and pathology	<u>Yun Sun Choi</u> , Ronald S. Adler, Carolyn M. Sofka, Kyu Ho Choi, Sung Won Park, Jin Kyung An, Sang Heum Kim, Jeong Joo Woo, Hyun-Sook Kim, Chang Yul Han	WFUMB 2006
Exhi bitio n	Ultrasound evaluation of tibial periosteal ganglion with intraosseous component	<u>Yun Sun Choi</u> , Kyu Ho Choi, Byoung-Suck Kim, Dong Hoon Kim, Tong Jin Chun, Seoung-Oh Yang	WFUMB 2006
Oral pres enta tion	Why don't you use the water-bath immersion technique in the sonographic examination of the hand, wrist, foot, and ankle?	Ik Yang	WFUMB 2006 2006.5.27-6.1 Seoul, Korea
Oral pres enta tion	Comparison of three - and two dimensional sonography in diagnosis of tendon, ligament, and fascia pathology; early experience	Ik Yang	WFUMB 2006 2006.5.27-6.1 Seoul, Korea
Oral pres enta tion	Comparison of three - and two dimensional sonography in diagnosis of palpable soft tissue mass at extremity; early experience	Ik Yang	WFUMB 2006 2006.5.27-6.1 Seoul, Korea
pres enta	Feasibility of Ultrasonography in Hemiplegic Shoulders of Stroke	¹ In sook Lee, M.D., ² Yong Beom Shin,	WFUMB 2006

tio	Patients Duing Rehabilitation Treatment	M.D., ¹ Tae-Yong Moon, M.D.	
	Ultrasound of bone and bone-related diseases	Cho K-H, Lee Y-H, Lee s-M	Ultrasound Med Biol 2006;32(5S):p59
전시 및 구연	Ultrasound in diagnosing fracture of the immature bone in children when radiography is normal or equivocal	Kim KR, Cho KH, Lee SM, Lee YH	WFUMB2006
전시 및 구연	The use of ultrasound in the diagnosis of fracture in adults with normal or equivocal findings on radiography	Kim KR, Cho KH, Lee SM, Lee YH	WFUMB2006
전시 및 구연	Ultrasonography in meniscal tear: comparison with MRI.	Lee S-M, Kim M-J, Kim Y-H, Choi J-S, Ko S-M, Lee S-K, Cho K-H.	WFUMB2006
전시 및 구연	Ultrasonographic findings of subcutaneous and muscular sparganosis	Lee S-M, Sohn C-H, Lee H-J, Kwon J-H, Woo S-K, Cho K-H	WFUMB2006
전시	Iliopsoas bursitis complicating total hip arthroplasty : Sonographic finding	<u>SJ Lee</u> , JS Park, YM Park, CK Eun, JH Ryu, SJ Jeong	Official Journal of the World Federation for Ultrasound in Medicine and Biology(WFUMB), Seoul, Korea, 2006, May 28
외부 수련	김수연 동아대학병원 4년차 근골격계	서경진	2006.06.01-06.30
구연	Metastatic Bone tumors with Surburst Periosteal Reaction	Kyung Jin Suh, Jee young Lee, Il Hyung Park	The 39th Annual Musculoskeletal Tumor Meeting of the Japanease Orthopaedic Association, 2006 July 5-7, Sapporo Convention Center, Hokaido, Japan
E-Poster	Artifactual evaluation in tissue components of soft tissue solid tumors: Comparison of MEDIC and conventional T2 weighted MR images	Moon TY	The 11th AOCR, Hongkong, China (2006.08.06)
포스터	Partial-thickness rotator cuff tears of both articular and bursal	천경아	AOCR 20060806 Hong Kong

	surfaces: evaluation with MR arthrography		
Oral presentation	Comparison of imaging features of hand on high resolutional sonography with water bath immersion technique and MRI with microscopic coil	Ik Yang	AOCR 2006 2006.8.6-9 Hong Kong, China
Poster	High-resolutional US findings of common nontumorous conditions at upper and lower extremities	Ik Yang	AOCR 2006 2006.8.6-9 Hong Kong, China
구연	MR corner sign: Its value for predicting of the presence of ankylosing spondylitis	Na Ra Kim, Ja-Young Choi, Sung Hwan Hong, Woo Sun Jun, Joon Woo Lee, Jung Ah Choi, Heung Sik Kang	AOCR 2006 2006.8.6-9 Hong Kong, China
exhibit	Disc Degeneration of the Lumbar Spine: Association with Endplate Abnormalities and Facet Joint Osteoarthritis at MR Imaging. (educational exhibit)	Kim HS, Jee WH, Lim CH, Choi SY, Ha KY.	Asian Ocean Congress of Radiology 2006
	Partially torn posterior cruciate ligament causing medial tibiofemoral joint impingement in the knee: Correlation of MR images with arthroscopic findings	kwon ST, Kim YM, Song CJ, Kim JH, Yoon CD, Rhee KJ.	ARRS 2006 (EP) E-239:115, Vancouver, Canada
전시	Clinical Outcome and Prognostic Factors of Chondrosarcomas	정양국, 이승구, 강용구, 이안희, 박정미, 허성우	The 6th Congress of APMSTS
전시	Surface Lesions of the Appendicular Skeleton: Pictorial Review Focusing on MR imaging	김성준, 서진석, 주경빈, 김세훈, 신규호, 허용민	International Skeletal Society (ISS) annual meeting 2006
전시	Imaging of Hip & Groin Pain in Athletes: Emphasis on MRI	Mi Sook Sung, Hae G Lee	ISS2006
구연	External Snapping Hip Syndrome: Emphasis on MR Imaging	Jung E Choi, Mi Sook Sung, Hae G Lee, Ki H Lee	ISS2006
oral presentations	The Value of MR Imaging Using Microscopy Coil in Evaluation of Small Soft Tissue Masses of Hand and Foot: Correlation with Pathologic and Surgical Findings	Choi JA, Lee IS, Oh JH, Gong HS, Choi JY, Hong SH, Kang HS	The International Skeletal Society 2006 Meeting. 2006.9.9-9.16. Vancouver, Canada.
oral	Indirect MR arthrography in	Choi JA, Koo KH, Lee	The International

pres enta tions	patients with hip or inguinal pain: pathology of labrum and ligamentum teres	JW, Choi JY, Hong SH, Kang HS	Skeletal Society 2006 Meeting. 2006.9.9- 9.16. Vancouver, Canada.
Lect ure topic s	Muscle Ultrasound: Anatomy and pathology Ultrasound Imaging of the Shoulder: Non-Rotator Cuff Pathology Hand and Wrist Ultrasonography: Anatomy and Pathology Ultrasonography of the Knee Joint Bursal Pathology Ultrasonography of Soft Tissue Tumors	KH CHO	Master Course in Musculoskeletal Ultrasound" in Goa, India, from Sep-27- 2006 to Oct-01-2006
pres enta tio	Isotropic MR imaging of shoulder: a prospective study with indirect MR arthrography	Young Cheol Yoon, Hye Won Chung, Sang-Hee Choi, Jong Won Kwon, Sang-Kyu Yi, Jae Chul Yoo	62 nd Annual Meeting of Korean Radiological Society, Seoul, Korea, October 30- November 1, 2006
pres enta tio	Central hole tears of the discoid meniscus of the knee in MR imaging: mimicking bucket-handle tear	Jin Wook Choi, Hye Won Chung, Jin Hwan Ahn, Young Cheol Yoon, Sang- Kyu Yi	62 nd Annual Meeting of Korean Radiological Society, Seoul, Korea, October 30- November 1, 2006
pres enta tio	Accuracy of 3T MRI using 1.5 mm thin slice thickness images to detect meniscal and ligamentous tears of the knee	Hye Won Chung, Jong Won Kwon, Sang-Kyu Yi, Sang- Hee Choi, Young Cheol Yoon, Sang- Hoon Lee, Jin Hwan Ahn	62 nd Annual Meeting of Korean Radiological Society, Seoul, Korea, October 30- November 1, 2006
pres enta tio	Common accompanying lesions with highly attached posterior meniscomfemoral ligament to medial femoral condyle on complete discoid meniscus	Eun Young Kim, Sang-Hee Choi, Sang-Kyu Yi, Jong Won Kwon, Young Cheol Yoon, Hye Won Chung.	62 nd Annual Meeting of Korean Radiological Society, Seoul, Korea, October 30- November 1, 2006
pres enta tio	Subscapularis tendon tears: preoperative detection and grading at 3T MR arthrography	Sang-Kyu Yi, Jong Won Kwon, Hye Won Chung, Jae Chul Yoo, Young Cheol Yoon, Sang-	62 nd Annual Meeting of Korean Radiological Society, Seoul, Korea, October 30- November 1, 2006

		Hee Choi	
pres enta tio	Isotropic MR arthrography of the shoulder: comparison to conventional MR arthrography using a 3-Tesla MR.	Sang-Kyu Yi, Young Cheol Yoon, Jong Won Kwon, Sang-Hee Choi, Hye Won Chung, Jae Chul Yoo	62 nd Annual Meeting of Korean Radiological Society, Seoul, Korea, October 30- November 1, 2006
pres enta tio	Comparison study of indirect MR arthrography versus direct MR arthrography of the shoulder	Sang-Kyu Yi, Young Cheol Yoon, Jong Won Kwon, Sang-Hee Choi, Hye Won Chung, Jae Chul Yoo	62 nd Annual Meeting of Korean Radiological Society, Seoul, Korea, October 30- November 1, 2006
구연	Molecular MR imaging of collagen-induced arthritis with endothelial cell-targeted ICM-1 antibody-conjugated Gd-DTPA	이상용, 박건, 이상일, 정경호	The society for Molecular Imaging 하와이 2006
pres enta tio	Central hole tears of the discoid meniscus of the knee in MR imaging: mimicking bucket-handle tear	Sang-Kyu Yi, Jin Wook Choi, Hye Won Chung, Jin Hwan Ahn, Young Cheol Yoon.	The 92 nd Scientific Assembly and Annual Meeting, Radiological Society of North America, McCormick Place, Chicago, Illinois, November 26- December 01, 2006
oral pres enta tions	16 Slice Multidetector CT (MDCT) arthrography in the evaluation of anterior shoulder instability with arthroscopic correlation	<u>Choi JA</u> , Oh JH, Kim JY, Choi SK, Hong SH, Kang HS, Choi JY, Lee JW	92 nd Scientific Assembly and Annual Meeting of the Radiological Society of North America, 2006 11. 26 - 12. 1., Chicago, IL, USA
oral pres enta tions	16 Slice Multidetector CT (MDCT) arthrography in the evaluation of SLAP lesions with arthroscopic correlation	<u>Choi JA</u> , Oh JH, Kim JY, Choi JY, Hong SH, Kang HS, Lee JW	92 nd Scientific Assembly and Annual Meeting of the Radiological Society of North America, 2006 11. 26 - 12. 1., Chicago, IL, USA
post er/e xhibi t pres enta tions	Rotator Cuff and Labral Anatomy and Abnormalities of the Shoulder on CT Arthrography (CTA) using 16 MDCT: Correlation with Arthroscopic Findings in Real-time	Choi SK, <u>Choi JA</u> , Oh JH, Lee JW, Kang HS, Hong SH, Choi JY	92 nd Scientific Assembly and Annual Meeting of the Radiological Society of North America, 2006 11. 26 - 12. 1., Chicago, IL, USA

Exhibition	MR Imaging of cartilage repair in the knee and ankle.	Yun Sun Choi, Hollis G. Potter, Tong Jin Chun	RSNA 2006 Educational Exhibition
Exhibition	Bone marrow edema pattern of ankle and foot injuries on MR imaging.	Yun Sun Choi, Hollis G. Potter, Tong Jin Chun, Seung-oh Yang, Kyu Ho Choi	RSNA 2006 Educational Exhibition
포스터	Partial-thickness rotator cuff tears: evaluation with MR arthrography	김은희, 천경아, 권오수	RSNA 92nd scientific assembly and annual meeting 20061126 Chicago, USA
포스터	Benign Soft Tissue Tumors in the Digit: Focus on Plain Radiograph and MR Imaging	김유성, 김지영, 천경아	RSNA 92nd scientific assembly and annual meeting 20061130 Chicago, USA
	Discrimination of Necrotizing Fasciitis from Pyomyositis with MR Imaging: a Preliminary study (scientific paper)	Seok JH, Jee WH, Lee SY, Kim YS, Chung YG, Kim YR	92nd Scientific Assembly and Annual Meeting of Radiological Society of North America 2006
논문	Successful intraarterial and transvenous embolization of persistent trigeminal artery-cavernous	최시성, 전세정, 이영환, 김은아, 정선관, 노병석	미국 ESNR 초록 2006.11.21
구연	Accuracy for Detection of Glenoid Labral and RC Tears: Prospective Evaluation with CT Arthrography and MR Arthrography	정선관, 김강득, 김혜원, 이성아, 김형준	RSNA Scientific Assembly and Annual Meeting Program 2006 .11.26 McCormick Place, Chicago
poster	16-slice Multidetector CT Virtual Arthroscopy: Application to Tears of Triangular Fibrocartilage of the Wrist	차장규, 민경대, 백상현, 박성진, 김대호, 이해경	RSNA 2006, 12
구연	MR findings of sequestered disc: Is there any complementary features except separation from patent disc?	Sim SY, Park JS, Ryu KN	RSNA 2006, 12
전시	Feasibility of CT Angiography in the Evaluation of Varicosities: How and What to Help in Determining Therapeutic Plan?	김성준, 주경빈, 박동우, 박충기, 이흥기, 김용수, 허정남	RSNA 2006
구연	Is standard MR Imaging	김현지, 김성준,	RSNA 2006

		Suboptimal for the Evaluation of Rotator Cuff Tear? Comparison of Diagnostic Performance between MR Arthrography versus Standard MR Imaging in 41 Patients with Arthroscopic Confirmation	이성아, 이지혜, 주경빈, 박태수	
구연		Anterolateral Soft Tissue Impingement of the Ankle: Assessment with Contrast-enhanced Three-dimensional Fast Spoiled Gradient (3D-FSPGR) MR Imaging	HJ Choo, MI Kim, SJ Kim, YM Hur, SJ Suh.	Radiological Society of North American(RSNA) , Chicago, USA 2006, Nov 27
Presented		Central Hole Tear of the Discoid Meniscus of the Knee in MR Imaging: Mimicking Bucket-Handle Tea	Choi JW, CHUNG HW, Ahn JH, Yoon YC.	Presented at the 92th Scientific Assembly and Annual Meeting of RSNA, 2006, Chicago. Samsung Medical Center. Sungkyunkwan University School of Medicine
	2007	Artificially engineered magnetic nanoparticles for ultrasensitive molecular imaging	Lee J-H, Huh Y-M, Jun Y-W, Seo J-W, Ko SJ, Song H-T, Kim S, Cho E-J, Yoon H-G, Suh J-S, Cheon J	Nature Medicine 2007(Jan);13:95-99. (IF; 28.58)
		In vivo MR Imaging of Tissue-engineered Human Mesenchymal Stem Cells Transplanted to Mouse: a Preliminary Study	Ko IK, Song HT, Cho EJ, Lee ES, Huh YM, Suh JS.	Ann Biomed Eng. 2007 Jan;35(1):101-8.
		Chronic Tibiofibular Syndesmosis Injury of the Ankle: Evaluation with Contrast-Enhanced Fat-Suppressed 3D-FSPGR MR Imaging and Cadaveric Correlation	Kim S, Huh Y-M, Song H-T, Lee S-A, Lee JW, Suh JS	Radiology. 2007 Jan;242(1):225-235.
		Overcoming Orthopedic Metallic Artifacts in state-of-the-art Imaging Modalities of High Magnetic Field MR Imaging and Multi-detector row CT: Theories and Tips with Pros and Cons	Lee M-J, Kim S, Lee S-A, Song H-T, Huh Y-M, Kim DH, Han SH, Suh J-S.	Radiographics 2007;27:791-803
		Chronic tibiofibular syndesmosis injury: the diagnostic efficiency of magnetic resonance imaging and	Han SH, Lee JW, Kim S, Suh JS, Choi YR	Foot Ankle Int.2007;28:336-42

	comparative analysis of operative treatment		
	Role of magnetic resonance imaging in entrapment and compressive neuropathy—what, where, and how to see the peripheral nerves on the musculoskeletal magnetic resonance image: part 1. Overview and lower extremity	Kim S, Choi J-Y, Huh Y-M, Song H-T, Lee S-A, Kim SM, <i>Suh J-S</i> .	European Radiology; 2007;17:139-149
	Role of magnetic resonance imaging in entrapment and compressive neuropathy—what, where, and how to see the peripheral nerves on the musculoskeletal magnetic resonance image: part 2.upper extremity	Kim S, Choi J-Y, Huh Y-M, Song H-T, Lee S-A, Kim SM, <i>Suh J-S</i>	European Radiology; 2007;17:509-522
한 문	Morton neuroma : evaluated with Ultrasonography (US) and MR imaging	Lee M-J, Huh Y-M, Song H-T, Kim S, Lee J-W, <i>Suh J-S</i>	KJR 2007;8:148-155
	Osteosarcoma arising in a polyostotic fibrous dysplasia: A case report	Kyung Jin Suh	J Korean Soc Magn Reson Med 2007; 11:49-53 채택: 2007. 5. 7
	Fluorodeoxyglucose-Positron Emission Tomography for Diagnosis of Single Bone Metastasis: Comparison With Bone Scintigraphy	Hur J, Yoon CS, Ryu YH, Yun MJ, Suh JS.	J Comput Assist Tomogr. 2007 September/October;31(5):812-819. (IF;1.53)
	Efficacy of multidetector row computed tomography of the spine in patients with multiple myeloma:Comparison with MR imaging and fulorodeoxyglucose positron emission tomography	Hur J, Yoon C-S, Ryu YH, Yun MJ, Suh JS	J CAT 2007;31:342-347. (IF;1.53)
한 문	Intracortical lipoma of the femur	Sun-Joo Lee , Jeong-Hee Yoon, Jae-Ik Bae, Choong-Ki Eun, Jung-Ah Choi, <u>Kyung-Jin Suh</u> , Seung-Seok Seo, Dong-Joon Ha	Skeletal Radiol, 2007; 36 Suppl 1: S77-81. 2007. 06. 01 Published
한 문	A case of scapulothoracic	GK Lee, KJ Suh, JA	Acta Radiol, Nov

	dissociation with brachial plexus injury: magnetic resonance imaging findings	Choi, HY Oh.	2007; 48(9): 1020-1023
논문	Imaging of the brachial plexus	Kyung Jin Suh, Jeong Hyun Lee, Gyung Kyu Lee	J Korean Soc Magn Reson Med 2007; 11(2):119-126 채택: 2007. 11. 28
논문	A case of pedunculated localizing nodular synovitis of the knee: MR imaging findings	Jae Hwand Lee, Jee Young Lee, <u>Kyung Jin Suh</u>	J Korean Soc Magn Reson Med 2007; 11(1):54-57
논문	Osteopathia Striata with Cranial Sclerosis: Report of Two Cases.	Nae Jung Rim, M.D., Ok Hwa Kim, M.D., Kyung Jin Seo, M.D., Young Seok Lee, M.D	Journal of the Korean Radiological Society 2007; 56 (3):293-296
	Multifunctional Magneto-Polymeric Nanohybrids for Targeted Detection and Synergistic Therapeutic Effects on Breast Cancer	Yang J, Lee CH, Ko HJ, Yoon HG, Suh JS, Lee K, Huh YM, Haam S.	<i>Angewandte Chemie International Edition</i> 2007, 46(46), 8836-8839. (IF;10.23)
	Synthesis of ultrasensitive magnetic resonance contrast agents for cancer imaging using PEG-fatty acid	Yang J, Lee TI, Lee J, Lim EK, Hyung W, Lee CH, Song YJ, Suh JS, Yoon HG, Huh YM, Haam S	<i>Chemistry of materials</i> 2007, 19(16), 3870-3876. (IF:5.10)
	Antibody conjugated magnetic PLGA nanoparticles for diagnosis and treatment of breast cancer	Yang J, Lee CH, Park J, Seo S, Lim EK, Song YJ, Suh JS, Yoon HG, Huh YM, Haam S	<i>Journal of Materials Chemistry</i> 2007, 17, 2695-2699.(IF; 4.27)
	Magnetic resonance imaging in the evaluation of osteochondritis dissecans of the patella	<u>Choi YS</u> , Cohen NA, Potter HG, Mintz DN	Skeletal Radiol 2007;36:929-935
구연	강직성 척추염 환자에서 MR, CT를 이용한 Etanercept 사용 전후 평가	이상일, 제1:이상용, Hwang MH, Yoo WH, Kim SH	The European league against rheumatism 스페인 바르셀로나 2007
포스터	Insulin resistance and metabolic syndrome in gout	류완희, 제1:이상일, 윤희진, 이명수, 이상용	유럽류마티스학회 스페인 바르셀로나 2007
포스터	Assessment of sacroiliac joint by using magnetic resonance and computerized tomography imaging in patients with	류완희, 제1:이상일, 이상용, 황민호, 김상현,	유럽류마티스학회 스페인 바르셀로나 2007

	ankylosing spondylitis before and after therapy with etanercept		
pres enta tio	Perineural air injection as thermal protection method of sciatic nerve during RF ablation: an experimental study in rabbits.	Young Cheol Yoon, Eun Yoon Cho, Bong-Keun Choi	Annual Meeting of Korean Society of Medical Ultrasound, Seoul, May 18-19, 2007
	A case of pedunculated localizing nodular synovitis of the knee: MR imaging findings	Jae Hwand Lee, Jee Young Lee, Kyung Jin Suh	J Korean Soc Magn Reson Med 2007; 11(1):54-57 채택: 2007. 5. 30
	Intracortical lipoma of the femur.	Sun-Joo Lee , Jeong-Hee Yoon, Jae-Ik Bae, Choong- Ki Eun, Jung-Ah Choi, Kyung-Jin Suh, Seung-Seok Seo, Dong-Joon Ha	Skeletal Radiol, 2007; 36 Suppl 1: S77-81. 2007. 06. 01 Published
exhi bit	Segmental Arteries in Kummell's Disease: Correlation of MR Angiography with Surgical and Pathologic Findings (educational exhibit)	Jeong HS, Jee WH, Ha KY	34th International Skeletal Society Annual Meeting 2007
구연	16-Slice MDCT Arthrography of the Shoulder: Diagnostic Accuracy for Detection of Glenoid Labral and Rotator Cuff Tears	SK Juhng, GD Kim, HW Kim, S Lee, HJ Kim	ESSR (European Skeletal Society of Radiology) 14th Annual Meeting 2007.06.02
exhi bit	Feasibility of Ultrasonography in Hemiplegic Shoulders of Stroke Patient	¹ In sook Lee, M.D., ² Yong Beom Shin, M.D., ¹ Tae-Yong Moon, M.D	ESSR 2007 Education exhibit
exhi bit	A pictorial essay of subcutaneous lesions in musculoskeletal system ; Emphasis on MR imaging	In Sook Lee, Kyung Un Choi, Jeong Il Kim, Tae-Yong Moon, Jong Woon Song	ESSR 2007
E- Post er	Radiological features of finger megadactylia; report of 2 different type	Moon TY	ESSR2007, Ismir, Turkey (2007.06.02)
구연	Monitoring effect of heme oxygenase 1 modulation with ultrasound biomicroscopy and micro-radiography in rheumatoid	E.-a Heo, S.-E Yoon, Y.-H.Lee, S.-K. Juhng, K-H.Yoon	ECR초록 2007.06.11

	arthritis mouse models		
	Meniscal Root Radial Tears: Reliability and Accuracy of Diagnosis with MR Imaging and Associated Findings. (scientific paper)	Lee SY, Jee WH, Kim JM	European Congress of Radiology 2007
exhibit	Superficial Cartilage Defects of Medial Femoral Condyle: Diagnosis with Fat-Suppressed Three-Dimensional Spoiled Gradient-Echo MR imaging. (educational exhibit)	Lee SY, Jee WH, Kim YS, Kim JM	European Congress of Radiology 2007
Lecture	The role of musculoskeletal ultrasound according to clinical situation	KH Cho	Lecture at the 4 th ISPRM (Int'l Society of Physical & Rehab. Med) Congress, Jun-13, 2007, Seoul, Korea
	" Ultrasound of heel pain	KH Cho	The 17 th Annual congress of Musculoskeletal Ultrasound Society, Palais des Congres, Paris, France, Aug-28, 2007
	MR Findings of Ossifying Fibroma	김현수,지원희,정준용,홍성환,정혜원,류경남,김지영,임수아,박정미,성미숙,황인용,이연수,홍석주,강홍식	Asian Oceanian Congress of Radiology
구연	MR Imaging Following Arthroscopic Repair of Medial Meniscal Root Tear	Shim Jae-Chan, Kim Jin Goo, Gwon Dong Il, Lee Ghi Jai, Kim Ho Kyun	ARRS 2007년
	Significance of vascularities within the medial nerve in patient with carpal tunnel syndrome: Assessment of color Doppler imaging	Yoon C, Kwon S, Sohn E, Jeon J, Shin H	ARRS. 2007 E281 109, Orlando, USA
	Functional result of no reconstruction after internal hemipelvectomy for periacetabular malignant tumors	박원종,이승구,강용구,이안희,박정미,정양국,신덕섭,최준혁	14th Biennial Congress of ISOLS
poster/e	Ultrasonography of the shoulder: normal anatomy and pathology	<u>Choi JA</u>	34 th Annual ISS Radiology Refresher

exhibit	with MR and CT arthrographic and arthroscopic correlation		Course, 2007.10.10-13., Budapest, Hungary
전시	MR imaging of the inflammatory myopathies	Mi Sook Sung, Jun K Min, Myung H Chung	ISS2007
presentation	Scan-type direct radiography of lower extremities: comparison to computed radiography in image quality and radiation dosage	Kwang Hwi Lee, Young Cheol Yoon, Jong Won Kwon, Jee Young Jeong, Sang-Hee Choi	63 rd Annual Meeting of Korean Radiological Society, Seoul, Korea, October 22- October 24, 2007
presentation	Initial experience of image-guided intramuscular botulinum toxin injection in patients with idiopathic cervical dystonia	Young Cheol Yoon, In Ho Lee. Jong Won Kwon, Jee Young Jeong, Sang-Hee Choi.	63 rd Annual Meeting of Korean Radiological Society, Seoul, Korea, October 22- October 24, 2007
	Advantage & Disadvantage of Ultrasound to MR in Musculoskeletal System	KH Cho	The Sports Medicine & Rehabilitation Education Series, Polytech. University, Hong Kong, Dec, 2007
	Novel multifunctional PHDCA/PEI nano-drug carriers for simultaneous magnetically-targeted cancer therapy and diagnosis using magnetic resonance imaging	Seo SB, Yang J, Hyung W, Cho EJ, Song Y, Yoon HG, Suh JS, <i>Huh YM, Haam S</i>	<i>Nanotechnology</i> 2007, 18, 1-8. (IF 3.03)
	Hybrid Nanoparticles for Magnetic Resonance Imaging of Target-Specific Viral Gene Delivery	Huh YM, Lee ES, Lee JH, Jun Y, Kim PH, Yun CO, Kim JH, <u>Suh JS</u> , Cheon J	<i>Adv. Mater.</i> 2007, 19, 3109. (IF; 7.89)
presentation	Perineural Air Injection as Thermal Protection Method of Sciatic Nerve during RF Ablation: An Experimental Study in Rabbits	Jee Young Jeong, Young Cheol Yoon, Jong Won Kwon, Sang-Hee Choi, Eun Yoon Cho, Bong-Keun Choi	The 93 rd Scientific Assembly and Annual Meeting, Radiological Society of North America, McCormick Place, Chicago, Illinois, November 25-30, 2007
presentation	Isotropic Shoulder MR Arthrography: Comparison to Conventional MR Arthrography in the Diagnosis of Labral Lesions	Ji Young Jeong, Young Cheol Yoon, Jong Won Kwon, Sang-Hee Choi,	The 93 rd Scientific Assembly and Annual Meeting, Radiological Society of North

	Using a 3-Tesla MR	Bong-Keun Choi	America, McCormick Place, Chicago, Illinois, November 25-30, 2007
presentation	Modic type I Change versus Early Infectious Spondylitis: Diagnostic Clues for the Differentiation	Sang-Hee Choi, Jong Won Kwon, Young Cheol Yoon, Ji Young Jeong, Bong-Keun Cho	The 93 rd Scientific Assembly and Annual Meeting, Radiological Society of North America, McCormick Place, Chicago, Illinois, November 25-30, 2007
presentation	Pelvic Bone Complications Following Radiation Therapy of Uterine Cervix Cancer	Sang-Hee Choi, Jong Won Kwon, Young Cheol Yoon, Ji Young Jeong	The 93 rd Scientific Assembly and Annual Meeting, Radiological Society of North America, McCormick Place, Chicago, Illinois, November 25-30, 2007
구연	Partial-thickness rotator cuff tears: MR arthrography with arthroscopic correlation	김민성, 천경아, 김영주	93rd scientific assembly and annual meeting 20071125 Chicago
	Partial Articular Supraspinatus Tendon Avulsions (PASTA): Reliability and Accuracy of Diagnosis with MR Arthrography (scientific paper)	Lee SJ, Jee WH, Jeong HS, Lee SY, Kim YS, Kim JM	93rd Scientific Assembly and Annual Meeting of Radiological Society of North America 2007
exhibit	Ultrasonography of nerves about the elbow: correlation with MR imaging	Jung GW, Jee WH, Jeong HS, Ryu KN	93rd Scientific Assembly and Annual Meeting of Radiological Society of North America 2007
poster/exhibit	Spinal infection or limitations? Radiologic Judgment	Hong SH, <u>Choi JA</u> , Lee JW, Kim NR, Jun WS, Choi J, et al	93rd Scientific Assembly and Annual Meeting. Nov 25-30, 2007. Chicago, USA.
poster/exhibit	MR imaging of interesting but rarely described muscle disorders	Kim NR, Hong SH, <u>Choi JA</u> , Jun WS, Lee JW, Choi J, et al	93rd Scientific Assembly and Annual Meeting. Nov 25-30,

t			2007. Chicago, USA.
pres enta tion	Spreading epidural hematoma and posterior subcutaneous edema: MRI signs of posterior column injury in spinal burst fracture.	Kim NR, Hong SH, Choi JY, Chang BS, Lee JW, Kang HS	RSNA 2007
pres enta tion	Effectiveness of transforaminal epidural steroid injection by using a preganglionic aApproach: a prospective randomized controlled study	Lee JW, Chung HS, Kim SH, Hong SH, Kang HS	RSNA 2007
pres enta tion	Diffusion tensor imaging in acute transverse myelitis	Lee JW, Park KS, Kim JH, Hong SH, Kang HS	RSNA 2007
Scie ntific pape r	Comparision of T2 Relaxation Changes in Articular Cartilage after Running between Young and Old Amateur Athletes	신충희, 차장규, 박재성, 이범하, 박성진, 이혜경	2007년 RSNA
구연	Spreading Epidural Hematoma and Deep Subcutaneous Edema: Indirect MRI Signs of Posterior Ligamentous Complex Injury in Thoracolumbar Burst Fractures	Na Ra Kim, Sung Hwan Hong, Ja-Young Choi, Bong-Soon Chang, Joon Woo Lee, Jae Sung Myung, Sung Gyu Moon, Heung Sik Kang	2007년 RSNA
전시	Staging of Osteochondritis Dissecans of the Knee: Review of MRI Features, Arthroscopic Findings and Postoperative Images	Na Ra Kim, Ja-Young Choi, Sung Hwan Hong, Woo Sun Jun, Joon Woo Lee, Jung-Ah Choi, Heung Sik Kang	2007년 RSNA
전시	An analysis and classification of image artifacts which appears in PACS environment and their preventive method	Sung DW, Ryu KN, Kang HD, Kim YH	RSNA 2007. 12
구연	Multidetector CT Findings of Right Intrahepatic Portosystemic Venous Shunt	Yelim Kim, M.D., Cheol Min Park, M.D., Kyeong Ah Kim, M.D. Jae Woong Choi, M.D., Jongmee Lee, M.D., Chang Hee Lee, M.D	ACAR (Asian Congress of Abdominal Radiology) , 2007
	2008	Quantitative Assessment of	Lee SH, Suh JS, Shin Korean J Radiol. 2008

		Synovial Vascularity Using Contrast-Enhanced Power Doppler Ultrasonography: Correlation with Histologic Findings and MR Imaging Findings in Arthritic Rabbit Knee Model.	MJ, Kim SM, Kim N, Suh SH.	Jan-Feb;9(1):45-53. (IF; 1.48)
		Novel hyaluronic acid (HA) coated drug carriers (HCDCs) for human breast cancer treatment	Hyung W, Ko H, Park J, Lim E, Park SB, Park YJ, Yoon HG, Suh JS, Haam S, Huh YM.	Biotechnol Bioeng. 2008 Feb 1;99(2):442-54. (IF;2.99)
논문		Spindle Cell Lipoma of the Posterior Axilla: A Case Report	Jee Young Lee, M.D., Kyung Jin Suh, M.D.2, Sang Yoon Kim, M.D	J Korean Radiol Soc 2008;59:45-49
논문		Vascular Tumors, Chondroid-osseous Tumors, Tumors of Uncertain Differentiation: An Update Based on the New WHO Soft Tissue Classification	Kyung Jin Suh.	J of Korean Bone & Joint Tumor 2008; 14(2):110-116
논문		Adipose Tumor, Fibroblastic/Myofibroblastic Tumors, So-called Fibrohistiocytic Tumors, Smooth Muscle Tumors, Pericytic Tumors and Skeletal Muscle Tumors: An Update Based on the New WHO Soft Tissue Classification	Kyung Jin Suh	J of Korean Bone & Joint Tumor 2008; 14(1):1-9
논문		Usefulness of Coronal MR Image in Diagnosis of Foraminal and Extraforaminal Disc Herniation	Myung Ho Kim, Kyung Jin suh, Jee Young Lee, Sang Hyuk Min, Hyun Youl Yoo	Journal of Korean Spine Surg. 2008; 15(3): 165-173
논문		유방에 발생한 샘낭암종: 1예보고.	김순. 서경진. 장태정	동국의학 2008; 15(1): 269-274
		"The role of ultrasound in musculoskeletal tumors	KH Cho	The 10 th Asian Musculoskeletal Society & the 1 st Indonesian Musculoskeletal Tumor Society, Hyatt regency Surabaya-Indonesia Hotel, Jan-

				25-2008
		Enhancement of magnetic resonance contrast effect using ionic magnetic clusters	Seo SB, Yang J, Lee TI, Chung CH, Song YJ, Suh JS, Yoon HG, <i>Huh YM, Haam S.</i>	J Colloid Interface Sci. 2008 Mar 15;319(2):429-34.. (2.233)
		Synthesis of water soluble PEGylated magnetic complexes using mPEG-fatty acid for biomedical applications	Lim EK, Yang J, Park MY, Park J, Suh JS, Yoon HG, Huh YM, Haam S.	Colloids Surf B Biointerfaces. 2008; 64(1): 111-7 (IF;1.78)
		Hollow Silica Nanocontainers as Drug Delivery Vehicles.	Yang J, Lee J, Kang J, Lee K, Suh JS, Yoon HG, <i>Huh YM, Haam S</i>	Langmuir 2008 Apr 1;24(7):3417-3421. (IF 3.9)
		Multifunctional Nanoparticles for Photothermally Controlled Drug Delivery and Magnetic Resonance Imaging Enhancement	Park H, Yang J, Seo SB, Kim K, Suh J, Kim D, Haam S, <i>Yoo KH</i>	Small 2008;4(2);192-196. (IF; 6.024)
		MR Findings of Skeletal Muscle Lymphoma according to the Types of Occurrence	박혜정,지원희,이상훈,김여주,박정미,박성환	Radiological Society of North America
		Comparative study of fluorodeoxyglucose positron emission tomography and magnetic resonance imaging for the detection of spinal bone marrow infiltration in untreated patients with multiple myeloma	Hur J, <i>Yoon CS</i> , Ryu YH, Yun MJ, Suh JS.	Acta Radiol. 2008 May;49(4):427-35
		Fluorescent magnetic nanohybrids as multimodal imaging agents for human epithelial cancer detection	Yang J, Lim EK, Lee HJ, Park J, Lee SC, Lee K, Yoon HG, Suh JS, <i>Huh YM, Haam S</i>	Biomaterials. 2008 Jun;29(16):2548-55
		Multifunctional magnetic gold nanocomposites: Human epithelial cancer detection via magnetic resonance imaging and localized synchronous therapy	Lee J, Yang J, Ko H, Oh SJ, Kang J, Son JH, Lee K, Lee SW, Yoon HG, Suh JS, <i>Huh YM, Haam S</i>	ADVANCED FUNCTIONAL MATERIALS 2008;18 (2): 258-264 (IF; 6.77)
		Magnetic sensitivity enhanced novel fluorescent magnetic silica nanoparticles for biomedical applications	Yang J, Lee J, Kang J, Chung CH, Lee K, Suh JS, Yoon HG, <i>Huh YM, Haam S.</i>	<i>Nanotechnology</i> 2008;19 (7): Art. No. 075610. (IF 3.03)
		Enhancement of cellular binding efficiency and cytotoxicity using polyethylene glycol base triblock	Yang J, Cho EJ, Seo S, Lee JW, Yoon HG, Suh JS, <i>Huh YM,</i>	J Biomed Mater Res A. 2008, 84A(1), 273-280. (IF; 2.49)

	copolymeric nanoparticles for targeted drug delivery	Haam S.	
출판 도서(번역 물)	자기공명영상의 역사와 기초물리학	서경진	pp17-22 IN 자기공명영상학. 대한자기공명외과학회. 일조각 초판발행 2008. 10. 10. ISBN 978-89-337-0548-3 93510 CIP 제어번호 2008002996
출판 도서(번역 물)	제4장 팔꿈치 초음파검사	서경진. 이재혁	pp102-132 IN 근골격계 초음파검사의 기초와 이해.2008. 10 .20 1 판인쇄. 한솔의학서적. ISBN 978-89-959616-9-8 Jon A. Jacobson, M.D. . Fundamentals of Musculoskeletal Ultrasound. Saunders ISBN-13: 978-1-4160- 3593-0 ISBN-10:1-4160-3593- 1 RC925.7J33 2008 616.7'07543-dc22
출판 도서(번역 물)	자기공명영상의 이해	서경진	한트 쉴드저, 쉐링, 독일 (106 페이지) MRI Made Easy in Schild HH. MRI Made Easy, (Scherling, German)
	Smart nanoprobe for ultrasensitive detection of breast cancer via magnetic resonance imaging	Lee, J., Yang, J., Seo, S.-B., Ko, H.-J., <u>Suh, J.-S.</u> , Huh, Y.-M., Haam, S	Nanotechnology, Vol. 19, No. 48, art. no. 485101, 2008
	In situ detection of live cancer cells by using bioprobes based on Au nanoparticles	Yang J, Eom K, Lim EK, Park J, Kang Y, Yoon DS, Na S, Koh EK, Suh JS, Huh YM, Kwon TY, and Haam S	Langmuir , 2008; 24(21): 12112-5
	Ankle MRI for anterolateral soft	Choo HJ, Suh JS,	Korean J Radiol ,

		tissue impingement: increased accuracy with the use of contrast-enhanced fat-suppressed 3D-FSPGR MRI	Kim SJ, Huh YM, Kim MI, and Lee JW	2008; 9(5): 409-15
		Nanohybrids <i>via</i> a polycation-based nanoemulsion method for dual-mode detection of human mesenchymal stem	Seo SB, Yang J, Lee ES, Jung Y, Kim K, Lee SY, Kim D, Suh JS, Huh YM, Haam S	<i>J. Mater. Chem.</i> , 2008, 18 , 4402-4407 (Cover article)
		Magnetic resonance imaging findings of surgically proven medial meniscus root tear: tear configuration and associated knee abnormalities	Lee YG, Shim JC, <u>Choi YS</u> , Kim JG, Lee GJ, Kim HK	J Comput Assist Tomogr 2008;32(3):452-457
		MR imaging of cartilage repair in the knee and ankle	<u>Choi YS</u> , Potter HG, Chun TJ	Radiographics 2008;28:1043-1059
전시		Superficial Soft-Tissue Masses of the Extremities: Differential Considerations on Ultrasound	Na Ra Kim, Sung Hwan Hong, Ja-Young Choi, Joon Woo Lee Jung-Ah Choi, Heung Sik Kang	2008 ECR
Presentations		MR imaging in lumbar spinal stenosis: prediction of surgical outcome	Hong SH, Lee JW, Yeom JS, Park KW, Choi JY, Kim NR, Kang HS	. ECR 2008
전시		MR Imaging Findings Of Medial Meniscal Root Tears: Tear Configuration, Diagnostic Accuracy, And The Associated Abnormalities	Shim Jae-Chan, Kim Jin Goo, Kim Young-Hwa, Lee Ghi Jai, Kim Ho Kyun, Suh Jung Ho	ECR 2008 년
		Clinical outcome of osteosarcoma-Catholic University experience	정양국,강용구,이승구,김형민,박원종,이안희,박정미	7th APMSTS meeting
		Soft tissue sarcomaspresented with hematomas	정양국,강용구,이승구,박원종,이안희,박정미,조현민	7th PAMSTS meeting
ecture		"imaging of bone and joint infection"	KH Cho	Santo Tomas University Medical School, Manila, PHILIPPINES, Sep, 2008
oral presentations		Clinical efficacy of ultrasound-guided subacromial steroid injection in adhesive capsulitis of	<u>Choi JA</u> , Oh JH, Kim Y, Choi JY, Hong SH, Kang HS	12th Asian Oceanian Congress of Radiology 2008. 10.

tions		the shoulder: comparison with intra-articular steroid injection.		24-28. Seoul, Korea
oral presentations		Posteroinferior labral cleft or irregularity on direct CT arthrography using multidetector CT (MDCT) with arthroscopic correlation: Is this a normal variant?	Lee GY, <u>Choi JA</u> , Oh JH, Choi JY, Hong SH, Kang HS	12th Asian Oceanian Congress of Radiology 2008. 10. 24-28. Seoul, Korea
poster/exhibit		Osteoid osteoma: from simple to challenging imaging features	Chai JW, Hong SH, Choi JY, Lee JW, Choi JA, Kang HS	12th Asian Oceanian Congress of Radiology 2008. 10. 24-28. Seoul, Korea
poster/exhibit		Bone marrow edema around the hip joint: MR imaging assessment and differential diagnosis	Hong SH, Choi JY, Lee JW, <u>Choi JA</u> , Chai JW, Kang HS.	12th Asian Oceanian Congress of Radiology 2008. 10. 24-28. Seoul, Korea
presentation		MR classification of bone marrow Langerhans' cell histiocytosis based on histopathologic phase	Moon TY, Lee IS, Lee G	The 12th AO CR, Seoul, Korea, (2008.10.27)
전시		Multiple myeloma demonstrated as extraosseous soft tissue masses	김정현, 박정미, 최정은, 민창기	The 12th Asian Oceanian Congress of Radiology
좌장		Session Title: Shoulder, Miscellaneous	Deuk Lin Choi MD, Christian W.A. Pfirrmann MD	AO CR 2008 Seoul 2008.10.26(Sun) 10:30-12:00
Exhibition		Metatarsophalangeal joints: normal MR imaging anatomy and pathology	<u>Sun Choi</u> , Seok-Hoon Lee, Hye-Jin Yang, Hollis G. Potter, Tong Jin Chun, Seoung-Oh Yang	AO CR 2008
presentation		MR imaging evaluation of lateral collateral ligaments in chronic ankle instability	Seok-Hoon Lee, <u>Yun Sun Choi</u> , Hye-Jin Yang, Ki Won Young, Kyung-Tae Lee, Chang-Yul Han.	AO CR 2008
presentation		MR imaging evaluation of reparative cartilage 1-Year after autologous chondrocyte implantation for osteochondral Lesions of talus	<u>Yun Sun Choi</u> , Hye-jin Yang, Mi-hye Im, Jin-su Kim, Kyung-tae Lee, Hollis G. Potter	AO CR 2008
전시		Fat-containing soft tissue tumors: imaging with emphasis on ultrasonographic findings	<u>HJ Choo</u> , SJ Lee, KJ Seo, SM Lee, YH Lee, MH Kim	12th Asian Oceanian Congress of Radiology(AO CR) ,

				Seoul, Korea, 2008, Oct 24.
전시		Kimura's disease in the soft tissue of the upper extremity: ultrasonographic and MR findings	SJ Lee, <u>HJ Choo</u> , YM Park, CK Eun, SS Han, SM Lee.	12th Asian Oceanian Congress of Radiology(AOCR) , Seoul, Korea, 2008, Oct 24.
구연		MR arthrography of partial rotator cuff tears: diagnosis of different types with arthroscopic correlation	천경아,김민성,김영주	12th asian oceanian congress of radiology 20081026 COEX, Seoul, Korea
포스터		Bone marrow edema of the knee: differential diagnosis of MR imaging	장진희,한혜정,천경아	12th asian oceanian congress of radiology 20081026 COEX, Seoul, Korea
Oral presentation		MR classification of bone marrow Langerhans' cell histiocytosis based on histopathologic phase	Moon TY, Lee IS, Lee G	The 12th AOCR, Seoul, Korea, 2008.10.27)
구연		Quantitative renal blood flow measurement with dynamic perfusion CT: comparison with blood flowmeter and laser Doppler flowmeter	교신:이상용, 제1:강경표, 김원, 고규영, 박성광,	12th Asian Oceanian Congress of Radiology 서울 코엑스 2008
구연		Ultrasonography of the knee: emphasis on position and stress applied to the knee joint	교신:이상용, 제1:이주홍, 서정환,	12th Asian Oceanian Congress of Radiology 서울 코엑스 2008
구연		High resolution micro CT: evaluation of treatment response in surgery-induced ischemic necrosis of the femoral head in rats	교신:이재아, 제1:김정렬, 장규윤, 윤권하, 이상용,	12th Asian Oceanian Congress of Radiology 서울 코엑스 2008
		Dynamic ultrasonography in musculoskeletal system Ultrasound as a problem-solving tool in musculoskeletal system	KH Cho	AOCR (Asian-Oceanian Congress of Radiol), KOREA, Oct, 2008
presentation		Posteroinferior labral cleft at direct CT arthrography of the shoulder by using multidetector CT: is this abnormal variant	Guen Young Lee ¹ , Jung-Ah Choi ¹ , Joo Han Oh ³ , Ja-Young Choi ² , Sung Hwan Hong ² , Heung Sik Kang ^{1,2} .	2008 AOCR
전시		Fat-containing soft tissue	HJ Choo, <u>SJ Lee</u> , KJ	12th Asian Oceanian

	tumors:imaging with emphasis on ultrasonographic findings	Seo, SM Lee, YH Lee, MH Kim	Congress of Radiology(AOCR) , Seoul, Korea, 2008, Oct 24.
전시	Kimura's disease in the soft tissue of the upper extremity: ultrasonographic and MR findings	<u>SJ Lee</u> , HJ Choo, YM Park, CK Eun, SS Han, SM Lee	12th Asian Oceanian Congress of Radiology(AOCR) , Seoul, Korea, 2008, Oct 24.
전시	avulsion fractures about the knee: review of clinical presentations and imaging findings	정선관,임세웅,김혜원,이영환,최시성,노병석	12th Asian Oceanian Congress of Radiology 2008.10.24 - 2008.10.28 12th Asian Oceanian Congress of Radiology Abstract book 352 ~ 352 대한민국
구연	Macrophage imaging for vulnerable atherosclerotic plaqu using X-ray computed tomography enhanced with gold nanoparticles contrast agent	박성훈,김선희,전홍영,정선관,김현수,윤권하	12th Asian Oceanian Congress of Radiology abstract book 12th Asian Oceanian Congress of Radiology abstract book 143 ~ 143 대한민국
구연	MRI detection of lymphnode metastasis in mouse melanoma models using thermally cross-linked superparamagnetic ironoxide nanopartilces	임세웅,김혜원,김현수,정선관,전홍영,윤권하	12th Asian Oceanian Congress of Radiology 2008.10.24 - 2008.10.28 157 ~ 158 대한민국 12th Asian Oceanian Congress of Radiology abstract book
구연	Visualization of leptin effect on angiogenesis using Gd-DTPA-anti-VEGFR2 antibody enhanced MRI in a Matrigel mous model	김무상,윤홍화,전홍영,박성훈,정선관,윤권하	12th Asian Oceanian Congress of Radiology 2008.10.24 - 2008.10.28 158 ~ 158 대한민국 12th Asian Oceanian Congress of Radiology abstract book

Poster	MR classification of bone marrow Langerhans' cell histiocytosis based on histopathologic phase.	Moon TY, Lee IS, Lee JW.	ISS2008, The Taj Palace Hotel, New Delhi, India (2008.10.29)
전시	Lipomatosis of median nerve: a case report	정선관, 박성훈, 김혜원, 이영환	35th Annual Radiology Refresher course, International 인도 ISS New Delhi India 2008.10.30 (23 ~ 23)
Exhibition	MR imaging of metatarsophalangeal joints: normal anatomy and pathology	Yun Sun Choi, Seok-Hoon Lee, Hye-Jin Yang, Hollis G. Potter, Han CY	RSNA 2008 Educational Exhibition
전시	Epidural cystic lesions of the spine	SJ Lee, HJ Choo, EJ Lee, NS Park, YM Park, JR Juhn, SS Han CK Eun.	Radiological Society of North American(RSNA) , Chicago, USA 2008, Nov 30
전시	Radiological Diagnosis of Osteoid Osteoma: From Simple to Challenging	Jee Won Chai, Sung Hwan Hong, Ja-young Choi, Joon Woo Lee, Jung-Ah Choi, Heung Sik Kang	RSNA 2008
poster	Lateral Epicondylitis: Diagnosis with High Resolution Ultrasonography	이민희(순천향부천), 차장규, 박성진, 백상현, 박재성, 김병성	2008년 RSNA
presentation	Posteroinferior labral cleft at direct CT arthrography of the shoulder by using multidetector CT: is this abnormal variant?	Guen Young Lee ¹ , Jung-Ah Choi ¹ , Joo Han Oh ³ , Ja-Young Choi ² , Sung Hwan Hong ² , Heung Sik Kang	2008 RSNA
presentation	Dural tear in the spinal burst fracture; predictable factors on MRI	In Sook Lee ¹ , Jung Sub Lee ² , Hak Jin Kim ¹ , Yeon Joo Jeong ¹ , Tae-Yong Moon	RSNA 2008
exhibit	Soft Tissue Masses Showing Low Signal Intensities on T2-Weighted Image	¹ In Sook Lee, M.D., ¹ Jin You Kim, M.D., ⁴ Kil Ho Cho, M.D., ⁵ Sung-Moon Lee, M.D., ⁶ Young Hwan	RSNA 2008

			Lee, M.D., ² Kyung-Un Choi, M.D., ³ Jeung Il Kim, M.D., ¹ Tae-Yong Moon, M.D	
oral presentations		Fatty degeneration of rotator cuff muscles after surgical repair: Are the current measuring systems of fatty degeneration reliable?	<u>Choi JA</u> , Oh JH, Kim YJ, Kim SH, Hong SH, Kang HS	94 th Scientific Assembly and Annual Meeting of the Radiological Society of North America, 2008 11. 30 - 12. 5., Chicago, IL, USA
oral presentations		Posteroinferior labral cleft or irregularity on direct CT arthrography using multidetector CT (MDCT) with arthroscopic correlation: Is this a normal variant?	Lee GY, <u>Choi JA</u> , Oh JH, Choi JY, Hong SH, Kang HS	94 th Scientific Assembly and Annual Meeting of the Radiological Society of North America, 2008 11. 30 - 12. 5., Chicago, IL, USA
poster/exhibitions		Osteoid osteoma: from simple to challenging imaging features	Chai JW, Hong SH, Choi JY, Lee JW, <u>Choi JA</u> , Kang HS	94 th Scientific Assembly and Annual Meeting of the Radiological Society of North America, 2008 11. 30 - 12. 5., Chicago, IL, USA
poster/exhibitions		Clinical efficacy of ultrasound-guided subacromial steroid injection in adhesive capsulitis of the shoulder: comparison with intra-articular steroid injection.	<u>Choi JA</u> , Kim YJ, Oh JH, Park SY, Hong SH, Kang HS, Oh CH	94 th Scientific Assembly and Annual Meeting of the Radiological Society of North America, 2008 11. 30 - 12. 5., Chicago, IL, USA
presentation		Isotropic MR Imaging of Shoulder: A Prospective Study with Indirect MR Arthrography.	Young Cheol Yoon, Dae Kun Oh, Jee Young Jung, Jong Won Kwon, Sang-Hee Choi, Soho Bae	SSJ17-02. The 94 th Scientific Assembly and Annual Meeting, Radiological Society of North America, McCormick Place, Chicago, Illinois, November 31- December 6, 2008
presentation		Three-dimensional Isotropic Proton Density-weighted MR Imaging of the Knee: A	Soohe Bae, Jee Young Jung, Young Cheol Yoon, Jong	SSG12-03 The 94 th Scientific Assembly and Annual Meeting,

		Comparison to Two-dimensional MR Imaging for the Diagnosis of Internal Derangement of the Knee Using 3-Tesla MR	Won Kwon	Radiological Society of North America, McCormick Place, Chicago, Illinois, November 31-December 6, 2008
exhibit		MR Findings of Skeletal Muscle Lymphoma according to the Types of Occurrence	Park HJ, Jee WH, Lee SH, Kim YJ, Park JM, Park SH	94th Scientific Assembly and Annual Meeting of Radiological Society of North America 2008
exhibit		Follow-up MR Features in Autologous Chondrocyte Implantation in Tibiofemoral Joint	Kim MS, Jee WH, Jung GW, Jeong HS, Kim JM	94th Scientific Assembly and Annual Meeting of Radiological Society of North America 2008
전시		Serial correlation between ultrasonographic and pathologic findings of intramuscular hemorrhage in the experimental rabbits	Ko KL, Bae MS, Choi JH, Lee DH, Park JS, Ryu KN	RSNA 2008. 12
구연		Incidence of Giacomini vein and its association with lower extremity venous insufficiency	Kwon SH, Park SC, Oh JH, Lee DH, Ryu KN	RSNA 2008. 12
	2009	Nanograting-based Plasmon enhancement for total internal reflection fluorescence microscopy of live cells	Kim K, Kim DJ, Cho EJ, Suh JS, Huh YM, Kim D	Nanotechnology 2009, Jan,;20(1):15202
lecture		Imaging of heel pain Imaging of hip pain	KH Cho	The 10 th Asian Musculoskeletal Society, Feb-07, 2009
논문		Femoral Nerve Palsy caused by Iliopsoas Bursitis Associated with Osteonecrosis of the Femoral Head: A Case Report	Phil Hyun Chung, M.D., Chung Soo Hwang, M.D., Suk Kang, M.D., Jong Pil Kim, M.D., Young Sung Kim, M.D., Soo Ma Kim, M.D., Kyung Jin Seo, M.D.	The Journal of Korean Hip Society 2009; 21(1): 82-85 게제확정일: 2009. 2. 16
		The usefulness of virtual MR arthroscopy as an adjunct to conventional MR arthrography in	Song HT, Huh YM, Kim S, Kim SJ, Suh JS	AJR Am J Roentgenol. 2009 Apr;192(4):W149-55

	detecting anterior labral lesions of the shoulder.		
논문	엄지발가락 종자골의 골괴사: 증례보고	서경진. 김순. 김성우	동국의학 2009; 15(2): 216-221
	In vivo magnetic resonance imaging of injected mesenchymal stem cells in rat myocardial infarction; simultaneous cell tracking and left ventricular function measurement.	Kim YJ, Huh YM, Choe KO, Choi BW, Choi EJ, Jang Y, Lee JM, <u>Suh JS</u>	Int J Cardiovasc Imaging 2009 Apr;25 Suppl 1:99-109. 2009 Jan 9. [Epub ahead of print]
	Nanoparticle-enabled terahertz imaging for cancer diagnosis	Oh SJ, Kang J, Maeng I, Suh JS, Huh YM, Haam S, Son JH	Opt. Express 2009;17:3469-3475
	Nanomechanical <i>In Situ</i> Monitoring of Proteolysis of Peptide by Cathepsin B	Kwon T, Park J, Yang J, Yoon DS, Na S, Kim CW, Suh JS, Hun YM, Haam S, Eom K	PLoS One 2009; 4(7): e6248; online 2009 July 16. doi: 10.1371/journal.pone.0006248.
	Controlled aggregates of magnetite nanoparticles for highly sensitive MR contrast agent.	Jeon B-S; Cho E-J; Yang H-M; Suh J-S; Huh Y-M; Kim J-D	Journal of nanoscience and nanotechnology 2009; 9(12):7118-22
	Synthesis of gold nanorod-embedded polymeric nanoparticles by a nanoprecipitation method for use as photothermal agents	Kim E, Yang J, Choi J, Suh JS, Huh YM, Haam S.	Nanotechnology. 2009 Sep 9;20(36):365602
	Synthesis and characterization of fluorescent magneto polymeric nanoparticles (FMPNs) for bimodal imaging probes.	Park J, Yang J, Lee J, Lim EK, Suh JS, Huh YM, Haam S	J Colloid Interface Sci. 2009 Dec 15;340(2):176-81 Epub 2009 Aug 15.
	Prognostic factors in liposarcomas: a retrospective study of 52 patients	정양국,강용구,이안희,박정미	ISOLS/MSTS combined meeting
	Gold-layered calcium phosphate plasmonic resonants for localized photothermal treatment of human epithelial cancer	Kang J ,Yang J, Lee J, Oh SJ, Moon S, Lee HJ, Lee SC, Son J, Kim DH, Lee K, Suh JS, Huh YM, Haam S	<i>J. Mater. Chem.</i> , 2009, 19, 2902 - 2905, DOI: 10.1039/b822835c
	Smart Drug-Loaded Polymer Gold Nanoshells for Systemic and Localized Therapy of Human	Yang J, Lee J, Kang J, Oh SJ, Ko H, Son J, Lee K, Suh JS, Huh	Adv. Mater. 2009, 21:1-4

		Epithelial Cancer.	<i>YM, Haam S</i>	
		Cancer-Targeted MR molecular imaging.	Song HT, Suh JS	J Korean Med Assoc. 2009;52(2):121-124.
포스터		Paricalcitol suppresses TNF-a induced fractalkine expression in endothelial cells through regulation of NFkB activity	교신:박성광, 제1:김원, 강경표, 이상용, 김덕훈, 정유진, 이애신, 이정은, 이식, 강성귀,	Internatinal Society of Nephrology 밀라노
포스터		COMP-angiopoietin-1 ameliorates chlorhexidine-induced sclerosing encapsulating peritonitis through regulation of peritoneal inflammation	교신:김원, 제1:박성광, 강경표, 이태환, 김덕훈, 정유진, 이애신, 이정은, 이식, 이상용, 강성귀	Internatinal Society of Nephrology 밀라노
		MR Imaging Features of Skeletal Muscle Lymphoma (scientific paper, corresponding author)	Chun CW, Jee WH, Park HJ, Lee SH, Kim YJ, Park JM, Park SH	European Congress of Radiology 2009
전시		Nerve root enhancement on contrast-enhanced MR: Differential considerations	HJ Choo, <u>SJ Lee</u> , MH Kim	European Congress of Radiology(ECR) , Vienna, Austria, 2009, Mar 9
전시		Pilomatricoma: Diagnostic value of ultrasound	HJ Choo, YH Lee, JH Lee, <u>SJ Lee</u> , MH Kim, MK Oh	European Congress of Radiology(ECR) , Vienna, Austria, 2009, Mar 9
		MR Imaging Features of Skeletal Muscle Lymphoma	전장우,지원희,박혜정, ,이상훈,김여주,박정미,박성환	European Congress of Radiology
oral presentations		Differentiating high-grade from low-grade chondrosarcoma with MR imaging	Yoo HJ, Hong SH, Choi JY, Moon S, Kim NR, Lee J, <u>Choi JA</u> , Kang HS	2009 European Congress of Radiology March 6-10, 2009. Vienna, Austria
poster/exhibi t		Subacromial spur in patients with rotator cuff tears: Morphological classification and clinical significance	<u>Choi JA</u> , Oh J, Lee H, Kang HS	2009 European Congress of Radiology March 6-10, 2009. Vienna, Austria
poster/exhibi t		Ultrasound of the shoulder: Normal anatomy, pathology, and pitfalls with MR and CT arthrographic and arthroscopic correlation	<u>Choi JA</u> , Oh J, Kang HS	2009 European Congress of Radiology March 6-10, 2009. Vienna, Austria

	Musculoskeletal radiology in Asia: Outlook to the future	KH Cho	The 16th ESSR (European Congress of the European Society of Musculoskeletal Radiology), Genoa, Italy, Apr 1-3, 2009
전시	Atypical appearance of brown tumors: emphasis on MR imaging features	Mi Sook Sung, Won S Hong, Myung H Chung	ESSR 2009
전시	Multifocal skeletal cystic tuberculosis: a case report	이영환, 김혜원, 박성훈	이탈리아 ESSR 16th annual congress of the European society of musculoskeletal radiology 18 ~ 18 2009.06.11
exhibit	Sagittal Proton-weighted TSE SPIR with 1.5 mm Slice-thickness at 1.5-T Knee MRI. (scientific exhibit)	Lee JH, Jee WH, Lee SY, Kim SK, Kim JM	European Society for Magnetic Resonance in Medicine and Biology 2009
전시	Sonographic evaluation of the painful elbow	MH Kim, HJ Choo, <u>SJ Lee</u>	American Roentgen Ray Society(ARRS) 2009 annual meeting, Boston, USA, 2009, Apr 26.
구연 전시	Granulocytic sarcoma of spine :MR imaging and Clinical review	박정미, 석지현, 김선기, 최정은	2009 ARRS
포스터	The study of motor activation in patients with cerebellar atrophy (due to long term antiepileptic drug medication) by fMRI	제1:정경호, 황승배, 한영민, 이상용,	European Society of Neuroradiology Greece Athens 2009
구연	central hypoechogenic line in the ultrasonographic image of the meniscus	교신:이상용, 제1:김종수,	(Wfumb2009) 호주 2009
	Ruptured Baker's cyst: Assessment of ultrasonographic findings	Kwon ST	WFUMB 2009. 1337, Sydney, Australia
presentation	Comparison of high resolution ultrasonographic imaging with water bath immersion technique and MRI with microscopic coil in the evaluation of hand	Ik Yang	WFUMB 2009 Sydney, Australia
poster	Radiologic features of lipomatous tumors as a periarticular soft	Ik Yang	WFUMB 2009 Sydney, Australia

		tissue mass		
		Differentiation between Grade 3 and Grade 4 Articular Cartilage Defects of the Knee: Fat-suppressed intermediate-weighted versus Fat-suppressed 3D Gradient-echo MR Imaging (scientific poster).	Jee WH, Lee SY, Cho SM, Kim JM	36th International Skeletal Society Annual Meeting 2009
Exhibition		Imaging findings of painful accessory ossicles around the small joints	<u>Yun Sun Choi</u> , Hye-jin Yang, Mi-hye Lim, Seok-Hoon Lee, Tong Jin Chun, Seoung-Oh Yang	International Skeletal Society 2009 Educational Exhibition
전시		Imaging of the Hemangioma in the soft tissue and bone: revisited	Mi Sook Sung, Myung H chung	ISS2009
oral presentations		In vitro study on contrast subtraction using dual-energy CT arthrography in pig joints	Chai JW, <u>Choi JA</u> , Koo KH, Choi JY, Hong SH, Kang HS	2009 International Skeletal Society Meeting 2009 Aug 31-Sept 5, 2009. Washington DC, USA
poster/exhibition presentations		Ten types of Superior Labral Anteroposterior Tears (SLAP): Diagnostic performance of MDCT arthrographywith arthroscopic correlation.	Kim Y , <u>Choi JA</u> , Oh JH, Kang HS	2009 International Skeletal Society Meeting 2009 Aug 31-Sept 5, 2009. Washington DC, USA
전시		Shoulder & Elbow Injuries in Throwing Athletes: MR Imaging Findings	Na Ra Kim, Sung Gyu Moon, Jin Ho Hwang, Jin-Young Park, Sang-Hoon Lhee	2009 ISS
전시		Tuberculosis arthritis, osteomyelitis and spondylitis : Pictorial review	이승훈,홍석주,김백현,강은영,강창호,이근영	ISS 2009 워싱턴
전시		MR findings of various hematologic malignancies involving spines	이승훈,홍석주,김백현,강은영,강창호,이근영	ISS 2009 워싱턴
		Ultrasound of hand and wrist: fracture" "Common pathology of hip pain: US evaluation	KH Cho	The 19th Annual Conference of Musculoskeletal Ultrasound Society, Barcelona, Spain, Oct 1-4, 2009

전시	Imaging Findings of Subungual tumors	<u>SJ Lee</u> , HJ Choo, KH Cho, YH Lee, S Lee, YM Park	Radiological Society of North American(RSNA) , Chicago, USA 2009, Nov 29
poster	Practical Application of IDEAL Imaging Technique in Minimizing Metallic Artifacts	차장규,김동훈,이범하,박성진,이선정,이영주	2009년 RSNA Educational poster
Scientific Poster	Role of the Gadolinium-DTPA infused MR in bone eosinophilic granuloma	Moon TY, Lee IS, Choi KW, Lee JM Chae JM, Lee SJ.	RSNA2009, Chicago, USA,
oral presentations	Evaluation of rotator interval of shoulder on direct CT arthrography using MDCT: correlation with external rotation shoulder stress radiography	Choi HS, <u>Choi JA</u> , Oh JH, Choi JY, Hong SH, Kang HS	95th Scientific Assembly and Annual Meeting, Radiological Society of North America, Nov 29-Dec 4, 2009, Chicago, Il, USA
oral presentations	CT Arthrography of the Repaired Rotator Cuff Using MDCT: Interobserver Agreement and correlation with Functional Outcome	Park SY, <u>Choi JA</u> , Oh JH, Choi JY, Hong SH, Kang HS	95th Scientific Assembly and Annual Meeting, Radiological Society of North America, Nov 29-Dec 4, 2009, Chicago, Il, USA
oral presentations	Usefulness of MRI with Microscopy Coil in Evaluation of Malignant Melanoma: Histopathologic Correlation with Breslow's Depth and Clark's Level	Kang Y, <u>Choi JA</u> , Oh JH, Chung JH, Hong SH, Kang HS	95th Scientific Assembly and Annual Meeting, Radiological Society of North America, Nov 29-Dec 4, 2009, Chicago, Il, USA
oral presentations	MR Imaging of Giant Cell Tumor of Bone: Prediction of Recurrence	Myung JS, Hong SH, Choi JY, Kim SJ, Lee JW, <u>Choi JA</u> , Kang HS	95th Scientific Assembly and Annual Meeting, Radiological Society of North America, Nov 29-Dec 4, 2009, Chicago, Il, USA
poster/exhibit	MRI Mapping of Skeletal Muscle Denervation in Peripheral Neuropathies	Kim SJ, Hong HS, Jun WS, Choi JY, Myung JS, Lee JW, <u>Choi JA</u> , Kang HS	95th Scientific Assembly and Annual Meeting, Radiological Society of North

pres enta tions				America, Nov 29-Dec 4, 2009, Chicago, IL, USA
post er/e xhibi t pres enta tions		T2 Signal of Soft Tissue Tumors around Shoulder: Radiologic-Pathologic Correlation	Kim YG, <u>Choi JA</u> , Kang HS	95th Scientific Assembly and Annual Meeting, Radiological Society of North America, Nov 29-Dec 4, 2009, Chicago, IL, USA
exhi bit		Sclerotic bone lesions: Imaging spectrum of imaging findings with pathologic correlation	² In Sook Lee, M.D., ^{1,2} Yoo Jin Lee, M.D., ³ Kil-Ho Cho, M.D., ⁴ Sung-Moon Lee, M.D., ⁵ Young Hwan Lee, MD, ⁶ Jae Hyuck Yi, MD., ^{1,2} Tae-Yong Moon, M.D., ^{2,7} Kyung-Un Choi, M.D., ^{2,8} Jeung Il Kim, MD	RSNA 2009 Education exhibit
post er		CT and MRI Findings of Calcified Spinal Meningiomas: Correlation with Pathologic Findings	² In Sook Lee, M.D., ^{1,2} Ji Won Lee, M.D., ^{2,3} Kyung-Un Choi, M.D., ⁴ Young Hwan Lee, M.D., ⁵ Jae Hyuck Yi, M.D., ⁶ Jong Woon Song, M.D., ⁷ Kyung Jin Suh, M.D., ^{1,2} Hak Jin Kim, M.D	RSNA 2009 scientific poster
exhi bit		A pictorial review of the uncommon presentations of the bone tumors accompanying pathologic fracture; Imaging features with pathologic correlation	⁵ In Sook Lee, M.D., ^{1,5} Jeong A Yeom, M.D., ^{1,6} Kil Ho Cho, M.D., ^{1,7} Sung-Moon Lee, M.D., ^{1,8} Young Hwan Lee, M.D., ^{1,9} Jae Hyuck Yi, M.D., ^{2,5} Kyung-Un Choi, M.D., ^{3,5} Jeung Il Kim, M.D.,	RSNA 2009 Education exhibit
exhi bit		Joint imaging at 3T MRI; focused on three dimensional isovoxel images	² Gee Won Lee, M.D., ^{1,2} In Sook Lee, M.D., ³ Kyung Jin Suh,	RSNA 2009 Education exhibit

			M.D., ⁴ Jae Min Ahn, M.D., ^{1,2} Tae-Yong Moon, M.D., ⁵ Nam Gu Kang, Dong Hyung Kim	
구연		Thick low signal band of the infrapatellar fat pad on knee MR imaging: a landmark for the detection of thickened medial patellar plica?	Park SY, Jin W, Park JS, Ryu KN, Yang DM, Kim HC	RSNA 2009.12
Pres enta tion		Potter. Autologous chondrocyte implantation in osteochondral lesions of the talus: MR imaging evaluation at one-year follow-up	Yun Sun Choi, Hye- jin Yang, Mi-hye Im, Kyung-tae Lee, Hollis G	RSNA 2009 Scientific Presentation
Pres ented		Musculoskeletal MRI Suggesting the Possibility of Liposarcoma: Correlation between Radiologist's Certainty of Diagnosis and Pathologic Results	YM Lee, HW CHUNG, MJ Shin, SH Lee	Presented at the 95th Scientific Assembly and Annual Meeting of RSNA, 2009, Chicago.
전시		Spinous process insufficiency fractures in the osteoporotic compression fractures involving thoracolumbar spine	Seo MRN, Lee KM, Park SY, Park JS, Jin W, Ryu KN	RSNA 2009.12
전시		Scoliosis Imaging: What the orthopedic surgeons want to know	김하나, 김성준, 윤춘식, 정태섭, 김학선, 문은수	RSNA 2009
전시		Chest wall tumors or tumor like lesions: systematic review for differential diagnosis	남세진, 김성준, 윤춘식, 김태훈, 서진석	RSNA 2009
구연		Joint Imaging at 3 T MRI: Focused on Three-dimensional Isovoxel Images LL-MK2411	Geewon Lee In Sook Lee In Sook Lee Kyung Jin Suh Tae-Yong Moon	95th Scientific Assembly and Annual Meeting of Radiologic society of North America, Chicago, U.S.A., Nov 29-Dec 4, 2009
구연		CT and MRI Findings of Calcified Spinal Meningiomas: Correlation with Pathologic Findings LL-NR4604	In Sook Lee Kyung Jin Suh Young Hwan Lee Jae Hyuck Yi Tae-Yong Moon	95th Scientific Assembly and Annual Meeting of Radiologic society of North America, Chicago, U.S.A., Nov 29-Dec 4,

				2009
		Lateral Meniscocapsular Separation in Patients with Lateral Tibial Plateau Fractures: Detection with MR Imaging (scientific paper)	Lee SY, Jee WH, Koh JJ, Kim JM	95th Scientific Assembly and Annual Meeting of Radiological Society of North America 2009
구연		The value of Sono-guided biopsy in the bacteriologic diagnosis of cellulitis	유정림, 홍석주, 이승훈, 강은영, 정희진	RSNA 2009, Chicago, U.S.A
구연		The prediction of intradiscal cement leakage during vertebroplasty: multivariate study using preoperative MR scoring system	이승훈, 홍석주, 김백현, 강은영, 강창호, 이근영	RSNA 2009, Chicago, U.S.A
		Extensor hallucis longus tendon injury in taekwondo athletes	Lee KT, Choi YS, Lee YK, Lee JP, Young KW, Park SY	Phys Ther Sport 2009 Aug;10(3):101-4
논문	2010	Inferior Accessory Ossicle of the Anterior Arch of the Atlas	Chung-Soo Whang, M.D., Phil-Hyun Chung, M.D., Kyung-Jin Suh, M.D.,* Suk Kang, M.D., Jong-Pil Kim, M.D., Young-Sung Kim, M.D. and Jae-Woo Cho, M.D	J Korean Orthop Assoc. 2010 Jun;45(3):234-237 게재확정일 2010. 1 월 24 일
논문		Ultrasound Diagnosis of Either an Occult or Missed Fracture of an Extremity in Pediatric-Aged Children.	Kil-Ho Cho, Sung-Moon Lee, Young-Hwan Lee, Kyung-Jin Suh	Korean J Radiol 2010; 11(1): 84-94 Jan/Feb
		Magnetoplex based on MnFe ₂ O ₄ nanocrystals for magnetic labeling and MR imaging of human mesenchymal stem cells	Yang J, Lim EK, Lee ES, Suh JS, Haam S, Huh YM	J of Nanoparticle Research 2010;12(4) May;1275-1283
		Phase-sensitive, dual-acquisition, single-slab, 3D, turbo-spin-echo pulse sequence for simultaneous T2-weighted and fluid-attenuated whole-brain imaging	Park J , Park S , Yeop Kim E , Suh JS	Magn Reson Med. 2010 May;63(5):1422-30.
		Prostate cancer cell death produced by the co-delivery of Bcl-xL shRNA and doxorubicin using an aptamer-conjugated polyplex	Kim E, Jung Y, Choi H, Yang J, Suh JS, Huh YM, Kim K, Haam S	Biomaterials 2010 June;31(16):4592-4599

		Nanoscaled Iodized Oil Emulsion as a CT Contrast Agent for the Detection of Experimental Liver Tumors in a Rat Model	Lim SJ, Lim JS, Choi J, Choi JY, Hyung WJ, Kim HS, Suh J, Kim KW	Academic Radiology 2010;17(8)Aug:985-991
논문		Nuchal-type fibroma of the buttock: magnetic resonance imaging findings	Gyung Kyu Lee, Kyung Jin Suh, Sung Moon Lee, Sun Joo Lee	Jpn J Radiol 2010;28:538-541
논문		Myositis Ossificans of the Psoas Muscle After Compression Fracture of Lumbar Spine: CT and MR Imaging Findings	Mi Nyong Choi, Gyung Kyu Lee, Kyung Jin Suh	J Korean Soc Radiol 2010;63:75-7
		상지의 고압 전기화상의 혈관조영술 및 자기공명영상 소견: 증례 보고1	미농·이경규·서경진·강익원·황대현·이일성·민선정·전 옥	대한영상의학회지 2010;62:389-392
논문		Three-dimensional osseous micro-architecture of the distal humerus: Implications for internal fixation of osteoporotic fracture	Park SH, Kim SJ, Park BC, Suh KJ, Lee JY, Park CW, Shin IH, Jeon IH	J Shoulder Elbow Surg. 2010;19:244-250
		Comparison of MRI and arthroscopy after autologous chondrocyte implantation in patients with osteochondral lesion of the talus	Lee KT, Choi YS, Lee YK, Kim JS, Kim JH	Orthopedics 2010 Aug 11;33(8)
		Liposomes coloaded with iopamidol/lipiodol as a re-targeted contrast agent for computed tomography imaging	Kweon S, Lee HJ, Hyung WJ, Suh J, Lim JS, Lim SJ	. Pharmaceutical Research 2010; 27:1408-1415
		Proton magnetic resonance spectroscopy of musculoskeletal lesions at 3T with metabolic quantification	Lee CW, Lee J-H, Kim DH, Min HS, Park BK, Cho HS, Kang HG, Suh JS, Ehara S.	Clinical Imaging 2010;34(1):47-52
Exhibit		Contrast-enhanced MRI for the staging of skeletal eosinophilic granuloma	Moon TY, Lee IS.	ECR2010, Vienna, Austria, [Scientific Exhibit] (2010.03.04)
oral presentations		Postoperative CT arthrography using MDCT in patients with SLAP repair: imaging findings with clinical correlation.	Lee KH, Kim JE, Choi JA, Oh JH, Hong SH, Kang HS	22nd European Congress of Radiology Meeting, 3.4.-3.8. 2010. Vienna, Austria
presentation		Comparison of diagnostic accuracy between dynamic cine-arthrography and wrist MRI with	Guen Young Lee ¹ , Baek Hyun Kim ¹ , Sang Hoon Cha ¹ , Ki	2010 ECR

	or without intraarticular contrast injection in diagnosis of intrinsic ligament tear and TFCC tear, based on arthroscopic findings.	Yeol Lee ¹ , Suk Joo Hong ² , Chang Ho Kang ³ , Jong Woong Park ⁴ , Jong Woo Kang ⁴	
구연	MR imaging of ulnar collateral ligament injury in baseball players: Value for predicting rehabilitation outcome	Na Ra Kim, Sung Gyu Moon, Sung Min Ko, Won-Jin Moon, Jin Woo Choi, Jin-Young Park	2010 ECR
포스터	3.0T 자기공명영상: 비세포암 환자에서 작은 결절을 발견하는데 어떤 sequence가 유용한가?	교신:진공용, 제 1:이재아, 한영민, 정경호, 김영곤, 이상용,	ECR 비엔나 2010
전자 전시	Preoperative US-guided indigocarmine injection of benign cystic lesions around the knee	박희진	US findings of bifid median nerve 2010. 3 ECR
presentation	Comparison of high resolutional ultrasonographic imaging with water bath immersion technique and MRI with microscopic coil in the evaluation of hand	Ik Yang	AOCR (Asian-Oceanian Congress of Radiol), Taipei, Taiwan, Mar, 2010
Poster	Radiologic features of lipomatous tumors as a periarticular soft tissue mass	Ik Yang	AOCR (Asian-Oceanian Congress of Radiol), Taipei, Taiwan, Mar, 2010
Poster	High resolutional ultrasonographic findings of nerve entrapment syndromes	Ik Yang	AOCR (Asian-Oceanian Congress of Radiol), Taipei, Taiwan, Mar, 2010
	Non-neoplastic peripheral neuropathy Trauma-related peripheral nerve injury	KH Cho	AOCR (Asian-Oceanian Congress of Radiol), Taipei, Taiwan, Mar, 2010
구연	Avulsion fractures of the anterior cruciate ligament: Different frequency of associated injuries between adults and children on MR imaging	강유진,전세정,박성훈,김강득,송상국,이상용	AOCR 2010 TAIPEI 470 ~ 471 2010.03.21 대만 타이베이 국제컨벤션센터
구연	The prediction of intradiscal cement leakage during vertebroplasty: multivariate study using preoperative MR scoring system	이승훈,홍석주,김백현,강은영,강창호,이근영	2010 APCCVIR

exhibit	Charateristic Radiologic Findings of Adult Skeletal Langcrhans Cell Histiocytosis; Emphasis on MR Findings.	In Sook Lee	ESSR 2010 Education exhibit
exhibit	A pictorial review of the uncommon presentations of the bone tumors accompanying pathologic fracture; Imaging features with pathologic correlation	In Sook Lee	ESSR 2010 Education exhibit
exhibit	Soft Tissue Masses Showing Decreased Signal Intensity on Long Repetition Time (TR) Image : Correlation with Pathologic Findings	In Sook Lee	ESSR 2010 Education exhibit
구연	연조직종양의 진보된 분류: 새로운 WHO 분류에 의한 갱신	서경진. 이지영	대한근골격영상의학회 학술대회, 라마다플라자 호텔, 제주도, Apr 16-17, 2010
구연	Shoulder Impingement Syndrome	서경진. 이경규	대한근골격영상의학회 학술대회, 라마다플라자 호텔, 제주도, Apr 16-17, 2010
구연	One Shot One Kill: Hip and Pelvis. Phillip Tirman MD	서경진	20 차 대한근골격영상의학회 학술대회, 라마다플라자 호텔, 제주도, Apr 16-17, 2010
구연	MRI Ankle and Foot: A Case Based Approach. James Linklater	서경진.	제 20 차 대한근골격영상의학회 학술대회, 라마다플라자 호텔, 제주도, Apr 16-17, 2010
구연	Adult Hip Pain.	서경진. 이성문. 이영환. 이재혁. 조길호	제 20 차 제 20 차 대한근골격영상의학회 학술대회, 라마다플라자 호텔, 제주도, Apr 16-17, 2010
구연	Functional imaging of fibromyalgia	Hui-jin Song, Joo-	International Society

		using empathy for pain	hyun Kim, Jeehye Seo, Moon-jung Hwang, Young-ju Lee, Kyung Jin Suh, Sung Woo Kim, Young Hwan Lee, Dong Soo Yoo, Yongmin Chang.	for Magenetic Resonance in Medicine. Stockholm, Sweden, May 1-7, 2010
구연		Functional imaging of observation of action in elite archers using video of Western-style archery task	Hui-jin Song, Joo-hyun Kim, Jeehye Seo, Moon-jung Hwang, Young-ju Lee, Kyung Jin Suh, Sung Woo Kim, Young Hwan Lee, Dong Soo Yoo, Yongmin Chang	International Society for Magenetic Resonance in Medicine. Stockholm, Sweden, May 1-7, 2010
구연		Altered working memory process in welders using N-back fMRI	Jeehye Seo, Jae-jun Lee, Hui-jin Song, Joo-hyun Kim, Kyung Jin Suh, Sung Woo Kim, Young Hwan Lee, Dong Soo Yoo, Yongmin Chang.	International Society for Magenetic Resonance in Medicine. Stockholm, Sweden, May 1-7, 2010
전시		Insufficiency fracture of the sternum	Mi Sook Sung, Jun K Min, Myung H Chung	ISS2010
		Proton density-weighted MR imaging of the knee: fat-suppression versus without fat-suppression (scientific paper)	Lee SY, Park MY, Jung JY, Suh KJ, Kim JM, Jee WH	37th International Skeletal Society Annual Meeting 2010
exhibit		Epidermal inclusion cyst: initial experience with diffusion-weighted MR imaging (electronic exhibit)	Lee SY, Jee WH, Jung JY, Park MY, Chung YG	37th International Skeletal Society Annual Meeting 2010
Exhibition		High-resolution ultrasonography of joint Pathology	<u>Yun Sun Choj</u> , Mi-hye Im, Yun Jung Kim, Tong Jin Chun, Seoug-Oh Yang	International Skeletal Society 2010 Educational Exhibition
전시		The Effect of Rotation Angle on the Measurement of BMD in the Forearm.	한만석, 양승호, 권순태	미국 영상의학회지 2010.05.03 San Diego(USA)

pres enta tion	Comparison of diagnostic accuracy between dynamic cine-arthrography and wrist MRI with or without intraarticular contrast injection in diagnosis of intrinsic ligament tear and TFCC tear, based on arthroscopic findings	Guen Young Lee ¹ , Baek Hyun Kim ¹ , Sang Hoon Cha ¹ , Ki Yeol Lee ¹ , Suk Joo Hong ² , Chang Ho Kang ³ , Jong Woong Park ⁴ , Jong Woo Kang ⁴	2010 ARRS poster presentation
	<p>"Ultrasound of pediatric bone trauma"</p> <p>"Ultrasound of carpal tunnel: median nerve-related pain"</p> <p>"Elbow ligament: MR vs. Ultrasound"</p> <p>"Ultrasound of the hand and wrist: common pathology"</p>	KH Cho	The Annual Congress of Musculoskeletal Ultrasound Society", Cancun, Mexico, Jul 21-24, 2010
Exhi bit	Modified MRI classification to predict histologic grading of liposarcomas.	Moon TY	The 37th ISS, Athen, Greece,
구연	Giant cell tumor of metacarpal bone in pregnant womenq	Ryu KN, Park JS, Park YK	ISS 2010. 09
	Monostotic Fibrous Dysplasia confined to the Body of the Lumbar Spine: Imaging Features in Four Patients	Kwon ST, Kang HS, Ryu KN, Cho JH, Juhng SK, Hwang CM, Park WJ, Yeon JS	ISS 2010. EE, Greece, Athens
pres enta tion	Qualitative assessment of isotropic ankle MR imaging: 3D isotropic intermediate-weighted fast spin echo (FSE) versus 3D isotropic fast field echo (FFE) sequences	Young Cheol Yoon, Hyun Su Kim, Jong Won Kwon	SS0758. 66 th Annual Meeting of Korean Radiological Society, Seoul, Korea, October 18- October 20, 2010
pres enta tion	Is Ultrasonographic Evaluation of Rotator Interval Useful in Diagnosis of Adhesive Capsulitis of Shoulder?	Young Cheol Yoon, Won Seon Shin, Jong Won Kwon	SS0761 66 th Annual Meeting of Korean Radiological Society, Seoul, Korea, October 18- October 20, 2010
pres enta tion	Qualitative assessment of isotropic wrist MR imaging: 3D isotropic intermediate-weighted fast spin echo (FSE) versus 3D isotropic fast field echo (FFE) sequences	Young Cheol Yoon, Jee Young Jung, Jong Won Kwon.	SS0762 66 th Annual Meeting of Korean Radiological Society, Seoul, Korea, October 18- October 20, 2010
전시	A practical MRI grading system for lumbar foraminal stenosis	이승훈,이준우,강흥식, 조온구	ARRS 2010 샌디에이고

전시	Comparison of diagnostic accuracy between dynamic cine-Arthrography and wrist MRI with or without intraarticular contrast injection in the diagnosis of intrinsic ligament tear or TFCC tear, Based on Arthroscopic findings of the wrist	김백현,이근영,차상훈,홍석주,강창호,이승훈	ARRS 2010 샌디에이고
presentation	Indirect Magnetic Resonance (MR) Arthrographic Findings of Adhesive Capsulitis (AC)	Jong Won Kwon, Kyoung Doo Song, Young Cheol Yoon, Sang-Hee Choi	SSC10-06. The 96 th Scientific Assembly and Annual Meeting, Radiological Society of North America, McCormick Place, Chicago, Illinois, November 28-December 4, 2010
presentation	Qualitative Assessment of Isotropic Knee MR Imaging: 3D Isotropic VISTA vs 3D Isotropic FFE Sequences	Young Cheol Yoon, Jung Min Seo, Jong Won Kwon, Hyun Su Kimi	SSE15. The 96 th Scientific Assembly and Annual Meeting, Radiological Society of North America, McCormick Place, Chicago, Illinois, November 28-December 4, 2010
presentation	Qualitative Assessment of Isotropic Wrist MR Imaging: 3D Isotropic VISTA vs 3D Isotropic FFE Sequences	Young Cheol Yoon, Jong Won Kwon, Jee Young Jung	LL-MKS-TU1B. The 96 th Scientific Assembly and Annual Meeting, Radiological Society of North America, McCormick Place, Chicago, Illinois, November 28-December 4, 2010
presentation	MR Findings of Aspergillus Spondylitis	Jong Won Kwon, Sung Hwan Hong, Sang-Hee Choi, Young Cheol Yoon	LL-MKS-WE2B. The 96 th Scientific Assembly and Annual Meeting, Radiological Society of North America, McCormick Place, Chicago, Illinois, November 28-December 4, 2010

ent tion	Benign Musculoskeletal Uptake on 18F-FDG PET/CT in Oncologic Patients: Correlation with MR Imaging	Jong Won Kwon, Kyoung Doo Song, Young Cheol Yoon, Sang-Hee Choi	LL-MKE2538 The 96 th Scientific Assembly and Annual Meeting, Radiological Society of North America, McCormick Place, Chicago, Illinois, November 28-December 4, 2010
pres enta tion	Meniscal Tear Types: Impact on Rapidly Progressive Osteoarthritis of the Knee Joint (scientific paper)	Lee SY, Jee WH, Jung JY, Park MY, Ju JH	96th Scientific Assembly and Annual Meeting of Radiological Society of North America 2010
pres enta tion	Meniscal Tear Configurations: Categorization with 3D Isotropic Turbo Spin-Echo MR Imaging Compared with 2D Conventional MR Imaging at 3.0 T (scientific paper).	Jung JY, Jee WH, Park MY, Lee SY, Kim JM	96th Scientific Assembly and Annual Meeting of Radiological Society of North America 2010
pres enta tion	Rotator Cuff Tears at 3.0 T Shoulder MR Arthrography: Diagnosis with 3D Isotropic Turbo Spin-Echo SPACE Sequence versus 2D Conventional Sequences (scientific paper)	Jung JY, Jee WH, Park MY, Lee SY, Kim YS	96th Scientific Assembly and Annual Meeting of Radiological Society of North America 2010
post er	SLAP Tears at 3.0 T Shoulder MR Arthrography: Diagnosis with 3D Isotropic Turbo Spin-Echo SPACE Sequence versus 2D Conventional Sequences (scientific poster)	Jung JY, Jee WH, Park MY, Lee SY, Kim YS	96th Scientific Assembly and Annual Meeting of Radiological Society of North America 2010
post er	Importance of Early Relative Enhancement and Preliminary Results in Using 3.0 T Dynamic MRI for Evaluation of Bone and Soft Tissue Tumors (scientific poster)	Park MY, Jee WH, Lee SY Jung JY	96th Scientific Assembly and Annual Meeting of Radiological Society of North America 2010
post er	Wrist: Isotropic MR Imaging with 3D-FSE-Cube—Preliminary Results in Healthy Volunteers	이민희(순천향부천), 차장규, 박재성, 박성진, 이범하, 김동훈	2010년 RSNA
post er	Bright Dot Sign on MR Image for the Anterior Talofibular Ligament	이민희(순천향부천), 차장규, 이영구, 박성일	2010년 RSNA

		Injury	,이혜경,홍현숙	
Scientific paper		Usefulness of IDEAL Contrast-enhanced T1- and T2-weighted Imaging in Reducing Metallic Artifact in Postoperative Spines: A Phantom and Clinical Study	차장규,진욱,이민희(순천향부천),황문정,박재성,박성진	2010년 RSNA
presentation		The usefulness of of MDCT in early detection and prediction of cortical collapse in osteonecrosis of femur head, using modified Kerboul method: comparison with MRI	Guen Young Lee ¹ , Jung-Ah Choi ¹ , Kyung-Hoi Koo ² , Yong-Chan Ha ² , Ja-Young Choi ³ , Sung Hwan Hong ³ , Heung Sik Kang ¹	2010 RSNA scientific
전시		Ultrasound-guided Musculoskeletal Interventions: Beyond the Routine	<i>Y Kim, MD, S Hong, MD; E Kang, MD; I Cha, MD, PhD</i>	RSNA 2010
구연		Accuracy of MR finding in characterizing peroneal tendons disorders in comparison with surgery	박희진	2010. 12 RSNA

4 부

사진으로 보는
근골격영상의학회 20년

제 1장. 학회활동

- Radiological **S**ociety of **N**orth **A**merica
- **A**sian **M**uskuloskeletal **S**ociety
- **I**nternational **S**ociety for **M**agnetic
Resonance in **M**edicine
- **I**nternational **S**keletal **S**ociety
- **A**sian **O**ceanian **C**ongress of **R**adiology
- **A**merican **S**ociety of **S**pine **R**adiology

1 | RSNA



2003 RSNA

2 | AMS



2004 AMS



3 | ISMRM



2004 ISMRM



2006 ISS









2007 ISS





2009 ISS



5 | AOCR




2008 AOCR 단체사진



2008 AOCR 연자




2008 AOCR 회원모임



2008 AOCR 회원모임

6 | ASSR



제 2장.

대한근골격영상의학회 발자취를 기억하며

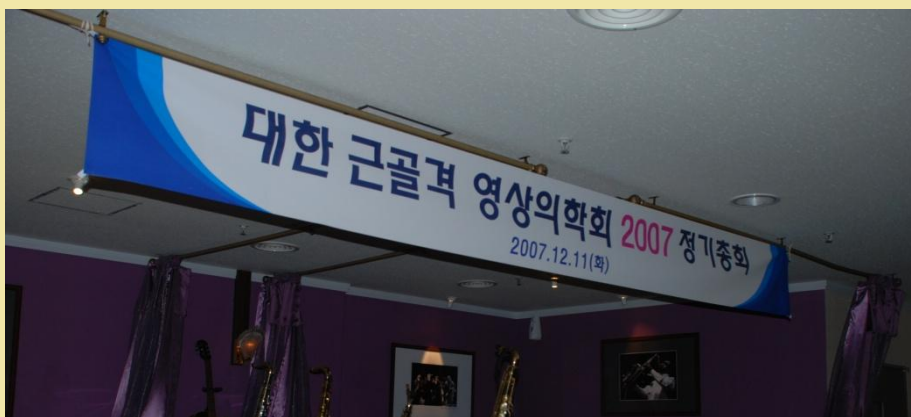

2004 집담회



2006 골영송년회

2007 골영송년회





2007 대영학회



2008 골영 춘계 강릉 단체 사진



2008 골영송년회



2008 전공의 교육목표 개정작업



2009 송년심포지움



단체사진



송년심포지움 강사



2009 송년심포지움 임원진



2009 송년심포지움 회장 이임 및 취임

2009 골영봄학회



단체사진





2009 추계학술대회



2009 radiology-pathology conference

5 부

학 회 현 황

- 1 회칙
- 2 홈페이지 운영

1 | 회칙

대한근골격영상의학회 회칙 개정(안)

● 제1차 개정안(2005년)

제 1 장 총 칙

제 1 조 (명칭)

본회는 대한근골격영상의학회 (골영회)라 한다.

제 2 조 (목적)

본회는 학술교류, 연구발표, 교육등의 사업을 통하여 근골격계방사선 과학 및 관련의학분야의 학문발전을 촉진시키는데 있다.

제 2 장 회 원

제 3 조 (회원)

본회의 목적에 찬성하고 협력하는 영상의학과 전문의들로 구성한다.

제 4 조 (특별회원)

본회의 목적에 찬성하고 협력하는 다른과 전문의들에게 특별회원의 자격을 줄 수 있다.

제 5 조 (회원가입)

회원이 되고자 할때는 성명, 소속기관, 현주소를 기입하여 총무에게 신청하며, 가입에 대한 본회의 승인을 받은 후 본회 홈페이지에 등록을 신청한다.

제 6 조 (회비)

회원은 매년 연회비를 납부하여야 하며 회비는 총회에서 결정한다.

제 3 장 임 원

제 7 조 (임원의 구성)

본회는 회장 1명과 5인 이내의 운영위원을 둔다.

제 8 조 (임원의 선출)

회장은 총회에서 선출하며 운영위원은 회장이 회원 중에서 선임한다.

제 9 조 (임원의 임기)

임원의 임기는 2년으로 연임 또는 중임할 수 있다.

제 10 조 (임원의 임무)

회장은 본회를 대표하여 본회의 모든 일을 총괄 집행한다.
운영위원은 회장을 보좌하고 회장의 위임 사항을 집행한다.

제 4 장 총 회

제 12 조 (총회의 소집)

총회는 매년 1회 실시하며, 필요시 임시총회를 개최할 수 있다.

제 13 조 (의결 정족수)

총회 참석 회원수의 과반수 찬성으로 결정한다.

제 14 조 (총회의 기능)

- 1) 사업계획
- 2) 예산 및 결산
- 3) 회칙개정
- 4) 회장 선출
- 5) 연회비 결정
- 6) 기타 필요하다고 인정되는 사항

제 5 장 사 업

제 15 조 (사업)

본회의 목적을 이루기 위하여 다음과 같은 사업을 한다.

- 1) 학술대회: 매년 1 회 이상 회장 및 운영위원이 정하는 제목 및 연자로 개최함을 원칙으로 한다.
- 2) 학술집담회: 년 8 회이상 개최함을 원칙으로 한다.
- 3) 기타 본회의 목적에 부합하는 사업을 운영위원회의 의결을 거쳐 시행할 수 있다.

제 6 장 회 계

제 16 조 (재정)

본회의 운영경비는 회원의 회비, 대한영상의학회 보조금 및 기타 수입금으로 한다.

제 17 조 (예산, 결산)

본회의 예산 및 결산은 총회의 승인을 받아야 한다.

제 18 조 (회계연도)

본회의 회계연도는 매년 1 월 1 일부터 12 월 31 일까지 한다.

부 칙

제 19 조

이 회칙에 명시되지 않은 사항은 총회의 결정을 따른다. 본회의 회칙은 운영위원회의 동의를 거쳐 총회에서 개정할 수 있다.

제 20 조 (회칙의 시행)

이 회칙은 2005 년도부터 시행한다.

● 제2차 개정안(2010년)

제 1 장 총 칙

제 1 조 (명칭)

이회는 대한영상의학회 산하 학회로서 “대한근골격영상의학회”라 하며, 영문표기는 “(The Korean Society of Musculoskeletal Radiology(KSMR))”로 한다.

제 2조 (목적)

이회는 회원의 학술교류, 연구, 교육 등의 사업을 통하여 근골격영상의학 및 관련 의학분야의 학문 발전을 촉진시키고, 회원상호간의 협력 증진 및 관련된 보건 의료정책의 수립과 시행에 기여함을 목적으로 한다.

제 3 조 (사무소)

이회의 사무소는 서울특별시에 둔다.

제 4 조 (사업)

이회는 제 2 조의 목적을 달성하기 위하여 다음의 사항을 행하며 구체적인 실무에 관한 사항은 이사회에 의거한다.

- 1) 근골격영상의학에 관한 학술 집담회 및 학술대회
- 2) 근골격영상의학에 관한 교육
- 3) 관련 분야의 저술(학회지 및 도서 간행) 및 연구
- 4) 관련 의료정책 수립에 대한 의견 개진 및 자문
- 5) 목적사업의 경비를 충당하기 위한 수익사업
- 6) 기타 이 회의 총회 및 이사회에서 의결한 사업

제 5 조 (연구회 및 지회)

이회는 산하에 연구회 및 지회를 설치할 수 있다. 연구회 및 지회의 설치 및 해산은 소정의 절차에 따라 이사회에 신청 및 승인을 얻어야 하며 학회는 재정적 지원을 할 수 있다. 연구회 및 지회의 설치와 활동에 관한 제반 사항은 학회의 제반 규정에 따른다.

제 2 장 회 원

제 6 조 (회원)

회원은 정회원, 공로회원, 특별회원 및 준회원으로 한다.

제 7 조 (정회원)

정회원은 근골격영상의학을 전공하는 영상학과 전문의로 이 회의 목적에 찬성하고 협력하는 자로 한다.

정회원 가입절차 및 자격 상실은 회원 자격에 관한 규정에 따른다.

제 8 조 (공로회원)

정회원 중 이 회의 발전에 탁월한 업적을 이룬 회원을 대상으로 하며 이사회의 추천과 총회의 인준을 받아 추대할 수 있다. 공로회원의 권리는 정회원에 준한다.

제 9 조 (준회원)

영상학과 전문의 및 영상학과 전공의는 준회원으로 가입할 수 있으며 입회 및 탈퇴에 따른 필요한 사항은 회원 자격에 관한 규정에 따른다.

제 10 조 (특별회원)

영상학과 전문의 및 전공의 외의 자는 특별회원으로 가입할 수 있으며 입회 및 탈퇴에 따른 필요한 사항은 회원 자격에 관한 규정에 따른다.

제 11 조 (회원의 권리)

- 1) 이 회의 정회원은 회칙에서 정하는 바에 따른 의결권, 선거권 및 피선거권, 목적사업의 참여권, 총회 발언권을 갖는다.
- 2) 특별회원 및 준회원은 이 회에서 개최하는 행사에 참가할 수 있다.

제 12 조 (회원의 의무)

- 1) 회원은 이 회의 회칙, 제 규정 및 총회의 의결사항을 준수하여야 한다.
- 2) 회원은 이 회의 학술활동 및 학술발표 등의 사업에 참여하여야 한다.
- 3) 정회원은 소정의 연회비를 납부하여야 하며 납부와 관련된 사항은 납부에 관한 규정에 따른다.

제 13조 (포상 및 징계)

1) 포상

회원의 의무를 다하고 학술활동, 사회봉사, 의료서비스의 질 향상 등에 탁월한 업적을 이룬 회원을 발굴하여 이사회 규정에 따라 시상할 수 있다.

2) 징계

의사의 윤리와 회칙을 위반하여 이 회의 명예를 실추시킨 회원에 대하여는 규정에 따라 징계할 수 있다.

제 3 장 임 원

제 14 조 (임원의 구성)

이 회의 임원은 회장 1명, 감사 1명, 9-12명의 이사로 구성하며, 부회장 1명을 둘 수 있다.

- 1) 총무이사 1명
- 2) 학술이사 1명
- 3) 편집이사 1명
- 4) 기획정보이사 1명
- 5) 의무/보험이사 1명
- 6) 국제협력이사 1명
- 7) 재무이사 1명
- 8) 고시이사 1명
- 9) 수련이사 1명
- 10) 특임이사 (약간 명)

제 15 (임원의 선출)

- 1) 이 회의 회장 및 부회장 선거에 관한 사항은 선거 관리 규정으로 정한다.
- 2) 감사는 총회에서 선출한다.
- 3) 이사는 회장이 선임한다.

제 16 조 (임원의 임기)

- 1) 임원의 임기는 2년으로 연임 또는 중임할 수 있다.
- 2) 보선 임원은 전임자의 잔존기간 재임이며, 보선 이사의 선임은 회장에 일임한다.

제17조 (임원의 임무)

- 1) 회장은 이 회를 대표하고 이사회 및 총회의 의장이 되며 회무를 총괄한다.
- 2) 부회장은 회장 유고 시 회장직을 대리한다.
- 3) 총무이사는 이 회의 업무 및 재정을 집행하고 회장과 부회장 유고 시 회장직을 대리한다.
- 4) 학술이사는 이 회의 제반 학술업무를 집행한다.
- 5) 편집이사는 이 회의 제반 간행 및 발간업무를 담당한다.
- 6) 기획정보이사는 이 회의 제반 정보 및 기획업무를 담당한다.
- 7) 의무/보험이사는 이 회의 제반 의무 및 보험업무를 담당한다.
- 8) 국제협력이사는 이 회의 제반 발전을 위한 대외사업을 담당한다.
- 9) 재무이사는 이 회의 제반 재무업무를 담당한다.
- 10) 고시이사는 이 회의 제반 고시업무를 담당한다.
- 11) 수련이사는 이 회의 제반 수련업무를 담당한다.
- 12) 특임이사는 이 회의 이사회가 정하는 특별업무를 담당한다.
- 13) 감사는 이 회의 사무 및 재정을 감사하고 그 결과를 총회에 보고한다.

제 4 장 이사회

제 18조 (이사회 구성)

이사회는 회장, 부회장, 이사로 구성하며 회장이 이를 소집하고 의장이 된다.

제 19조 (이사회 임무 및 의결)

이사회는 재적 과반수의 출석과 출석 과반수의 찬성으로 의결하며 가부동수인 때에는 의장이 결정한다. 이사회의 활동은 총회에 보고하여야 한다. 이사회는 학회의 운영 및 발전을 위해 다음의 제반 시책과 사업을 계획 집행한다.

- 1) 정회원, 공로회원, 특별회원 및 준회원에 대한 회원자격에 관한 사항
- 2) 연구회 및 지회 운영에 관한 제반 사항.
- 3) 회원에 대한 포상 및 징계에 관한 사항.
- 4) 위원회의 위원 선출 운용에 관한 사항.
- 5) 이 회의 목적과 사업수행에 관한 사항
- 6) 총회에서 위임된 사항

- 7) 서무, 회계, 예산 편성 및 결산에 관한 사항
- 8) 총회 소집 및 제안에 관한 사항
- 9) 회칙 및 규정에 관한 사항
- 10) 제 규정의 제정 및 개정에 관한 사항
- 11) 기타 회무 운영에 관한 사항

제 5 장 위원회

제 20조 (위원회)

위원회의 구성, 위원장 자격, 위원의 선출 및 임기, 위원회의 활동에 관한 사항은 위원회에 관한 규정으로 정한다.

제 6 장 총회

제 21 조 (총회의 소집)

- 1) 총회는 매년 1 회 실시하며, 필요 시 임시총회를 개최할 수 있다.
- 2) 회원의 1/5 이상의 요구가 있거나 회장이 필요하다고 인정될 경우 임시총회를 개최할 수 있다.

제 22 조 (의결 정족수)

- 1) 총회의 의결은 출석 회원 과반수 이상의 찬성으로 결정한다.
- 2) 단 회칙 변경의 경우 참석회원 2/3 이상의 찬성, 이 회 해산의 경우는 참석회원 3/4 이상의 찬성으로 결정한다.

제 23 조 (총회의 기능)

총회는 다음 사항을 심의 의결한다.

- 1) 예산 및 결산 승인에 관한 사항
- 2) 회칙개정에 관한 사항
- 3) 회장, 부회장 및 감사의 선출에 관한 사항
- 4) 연회비 결정에 관한 사항
- 5) 이사회에서 제출한 사항
- 6) 임원 탄핵에 관한 사항
- 7) 기타 필요하다고 인정되는 사항

제 7 장 회 계

제 24 조 (재정)

이 회의 운영경비는 다음의 수입금으로 충당한다.

- 1) 회원의 회비
- 2) 대한영상의학회 보조금
- 3) 행사 참가비, 찬조금, 수익사업의 과실, 기부금 및 기타 수입금으로 한다.

제 25 조 (자산의 관리)

이 회의 자산은 자산 관리에 관한 규정에 따라 회장이 관리한다.

제 26 조 (세입 · 세출예산)

이 회의 세입 · 세출예산은 매 회계연도개시 1 개월 전까지 사업계획서와 함께 이사회의 의결과 총회의 승인을 얻어야 한다. 다만, 부득이한 사정이 있는 경우에 이사회의 의결과 총회의 승인은 새 회계연도 후 각 첫 회의에서 이를 받을 수 있다.

제 27 조 (회계연도) 이 회의 회계연도는 매년 1월 1일에 시작하여 12월 31일로 한다.

제 28 조 (회계감사) 감사는 연 1회 이상 회계감사를 하여야 하며 그 결과를 이사회와 총회에 보고하여야 한다.

제 29 조 (임원의 보수)

임원의 보수는 지급하지 아니한다. 다만 실비는 변상할 수 있다.

부 칙

제 30 조

- 1) 이 회칙에 명시되지 않은 사항으로 이 회의 사무를 집행하기 위해 필요한 규정은 따로 정한다.
- 2) 이 회의 회칙은 이사회의 심의를 거쳐 총회에서 개정할 수 있다.

제 31 조 (회칙의 시행)

이 회칙은 총회의 의결 후 2010년 5월 1일부터 발효 시행한다.

3. 홈페이지 운영

- 퀴즈 운영

2006년 12월, 대한근골격영상의학회 송년회 모임에서 실질적인 증례를 통한 근골격 영상의학에 관한 전공의 교육을 목적으로 홈페이지 퀴즈 시행이 제안되었고, 회원들의 압도적인 지지에 힘입어 2006년 12월 12일 대한근골격영상의학회 홈페이지에 “이주의 증례(Weekly case)”란 제목으로 본격적으로 홈페이지 퀴즈가 운영되게 됐다. 가능한 모든 병원에서 증례 출제에 참여할 수 있도록 각 병원마다 1년에 한 문제 씩 출제하는 것을 원칙으로 하였다. 처음에는 2주 마다 두 개 씩 증례를 올리고 증례에 대한 답을 응모하도록 했다. 그리고 2주 후 증례의 정답과 함께 질환에 대한 간략한 설명을 실어 증례를 잘 이해할 수 있도록 했으며, 더불어 정답자도 함께 발표했다.

2008년 1월부터는 매주 한 예씩 증례를 올리고 정답과 해설, 정답자는 증례 게시 2주 후에 발표하는 형식으로 변경되어 현재까지 유지되고 있고, 2010년 11월 둘째 주 현재 총 183개의 증례가 출제되었다. 증례 출제 및 해설은 국내뿐만 아니라 국외에서 참여할 수 있도록 모두 영문으로 작성하였다. 각 병원에서 보내진 증례는 부위별, 질환별로 각각 분류하여 검색창에서 증례를 손쉽게 검색할 수 있도록 데이터베이스화 했다. 또한 1년에 2번 전 후반기로 나눠 그간 가장 많이 정답을 응모한 전공의 및 전문의 각 0명 씩 선발해 9월, 근골격영상집담회와 송년회 때 시상함으로써 증례에 대한 정답 응모에 더 적극적으로 참여하도록 독려하고 있다. 증례의 수집, 홈페이지 게시, 정답 해설 및 정답자 발표 등은 2006년부터 2년 임기로 한강성심병원 이경규, 서울대병원 최자영, 부산대병원 이인숙 선생님 순으로 담당하고 있다.

▼역대 증례 수상자

- 2008. 02.04~07.28 (총 27회)

1. 최희석 동국대학교 일산병원(전공의)(18)
2. 김완태 서울보훈병원(17)
3. 이경규 한강성심병원(16)
3. 하종수 광명성애병원(16)

- 2008. 08.04~11.24 (총 17회)

1. 김완태 서울보훈병원(11)
1. 박소영 분당서울대병원(11)
2. 최희석 동국대학교 일산병원(전공의)(9)
3. 김권형 제주한마음병원(8)

- 2009. 06.01~11.16 (총 21회)

전문의

1. 이승훈 고대구로병원 (13)
2. 김완태 서울보훈병원 (12)
3. 오경진 분당서울대병원 (9)
3. 채지원 보라매병원 (9)

전공의

1. 박상현 순천향대학천안병원 (7)
2. 노봉완 인하대병원 (4)
2. 김성윤 서울아산병원 (4)
3. 김재원 강남성심병원 (3)
3. 김혜린 부천순천향병원 (3)